



THE CARDIOPULMONARY LIMITED ULTRASOUND EXAMINATION: A FOCUSED APPROACH TO BEDSIDE ULTRASONOGRAPHY

JEREMY P. TIMM, MD

ASSISTANT PROFESSOR, UNIVERSITY OF UTAH
ASSISTANT PROGRAM DIRECTOR, INTERNAL MEDICINE RESIDENCY PROGRAM
ASSISTANT CHIEF OF PRIMARY CARE, GEORGE E. WHALEN VA MEDICAL CENTER

CHRISTOPHER CARLISLE, MD

ASSISTANT PROFESSOR, UNIVERSITY OF UTAH
DIRECTOR OF MEDICINE PROCEDURES, GEORGE E. WHALEN VA MEDICAL CENTER

ACP REGIONAL MEETING
MARCH 1, 2019

OVERVIEW

- Introduce CLUE
- Hands on practice
- Clinical application

WHY BEDSIDE ULTRASOUND?

- Improvements in technology increases availability of ultrasounds
- Augmentation of the physical exam
- Improve clinical decision-making in real time


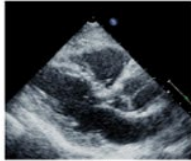


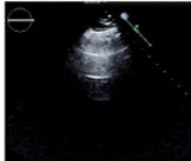
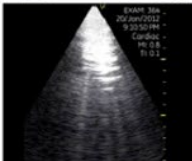

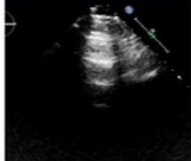
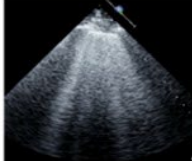

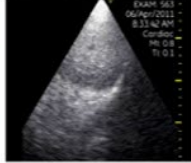


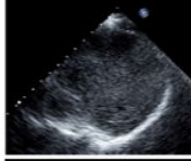
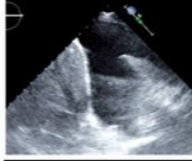


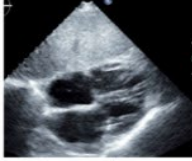

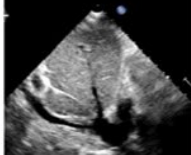

CAUTIONS

- Augmentation of physical exam, not a replacement for dedicated study
- Documentation needs?
- Saved images, over read by specialists?

CLUE

- 4 focused cardiopulmonary views
- Reasonable diagnostic accuracy
- Readily taught to novice users

CLUE VIEWS

	Site position	Normal	Abnormal
<p><u>Parasternal long axis</u> <i>Cardiac Dysfxn sign</i> <i>LAE sign</i></p>	<p>1</p> 		
<p><u>Lung, anteroapex</u> <i>Ultrasound lung comets</i></p>	<p>2</p> 		
	<p>3</p> 		
<p><u>Lung, posterolateral base</u> <i>Effusion (Pleural) sign</i></p>	<p>4</p> 		
	<p>5</p> 		
<p><u>Subcostal 4 chamber</u> <i>Subcostal RVE sign</i></p>	<p>6</p> 		
<p><i>Subcostal IVC sign</i></p>	<p>7</p> 		

VIEWS

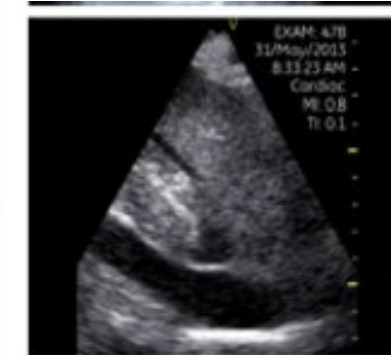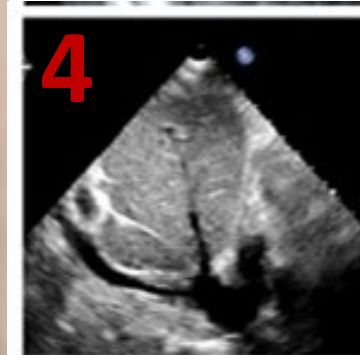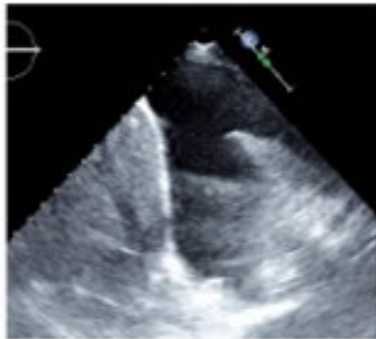
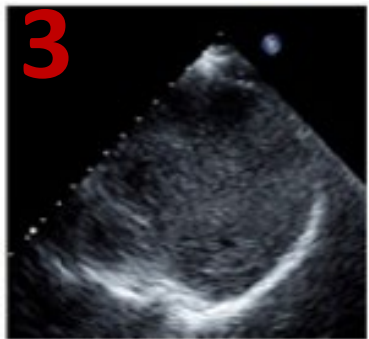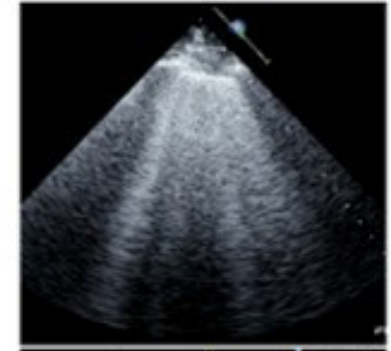
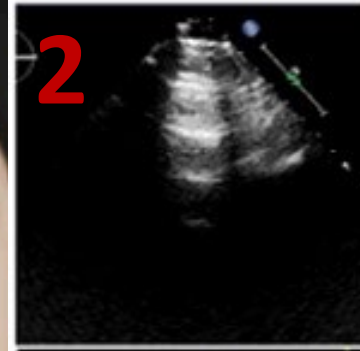
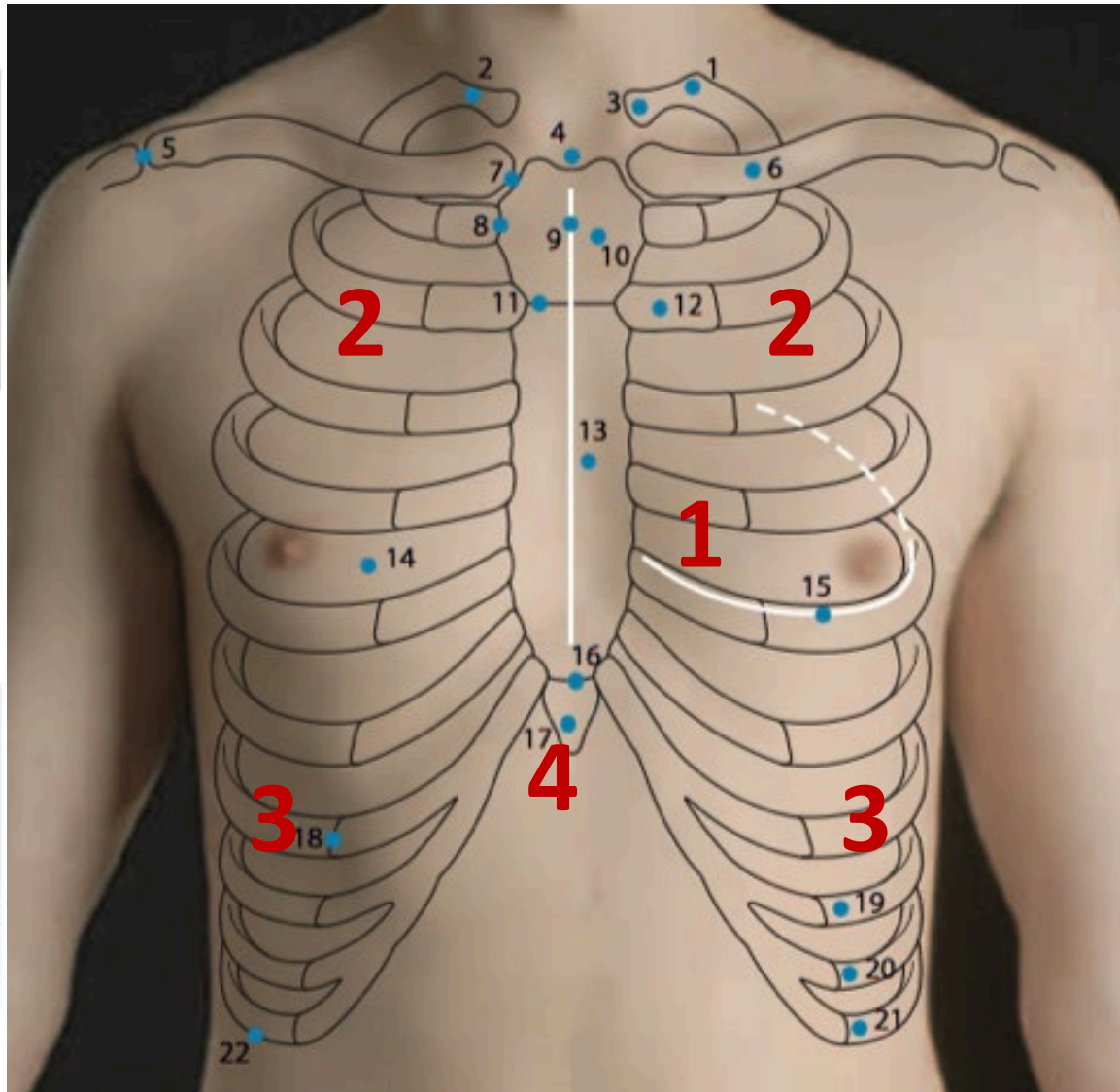
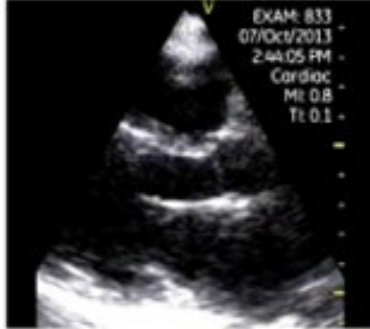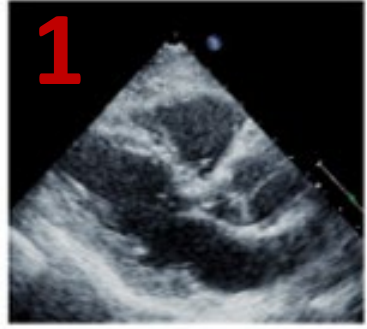


Figure 1 Surface anatomy of anterior chest wall.

<https://passmyclinicalexamination.com/the-chest-wall/>

LET'S PRACTICE!