



January 22, 2022

Resident Poster Submissions Part 2



Status Epilepticus with an Acute Kidney Injury: An Unusual Culprit

Ayesha Malik, MD; Aqsa Khalid, MD; Adiran Sequeira, MD



INTRODUCTION

- Acute uric acid nephropathy (AUN) is characterized by oliguric renal failure due to overproduction of uric acid and its deposition in renal tubules.
- This typically occurs in cases of leukemias and lymphomas or following chemotherapy due to tumor lysis.
- A few cases have reported uric acid crystals in the urine of patients with status epilepticus with only mild elevations of uric acid and CPK (1,2,5).

CASE PRESENTATION

- A 64 year old woman with history of glioblastoma multiforme status post multiple craniotomies for resection, was admitted with status epilepticus.
- She required a midazolam drip and was intubated for airway protection.
- She subsequently became bradycardic, hypothermic and anuric and remained so for the next 3 days despite 5L of crystalloids.
- Her creatinine increased from 0.5 to 1.8mg/dl and she developed anasarca.
- Laboratory studies were significant for BUN 28, CO₂ 17mmol/L, CPK 18U/L and BNP 554 pg/ml.
- Her renal ultrasound was normal.
- Initial urine analysis showed a pH of 5 with bland sediment. A second bedside urine analysis performed a few days later revealed abundant uric acid crystals, but no muddy brown casts or RTECs.
- In the absence of any other etiology for the AKI, a diagnosis of acute uric acid nephropathy was made
- She was started on a bicarbonate drip along with furosemide to keep urine pH 6.5-7.
- Her urine output consequently increased and creatinine normalized.

DISCUSSION

- Seizures can cause direct nucleotide breakdown, producing increased levels of adenosine which is converted to uric acid in the liver.
- Serum nucleotidase activity can be elevated for several hours after seizures, possibly leading to increased systemic breakdown of adenosine triphosphate and generation of urate (1).
- Moreover, seizures cause dehydration due to sweating and hyperthermia resulting in increased water reabsorption from renal tubules. This increases concentration of uric acid in urine, allowing it to precipitate in renal tubules.
- Uric acid can also cause direct damage to kidneys by activating pro-inflammatory mediators and inducing renal vasoconstriction (3).

CONCLUSION

- Urinalysis with microscopic examination of urine sediment is an important clinical tool for diagnosing AKI.
- Varghese et al showed that 20-25% cases which yielded no diagnosis on first urine microscopy, showed casts representing acute tubular injury on a second or third urine microscopy done 2-3 or 4-6 days later.(4) Serial exams may be helpful in uncovering the cause of AKI which a single inspection may miss.

REFERENCES

1. C. Patel, C. P. Wilson, N. Ahmed, Y. Hattab, & quot; Acute Uric Acid Nephropathy following Epileptic Seizures: Case Report and Review& quot;, Case Reports in Nephrology, vol. 2019, Article ID 4890287, 6 pages, 2019.
2. N Makki, G Hajj, GA Schmidt. "Seizure-induced acute urate nephropathy: case report and review." Chest. 2013 Aug;144(2):666-669. doi: 10.1378/chest.12-2129.
3. A. A. Ejaz, W. Mu, D.-H. Kang et al., "Could uric acid have a role in acute renal failure?" Clinical Journal of the American Society of Nephrology, vol. 2, no. 1, pp. 16-21, 2007.
4. V. Varghese, M. S. Rivera, A. A. Alalwan, A. M. Alghamdi et al., "Diagnostic Utility of Serial Microscopic Examination of the Urinary Sediment in Acute Kidney Injury" Kidney360 February 2021, 2 (2) 182-191.
5. J. M. Cote, A Berube, G. Bollee. Association of hyperuricemia with acute kidney injury: case series report among patients hospitalized with general tonic clonic seizures. Can J Kidney Health Dis 2020 Dec 8;7: 2054358120977386

Sweet Spots:

Recurrent Staphylococcal Skin and Soft Tissue Infections in a Patient with Uncontrolled Diabetes

Farhad Ghamsari, Lauren Ogawa, Chayan Chakraborti



TULANE UNIVERSITY
SCHOOL of MEDICINE

Tulane University School of Medicine, Department of Medicine, New Orleans, LA

Introduction

The association of diabetes with infection is well recognized, with diabetes being classified by the World Health Organization as a cause of secondary immune deficiency. Recognition of its role in recurrent infection, and thus the importance of adequate long-term glycemic control, cannot be overstated.

Case Description

A 49-year-old man without prior history presented with leg pain and multiple well demarcated lumps on his arms and legs. Imaging revealed a 14cm complex abscess in the distal sartorius muscle. Ultrasound imaging of the skin lesions revealed simple fluid collections later confirmed to be abscesses. He was taken to the OR promptly for surgical drainage of the abscesses.

Laboratory studies were significant for a white blood cell count of $23.2 \times 10^9/L$ (79% Neutrophils), Glucose of 358 mg/dL, and HbA1c of 14.1%. Additional studies included a CRP of 40.6 mg/dL, a negative Rapid HIV test, and a negative T-Spot TB Test. Deep wound and blood cultures grew methicillin sensitive *Staphylococcus aureus* (MSSA). He was discharged with outpatient IV Nafcillin therapy.

Two months later, he presented again with cellulitis and osteomyelitis of his right middle finger; cultures and biopsy again grew MSSA. Echocardiography showed no vegetations. He completed 6 weeks of IV Cefazolin therapy and with renewed focus on glycemic control, he and his outpatient providers were able to bring his HbA1c down to <6%.

He has since had no further recurrences.

Figure 1 – Conditions Associated with Secondary Immune Deficiency

Immunosuppressive therapy

- Cytotoxic chemotherapy for malignancy
- Treatment of autoimmune disease
- Treatment of rejection following solid organ transplantation

Microbial infection

- Viral infection: HIV/AIDS, HSV1/2, EBV, CMV, VZV
- Bacterial infection (superantigens)
- Mycobacterial infection
- Parasitic infestation

Malignancy

- Hodgkin disease, CLL, Multiple myeloma
- Solid tumors

Disorders of biochemical homeostasis

- Diabetes mellitus
- Renal insufficiency/dialysis
- Hepatic insufficiency/cirrhosis
- Malnutrition

Autoimmune disease

- Systemic lupus erythematosus
- Rheumatoid arthritis

Environmental exposure

- Radiation: Ionizing, Ultraviolet
- Toxic chemicals
- Burns

Other

- Stress, Pregnancy, Aging
- Asplenia / Hyposplenism

Discussion

Recurrent skin and soft tissue infections raise suspicion for underlying primary immune deficiency, but most cases are attributable to secondary causes. These secondary immune deficiencies include diabetes mellitus, chronic skin disease, infections (eg HIV, HBC, HCV, TB), as well as iatrogenic, vascular, auto-immune mediated, and malignancy-related causes.

Diabetes impacts immune defenses through multiple mechanisms: hyperglycemia affects neutrophil chemotaxis and phagocytosis; microangiopathy, vascular insufficiency, and tissue hypoxia promote anaerobic bacterial growth and lessen antibiotic penetration; and neuropathy promotes skin insensitivity and ulceration.

More insidious causes of immune dysfunction such as leukemia/lymphoma, nephrotic syndrome, and primary disorders of phagocytes should be considered in the right population.

This patient's infections were attributed to his uncontrolled diabetes and ceased to recur with adequate management.

References

1. Johnston SL. Clinical immunology review series: an approach to the patient with recurrent superficial abscesses. *Clin Exp Immunol*. 2008;152(3):397-405. doi:10.1111/j.1365-2249.2008.03640.x
2. Antonelou M, Knowles J, Siddiqi S, Sharma P. Recurrent cutaneous abscesses caused by PVL-MRSA. *BMJ Case Rep*. 2011;2011:bcr0120113680. Published 2011 Jun 29. doi:10.1136/bcr.01.2011.3680
3. Pozzilli P, Leslie RD. Infections and diabetes: mechanisms and prospects for prevention. *Diabet Med*. 1994 Dec;11(10):935-41. doi: 10.1111/j.1464-5491.1994.tb00250.x.
4. Berbudi A, Rahmadika N, Tjahjadi AI, Ruslami R. Type 2 Diabetes and its Impact on the Immune System. *Current Diabetes Reviews*. 2020 ;16(5):442-449. DOI: 10.2174/1573399815666191024085838.
5. Pasternack MS. Approach to the adult with recurrent infections. In: UpToDate, Post TW (Ed), UpToDate, Waltham, MA. (Accessed on November 12, 2021.)

Warfarin:

Adverse Drug-Drug Interactions with Commonly Prescribed Medications

Farhad Ghamsari, Joy Fesen, Anjali Niyogi

Tulane University School of Medicine, Department of Medicine, New Orleans, LA



TULANE UNIVERSITY
SCHOOL of MEDICINE

Introduction

Warfarin has a notoriously narrow therapeutic index requiring close monitoring and attention to co-prescribing. This case serves as a reminder of warfarin's complex pharmacodynamics and kinetics and the need for awareness when co-prescribing medications with warfarin.

Case Description

A 42-year-old incarcerated man with past medical history of renal transplant and mechanical mitral valve on warfarin presented with oliguria of two weeks and worsening fevers, gross hematuria, and hematochezia for four days.

History revealed recent diagnosis of urinary tract infection (UTI) treated at the jail first with ciprofloxacin then doxycycline. Jail records demonstrated frequent visits to the jail infirmary over a two week period of time with acetaminophen administration and multiple lab draws showing increasing INR during treatment. Upon admission, the patient was febrile without leukocytosis. There was no icterus, hepatomegaly, nor splenomegaly. Initial laboratory studies revealed down trending hemoglobin of 9.5 mg/dL, elevated BUN and Creatinine, and an elevated INR of 23.9.

Diagnosis of sepsis secondary to pyelonephritis was made complicated by hematuria and hematochezia from a supratherapeutic INR. The patient was treated with oral vitamin K, fluids, and antibiotics. After correction of the INR, resolution of the infection and kidney injury, the patient experienced a prolonged anticoagulation course on an IV Heparin bridge and oral Warfarin while awaiting return to therapeutic INR.

Figure 1 – Warfarin Metabolism Overview

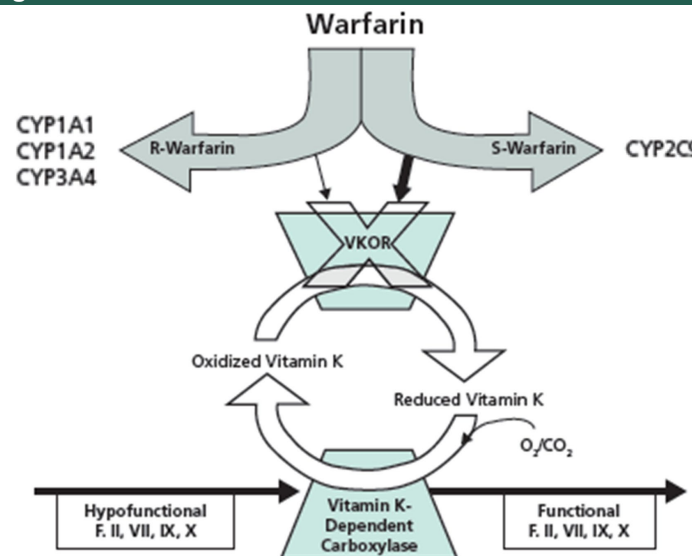


Figure 2 - The Major Mechanisms of Warfarin Interactions

Direct GI Injury

- Anti-Inflammatory Agents: NSAIDs, including selective COX-2 Inhibitors

Altered Gut Vitamin K Synthesis

- Antibiotics: Co-trimoxazole, Metronidazole, Macrolides, Fluoroquinolones

Interference with Vitamin K Cycle

- Acetaminophen (NAPQI Metabolite)

Altered Warfarin Metabolism

- Inhibition/Induction of CYP 2C9: Amiodarone, Anti-depressants (SSRI)
- Antibiotics - Fluconazole, Miconazole, Rifampin
- Alternative Remedies: Ginkgo biloba, dong quai, fenugreek, chamomille, St. John's Wort

Altered Platelet Function

- ASA, Clopidogrel, Ticlopidine

Discussion

Warfarin inhibits Vitamin K Epoxide Reductase Complex (VKORC), which converts the epoxide form of Vitamin K to the reduced form necessary for production of the vitamin K dependent coagulation factors (II, VII, IX, and X). Owing to Factor II's long plasma half-life, the full clinical efficacy of warfarin is delayed by about 3 days. Acetaminophen at high doses is believed to elevate INR via its NAPQI metabolite irreversibly inhibiting vitamin K dependent carboxylation and subsequent factor production. Antibiotics not only decrease gut flora production of Vitamin K, but also impact the CYP450 system of liver enzymes, which are well known to mediate warfarin metabolism. Finally, high doses of Vitamin K (>10mg) have been associated with warfarin resistance that may last up to 1-2 weeks, delaying the return to therapeutic levels; an effect that likely extended the patient's hospital course.

References

1. Juurlink DN. Drug interactions with warfarin: what clinicians need to know. CMAJ. 2007;177(4):369-371. doi:10.1503/cmaj.070946
2. Ansell J, Hirsch J, Hylek E, Jacobson A, Crowther M, Palareti G; American College of Chest Physicians. Pharmacology and management of the vitamin K antagonists: American College of Chest Physicians evidence-based clinical practice guidelines. 8th ed. Chest. 2008;133(suppl 6):S160-S198. doi: 10.1378/chest.08-0670.
3. Westfall LK, Mintzer DL, Wiser TH. Potentiation of warfarin by tetracycline. Am J Hosp Pharm. 1980;37:1620-1625.
4. Searcy RL, Simms NM, Foreman JA, et al. Evaluation of the blood-clotting mechanism in tetracycline-treated patients. Antimicrob Agents Chemother. 1965;179-183.
5. Caraco Y, Rubinow A. Enhanced anticoagulant effect of coumarin derivatives induced by doxycycline coadministration. Ann Pharmacother. 1992;26:1084-1086.
6. Rios JF. Haemorrhagic diathesis induced by antimicrobials. JAMA. 1968;205:142.

Warfarin as a risk factor for severe calciphylaxis in ESRD patients

Brenda Cruciani MD-PGY-2; Abdul Hussain Vali MD-PGY-2; Chelsea McNamee MD-PGY-2; Rohit Bhardwaj MD; Aaron DeWitt MD

Baton Rouge General Internal Medicine Residency Program, affiliate of Tulane University School of Medicine

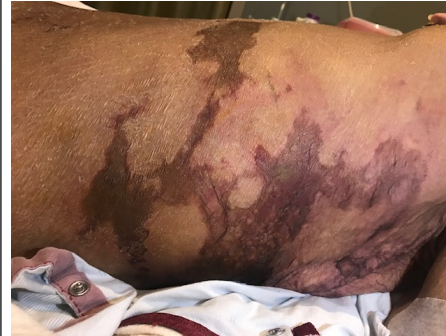Introduction

Calciphylaxis, or calcific uremic arteriopathy, is a poorly understood disorder. It is characterized by calcium accumulation in arterioles and capillaries of subcutaneous fat and dermis, leading to blood vessel occlusion. It often presents as painful ulcers in areas with the greatest adiposity. It is most commonly seen in patients with end-stage renal disease (ESRD) on dialysis. However, multiple risk factors have been attributed to this syndrome, including hyperphosphatemia, hypercalcemia, hyper/hypoparathyroidism, autoimmune conditions, diabetes mellitus, obesity, female sex, chronic steroid use, and warfarin therapy, which has been implicated as a significant risk factor for the development of calciphylaxis.

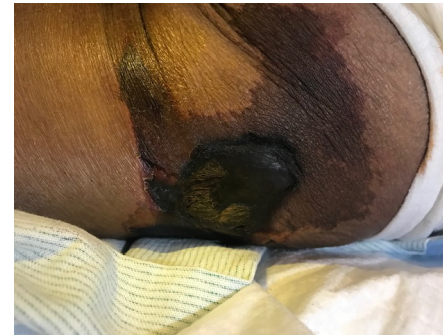Case Description

A 31-year-old female with systemic lupus erythematosus on chronic steroid use, ESRD on hemodialysis, mechanical aortic valve replacement on warfarin therapy presented to the emergency department with a sacral decubitus ulcer. Physical examination was pertinent for an unstageable sacral ulcer with large eschar associated with severe tenderness. Laboratory results revealed elevated INR (2.7). The patient underwent wound debridement. However, she continued to complain of severe generalized skin pain and was noted to develop multiple ecchymotic-type skin lesions throughout her arms, abdomen, back, and buttocks. Initially, the etiology was unclear, and anticoagulation was switched to Lovenox. Rheumatology was consulted, and extensive autoimmune workup was obtained, ruling out active lupus flare, anticardiolipin syndrome, heparin-induced necrosis, and vasculitides. Lesions continued to rapidly progress, advancing to necrosis. Skin punch biopsies showed calcifications in the walls of small and medium-sized vessels within the subcutaneous adipose tissue, consistent with calciphylaxis. She was initiated on sodium thiosulfate therapy with hemodialysis, continued on Lovenox, and given a short-term trial of vitamin K therapy. The patient was discharged to a long-term acute care facility with the above treatment plan.

Figures and Labs



Picture 1: Ecchymotic lesions to right truck



Picture 2: Necrotic lesion to right buttocks

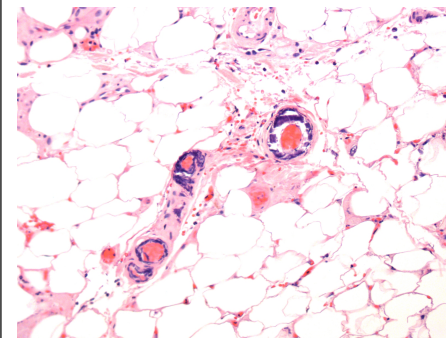


Figure 1: Pathology results of skin biopsy demonstrating small calcified blood vessels consistent with calciphylaxis.

Discussion/Conclusion

The most common reason for the development of calciphylaxis is a lack of molecular calcification inhibitors in the vessel wall, commonly attributed to vitamin K deficiency, which prevents matrix G1a protein activation (a potent inhibitor of calcification), promoting vascular calcification.

Currently, treatment options are not very effective as they focus on reversal rather than the prevention of lesions. It consists of sodium thiosulfate as a calcium chelator and antioxidant, wound care with debridement, and hyperbaric oxygen therapy depending on disease progression. Therefore, given the significant morbidity and mortality of calciphylaxis, prevention is critical, and the treatment goal should focus on reducing risk factors, especially vitamin K deficiency. Consequently, vitamin K supplementation has emerged as a potential candidate for the standard of care in treating calciphylaxis. However, there is still a lack of reliable data regarding effective standard therapy.

This case was challenging because the patient required warfarin therapy after mechanical aortic valve replacement, which increased her chances of developing calciphylaxis through Vitamin K deficiency along with all her other known risk factors. Therefore, in patients with multiple existent risk factors, physicians should use warfarin with caution to prevent the development of calciphylaxis. Furthermore, Eliquis has recently been considered as an alternative anticoagulant for patients with a significant risk for calciphylaxis. However, more studies must be conducted to assess the effectiveness and safety of this therapy in hemodialysis patients.

References

- Al-ani M, Parperis K. Warfarin-induced calciphylaxis. BMJ Case Rep. 2016 Jan;2016:bcr2015214142.
- Nigwekar SU. Calciphylaxis (calcific uremic arteriopathy). In: UpToDate, Post TW (Ed), UpToDate, Waltham, MA. (Accessed on January 20, 2021.)
- Ali F, Matharu T, Nagesh RV, Gordon Spratt E, Friedman BJ. Calciphylaxis in Stage 3 Chronic Kidney Disease on Apixaban Successfully Treated With Sodium Thiosulfate: A Case Report. Wounds. 2020 Sep; 32(9):E42-E49.
- Banerjee C, Woller SC, Holm JR, Stevens SM, Lahey MJ. Atypical calciphylaxis in a patient receiving warfarin then resolving with cessation of warfarin and application of hyperbaric oxygen therapy. Clin Appl Thromb Hemost. 2010 Jun;16(3):345-50.
- Bennett WM. Should dialysis patients ever receive warfarin and for what reasons? Clin J Am Soc Nephrol. 2006 Nov;1(6):1357-9.
- Bhamri A, Del Rosso JQ. Calciphylaxis: a review. J Clin Aesthet Dermatol. 2008 Jul;1(2):38-41.
- Chang JJ. Calciphylaxis: Diagnosis, Pathogenesis, and Treatment. Adv Skin Wound Care. 2019 May; 32(5):205-215.
- Crotty R, Nazarian RM, Song PI, Van Cott EM. Heparin, warfarin, or calciphylaxis? Am J Hematol. 2014 Jul;89(7):785-6.
- Hafji J, Deegan P, Brail R, Norris P. Warfarin-induced calciphylaxis successfully treated with sodium thiosulfate. Australas J Dermatol. 2013 May;54(2):133-5.
- Nigwekar SU. Calciphylaxis. Curr Opin Nephrol Hypertens. 2017 Jul;26(4):276-281.
- Nigwekar SU, Kroshinsky D, Nazarian RM, Goverman J, Mathotra R, Jackson VA, Kamdar MM, Steele DJ, Thadhani RI. Calciphylaxis: risk factors, diagnosis, and treatment. Am J Kidney Dis. 2015 Jul;66(1): 133-46.
- Nigwekar SU, Thadhani R, Brandenburg VM. Calciphylaxis. N Engl J Med. 2018 Jul;379(4):399-400.
- Saifan C, Saad M, El-Charabaty E, El-Sayegh S. Warfarin-induced calciphylaxis: a case report and review of literature. Int J Gen Med. 2013 Aug;6:665-9.
- Shafiee MA, Akbarian F, Memon KK, Aarabi M, Shahideh Y, Johnson D, Sharif U. Late-onset Warfarin Induced Skin Necrosis: In a Hemodialysis Patient. J Kidney. 2017 Jun;3:141.
- Zoccali C, Mallamaci F. A New Treatment for Calciphylaxis in Hemodialysis Patients? Am J Nephrol. 2018 Sep;48(3):165-167.

Treating Refractory Rhabdomyolysis with Short-Term High-Dose Steroids

Brenda Cruciani MD-PGY-2; Abdul Hussain Vali MD-PGY-2; Chelsea McNamee MD-PGY-2, Rohit Bhardwaj MD; Vasudev Tati MD

Baton Rouge General Internal Medicine Residency Program, affiliate of Tulane University School of Medicine

Introduction

Rhabdomyolysis is a severe disease characterized by muscle death and rapid release of cellular contents into the bloodstream. Symptoms range from mild to severe, including life-threatening electrolyte imbalances and acute kidney injury in the setting of hypovolemia and heme pigment-induced cytotoxic tubular damage. This disease process can be triggered by various etiologies, including trauma, seizures, alcohol, drugs (statins, MDMA), and viral infections. Specifically, Influenza A virus has been described as an underlying etiology of rhabdomyolysis. Furthermore, a few case reports have suggested short-term, high-dose steroid use as a treatment option for refractory disease.

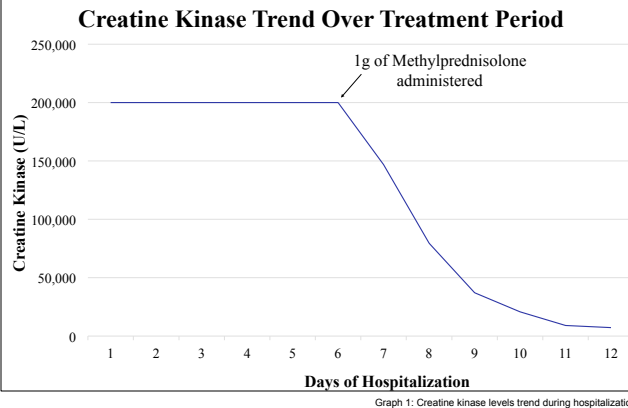
Case Description

A 29-year-old male presented to the emergency department complaining of persistent myalgia, fevers, intractable nausea and vomiting, and dark urine two days after being diagnosed with Influenza A at an urgent care. On presentation, the patient was afebrile and tachypneic. Physical examination was pertinent for diffuse muscle tenderness, particularly in bilateral thighs and calves, without any focal neurologic deficits. Laboratory results demonstrated creatinine of 2.9 mg/dL, potassium of 2.8 mmol/L, phosphorus of 7.1 mg/dL, AST 1,704 U/L and creatine kinase of > 200,000 U/L. Urinalysis showed 3+ blood but no red blood cells. The patient was promptly started on aggressive IV hydration with sodium bicarbonate. Creatine kinase level was noted to be persistently elevated at > 200,000 U/L. Kidney function continued to rapidly decline (creatinine trended up to 7.0), leading to oliguria and worsening of electrolyte derangements.

Case Description

Due to progressive decline, the patient was subsequently initiated on renal replacement therapy. Despite three days of hemodialysis and aggressive IV crystalloids, his condition failed to improve, with no significant changes to laboratory values. Therefore, a decision was made to give short-term high-dose steroid (1g of methylprednisolone), after which creatine kinase drastically trended down to 7,254 u/L.

Images and Labs



Laboratory	Day 1	Day 3	Day 7
BUN	30 mg/dL	49 mg/dL	40 mg/dL
Creatinine	2.91 mg/dL	7.08 mg/dL	5.58 mg/dL
Calcium	8.4 mg/dL	8.1 mg/dL	9.2 mg/dL
Sodium	137 mmol/L	136 mmol/L	136 mmol/L
Potassium	2.8 mmol/L	4.1 mmol/L	5.8 mmol/L
Bicarbonate	19 mmol/L	24 mmol/L	26 mmol/L
Phosphorus	7.1 mg/dL	8.0 mg/dL	3.8 mg/dL
ALT	168 U/L	307 U/L	538 U/L
AST	1,704 U/L	2,523 U/L	1,316 U/L
Creatine Kinase	> 200,000 U/L	> 200,000 U/L	> 146,900 U/L
Hemoglobin	15.0 g/dL	11.7 g/dL	11.7 g/dL
Urinalysis: Red color, 3+ protein, 3+ blood, WBC 0-5, RBC 0			

Table 1: Laboratory values from day 1, 3 and 7.

Discussion/Conclusion

Influenza A infection has been associated with the development of rhabdomyolysis. In this case, refractory disease resistant to standard therapy, which usually involves aggressive IV hydration with sodium bicarbonate and renal replacement therapy. Currently, there are no set guidelines for additional treatment in case the standard of care fails. However, it has been reported that the treatment of rhabdomyolysis with steroids, although poorly understood, results in a decreased immune response against myocytes, aiding with the decline of muscle injury. Therefore, as supported by this case, short-term high-dose steroid use alongside standard therapy is an effective treatment option for therapy-resistant rhabdomyolysis of various etiologies. It halts the disease process and optimizes disease outcome. However, it requires further analysis into its efficacy and validity to consider as a potential addition to the standard of care for severe refractory disease.

References

- Antoon JW, Chakraborti C. Corticosteroids in the treatment of alcohol-induced rhabdomyolysis. *Mayo Clin Proc.* 2011 Oct;86(10):1005-7.
- Miller ML. Clinical manifestations and diagnosis of rhabdomyolysis. In: UpToDate, Post TW (Ed), UpToDate, Waltham, MA. (Accessed on December 10, 2021.)
- Fadila MF, Wool KJ. Rhabdomyolysis secondary to influenza a infection: a case report and review of the literature. *N Am J Med Sci.* 2015 Mar;7(3):122-4.
- Gonakoti S, Bahirwani J, Maddala RNM, Vidyasagar S. A case of H3N2 complicated by acute kidney injury secondary to rhabdomyolysis. *BMJ Case Rep.* 2018 Apr; 2018:bcr2018224334.
- Ibrahim AM, Manthri S, Soriano PK, Bhatti V, Mamillapalli CK. Rhabdomyolysis Associated with Influenza A Virus Infection. *Cureus.* 2018 Jun;10(6):e2786.
- Shivam Krishna Patel, Azeem Mohammed, Rajan Kapoor (2019) Role of Corticosteroids in Rhabdomyolysis. *Integr J Nephro Urol Stud.* 2019 Dec;1(1):1-4.
- Torres PA, Helmstetter JA, Kaye AM, Kaye AD. Rhabdomyolysis: pathogenesis, diagnosis, and treatment. *Ochsner J.* 2015;15(1):58-69.
- Zarlasht F, Salehi M, Sattar A, Abu-Hishmeh M, Khan M. Short-Term High-Dose Steroid Therapy in a Case of Rhabdomyolysis Refractory to Intravenous Fluids. *Am J Case Rep.* 2017 Oct;18:1110-1113.

Purple Urine Bag Syndrome Due to *Enterococcus faecalis*

B Roubique MD, E Bourgeois MD, G Sapora MD, R McCarron MD, L Gawey BS, C Pesson BS, M Morvant BS

Department of Internal Medicine, Louisiana State University Health Sciences Center, New Orleans, LA

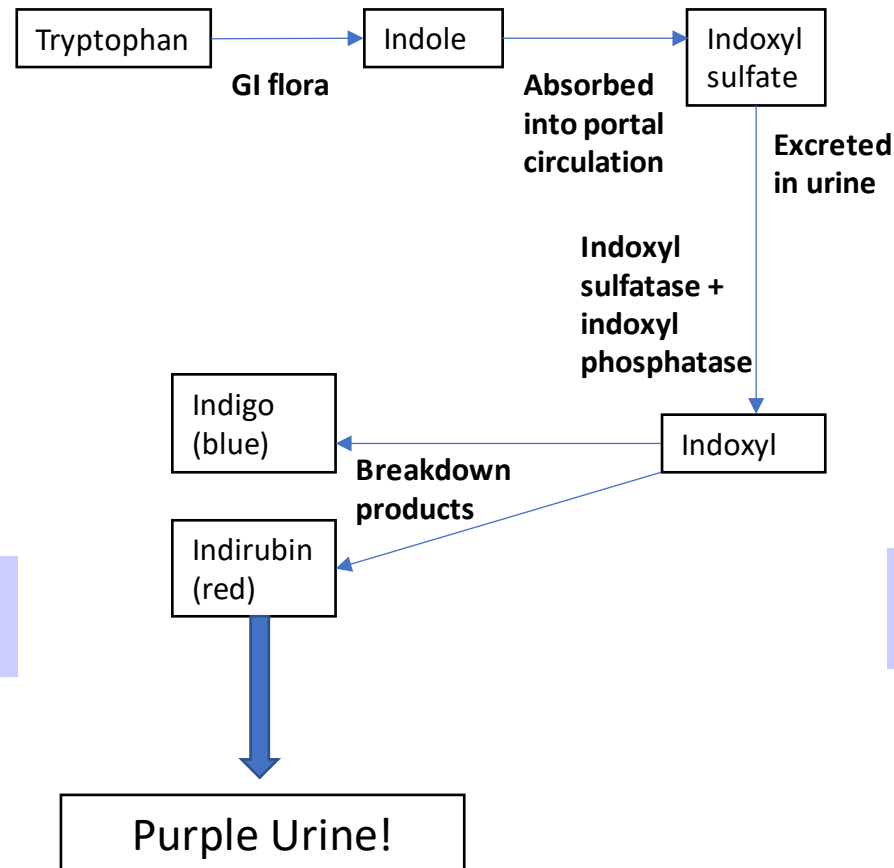
INTRODUCTION

- Purple urine bag syndrome (PUBS) is a rare manifestation of a urinary tract infection (UTI).
- It is typically seen in women and chronically debilitated patients with long-term indwelling urinary catheters, although there have been reports of PUBS in chronic renal failure patients who are dependent on hemodialysis or those with nephrostomy tubes.
- The purple color of the urine is due to breakdown products formed by bacterial enzymes in the urine, and the common bacteria capable of producing these enzymes include *Providencia* spp, *Klebsiella*, and *Proteus*.
- Many more bacterial species have been reported in association with PUBS, including *Escherichia coli*, *Enterococcus* spp, *Morganella morganii*, and *Pseudomonas aeruginosa*.

CASE PRESENTATION

- A 21-year-old male with recent history of gunshot wound to the abdomen complicated with numerous intraabdominal injuries and infections requiring percutaneous nephrostomy tube placement, presented to the hospital about 3 months later with a 3-day history of green nephrostomy drainage.
- He was complaining of fever, chills, headache, and non-bloody emesis, denying any other complaints.

DIAGRAM



HOSPITAL COURSE

- On hospital day two, his urine, urine bag, and nephrostomy tubing were dark purple.
- He was started on broad spectrum IV antibiotics for sepsis secondary to pyelonephritis and underwent nephrostomy tube exchange two days later with only complication of mild flank pain.
- Urinalysis from the purple urine bag contained urinary sediment with greater than 100 WBC/hpf and positivity for leukocyte esterase.
- Urine cultures yielded 50,000 CFU/mL of *Stenotrophomonas maltophilia* and greater than 100,000 CFU/mL of *Enterococcus faecalis*.
- He was switched to a course of Levofloxacin 750mg PO and amoxicillin 875mg every 12 hours for a total of 14 days post nephrostomy tube replacement.
- His urine was no longer purple in color.

DISCUSSION

- PUBS is a benign condition but can be distressing for patients who are unaware of this phenomenon.
- PUBS is treated by treating the underlying UTI, as well as ensuring proper care and sanitary practices for upkeep of urinary catheters.
- It is important for physicians to be able to recognize PUBS as it may signal underlying recurrent UTIs due to inadequate care of urinary catheters.



Baton Rouge General

Internal Medicine Residency Program

Mucinous adenocarcinoma of perianal region: a rare entity

Rameela Mahat MD, Gift Echefu MD, Deepti Kantamani MD, Maheswar Rao MD

Baton Rouge General Medical Center, Baton Rouge, Louisiana



Introduction

- ❑ Mucinous adenocarcinoma (MA) of the perianal region is an extremely rare malignancy accounting for only 6.9% of all anal neoplasms and 2–3% of all gastrointestinal malignancies [2,3].
- ❑ It may be sporadic or may arise from preexisting abscess cavity or fistula.
- ❑ This report shows sporadic or denovo development of MA in the absence of underlying perianal abscess or fistula. To the best of our knowledge, this is the rarest of this type.

Case Description

- ❑ A 68-year-old female was seen in the gastroenterology clinic. The patient had been well until approximately 1 month earlier, when she noted small amounts of bright red blood in her stools, on the toilet paper and in the toilet bowl. Symptoms were associated with constant anorectal pain lasting for hours, exacerbated with bowel movements. She also reported constipation, anal itching, and mucous discharge admixed with stool for the same duration. She reported no diarrhea, abdominal pain, nausea, vomiting, or weight loss.
- ❑ Her Medical History was significant for Crohn's disease with partial small bowel resection, currently in remission without medication, Essential hypertension and arthritis.
- ❑ Digital rectal examination showed a firm, circumferential appearing mass with mild tenderness without evidence of abscess, anorectal fistula or Paget disease. She underwent a colonoscopy revealing a 2cm X2 cm, infiltrative, sessile ulcerated, oozing, and partially obstructing, mass in the anal canal. Cold forceps biopsy was obtained.
- ❑ Pathological examination of biopsy specimen of the anal mass showed poorly differentiated invasive adenocarcinoma with mucinous and signet ring cell features.
- ❑ Initial Computed tomography of the abdomen and pelvis reportedly showed an inhomogeneous asymmetric appearance of the anorectal junction.
- ❑ Staging evaluation with whole body PET scan showed 4.2 cm hypermetabolic segment of the anal canal with associated soft tissue fullness. There was no evidence of regional or distal metastasis. Computed Tomography (CT) chest was unremarkable. The level of carcinoembryonic antigen was less than 2.1 ng per milliliter (reference range, 0 to 4.7).
- ❑ Pelvic MRI further revealed 6 cm, polypoid mass, secreting mucous, in the lower rectum, 0 cm from the anal verge, with sphincter involvement and suspected meso-rectal and superior rectal lymph node involvement. This case was diagnosed as Anal canal mucinous signet ring cell carcinoma, stage T3dN1M0 according to TNM staging of the American Joint Committee on cancer.
- ❑ The multidisciplinary team recommended neoadjuvant chemoradiation therapy followed by surgery. Accordingly, she completed preoperative chemotherapy with capecitabine with concurrent radiotherapy. Follow up MRI pelvis following chemoradiation showed significantly decreased bulk of the anal mucinous tumor with persistent invasion of the left posterolateral sphincter without suspicious lymph node involvement. She was restaged as T4b N0. After wards, she underwent robotic Abdominoperineal resection a month later.
- ❑ Final histopathology following APR showed moderately differentiated mucinous adenocarcinoma of the anal canal. She did well following surgery. She is now undergoing treatment with chemotherapy with regimen of capecitabine and oxaliplatin.

Figures

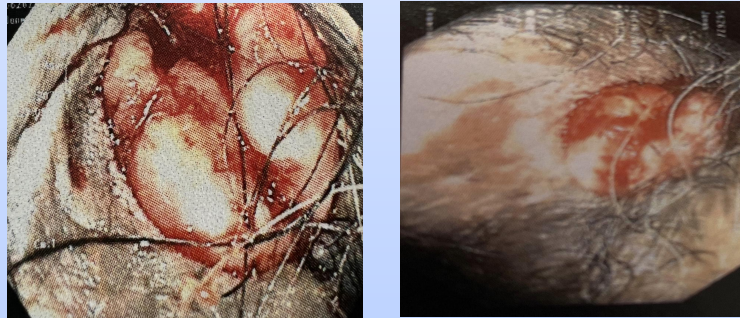
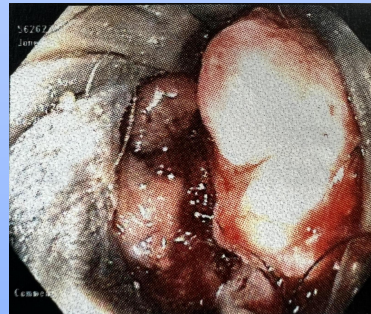


Figure : Endoscopy revealing a 2cm X2 cm, infiltrative, sessile ulcerated, oozing, and partially obstructing, mass in the anal canal



Discussion

- ❑ Mucinous adenocarcinoma of the perianal region is an extremely rare variant of anal canal tumor with poor prognosis [1].
- ❑ It is more aggressive than SCC and usually diagnosed in later stages.
- ❑ Rectal bleeding is the most common initial presentation. Other presentations are perianal pain or itching, sensation of rectal mass, change in stool caliber, altered bowel habits, sense of incomplete evacuation, obstruction due to the growth obscuring the anal opening or an ulceroproliferative growth or palpable mass in the perianal region with bloody or mucoid discharge [3]. About 20% of people remain asymptomatic.
- ❑ Colonoscopy with biopsy and histopathology is the gold standard of diagnosis. Diagnosis is based on histological assessment, with more than 50% of the lesion containing extracellular mucin.
- ❑ Pelvic MRI is the best image technique, since the abundance of mucin in these tumors gives them a unique radiological appearance, which results in a significant hyper-intense signal on T2-weighted images [1]
- ❑ Because of the rarity very few cases have been reported. There is limited data regarding treatment and outcomes. Treatment includes neoadjuvant chemoradiation followed by surgery.
- ❑ The prognosis is poor with reported survival rates of 2-48 months.

Conclusion

- ❑ Mucinous adenocarcinoma of the perianal region is an extremely rare malignancy. It remains a therapeutic challenge for physicians because of its rarity, unclear pathogenesis, non-specific presentation, and indolent disease course leading to an inferior prognosis [1,2,3]
- ❑ As a result, there is limited data regarding treatment and outcomes. Robust, consistent reporting of clinical information and increased enrollment in clinical trials are warranted.

Reference

- [1]Díaz-Vico T, Fernández-Martínez D, García-Gutiérrez C, et al. Mucinous adenocarcinoma arising from chronic perianal fistula-a multidisciplinary approach. J Gastrointest Oncol. 2019;10(3):589-596. doi:10.21037/jgo.2019.01.11
- [2]Feo CF, Veneroni S, Santoru A, et al. Perianal mucinous adenocarcinoma with dysplastic polyps of the colon: A case report. Int J Surg Case Rep. 2021;78:99-102. doi:10.1016/j.ijscr.2020.12.008
- [3]Purkayastha A, Sharma N, Dutta V, Bisht N, Pandya T. Mucinous adenocarcinoma of the perianal region: an uncommon disease treated with neoadjuvant chemoradiation. Transl Gastroenterol Hepatol. 2016;1:52. Published 2016 Jun 21. doi:10.21037/tgh.2016.06.03
- [4]Ibbawi AM, Simianu VV, Millie M, Soriano P. Wide local excision of perianal mucinous adenocarcinoma. J Clin Oncol. 2015;33(4):e16-e18. doi:10.1200/JCO.2012.48.5722

Covid-19 Myocarditis In A Rare Case Of Streptococcus Pyogenes Pneumonia

Syed R. Hussain, D.O

 **OchsnerHealth**

Department of Internal Medicine, Ochsner Medical Center, New Orleans, LA.

INTRODUCTION

Early detection and treatment of COVID-19 associated cardiac inflammation continues to remain a challenge among COVID-19 patients. We herein report a case from the early days of the pandemic that saw such complications develop in an otherwise healthy young male and were further exacerbated by a rare case of necrotizing, strep pyogenes bacterial pneumonia. This case from the early days of the COVID-19 pandemic depicts an overlap of two relatively rare but potentially deadly conditions.

CASE DESCRIPTION

A 21 year old man who recently started prophylactic Tamiflu post-exposure to his girlfriend presented to our hospital after he developed progressively worsening SOB, chest pain, cough. Tamiflu, Dayquil, Nyquil, Ibuprofen had failed to provide any alleviation in his symptoms. Workup revealed uptrending troponins, ECG w/ ST elevation in his inferolateral leads, systolic left ventricular dysfunction with an ejection fraction of 30%. Chest imaging showing "widespread consolidation in the right upper lobe; areas of cavitation, patchy subsegmental opacities at the periphery of this consolidation".

TREATMENT COURSE

Emergently admitted to the cardiac ICU for myopericarditis with severe sepsis secondary to necrotizing bacterial pneumonia, and started on broad spectrum antibiotics. Patient's troponin levels were trended and eventually peaked at approximately 12. Viral testing notable for Coronavirus and sputum/blood cultures for Strep Pyogenes(GAS). Antibiotics were tailored to Rocephin and patient continued to show improvement. Outpatient follow-up a month later showed improvement to an EF of 60% and return of normal systolic/diastolic function.

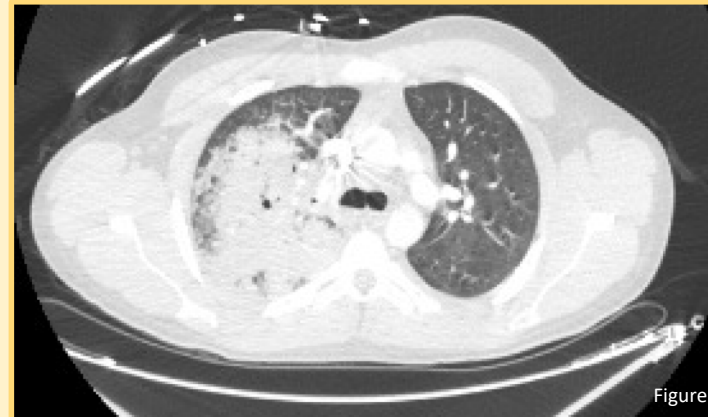

Figure 1

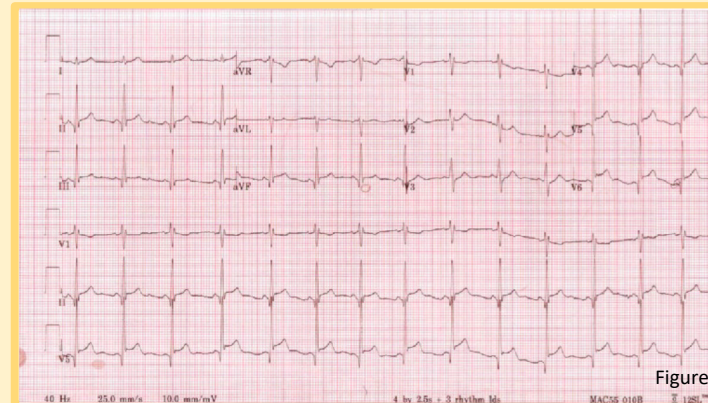


Figure 2

Figure 1. CT imaging demonstrating widespread consolidation in the right upper lobe; areas of cavitation, patchy subsegmental opacities at the periphery of this consolidation

Figure 2. Initial EKG showing ST segment elevations in the inferolateral leads.

DISCUSSION

-While Group A Streptococcus/ Streptococcus Pyogenes is a common cause of pharyngitis and soft tissue infections, it is relatively rare to have GAS infections in the lower respiratory tract. Average annual incidence of S. Pyogenes pneumonia was 1.14 episodes per 100,000 inhabitants.¹ Similarly, myocarditis is also a rare manifestation among COVID-19 patients with recent CDC data from 03/2020-01/2021 showing the risk for myocarditis was 0.146% among patient with COVID-19.²

-GAS bacteremia leading to pneumonia is known to be caused by multiple exotoxins that interact with specific regions of T-lymphocyte receptors to activate massive number of T cells nonspecifically.³ While the exact pathophysiology behind COVID-19 myocarditis remains unclear, research has shown a surge of proinflammatory cytokines plays a major role in myocardial injury.⁴ Although unclear whether GAS or COVID-19 was the primary infection in our patient, the inflammatory cascade from both infections played a synergistic role in worsening our patient's condition that required admission to the cardiac ICU.

-Although limited due to the early supply constraints in the pandemic, this case demonstrates the importance of early testing to detect COVID-19 and increased consideration for testing for overlapping bacterial infections.

REFERENCES

1. Tamayo, E, et al. Streptococcus pyogenes Pneumonia in Adults: Clinical Presentation and Molecular Characterization of Isolates 2006-2015. *PLoS One*. 2016 Mar 30
2. Boehmer, TK, et al. Association Between COVID-19 and Myocarditis Using Hospital-Based Administrative Data-United States, March 2020-January 2021. *MMWR Early Release*. 2021 Aug 31
3. Cunningham, MW. Pathogenesis of group A streptococcal infections. *Clinical Microbiol Rev*. 2000 Jul 13
4. Pirzada, A., et al. COVID-19 and Myocarditis: What do we know so far?. *CJC Open*. 2020 May 28

INTRODUCTION

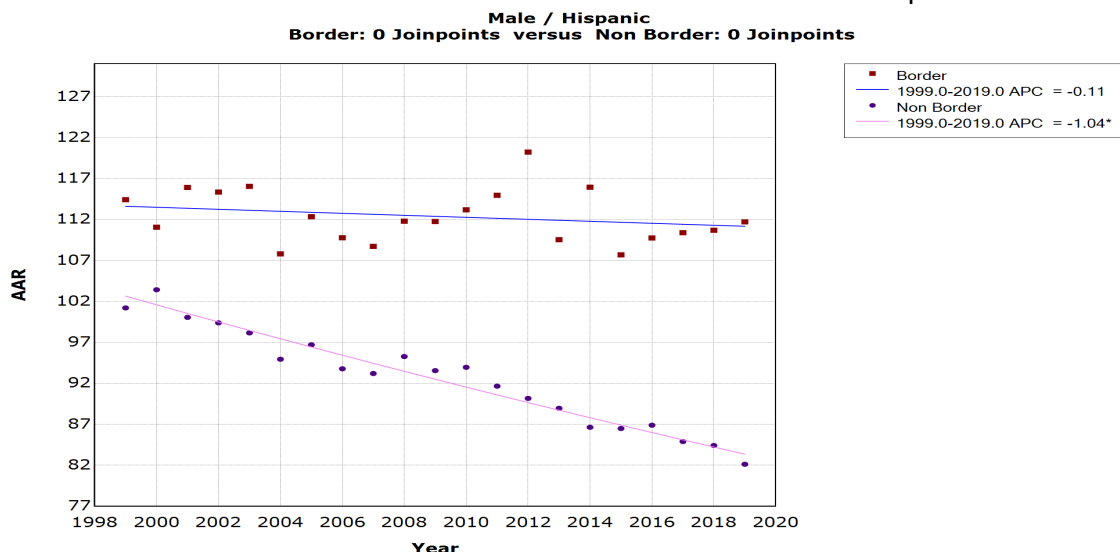
We aimed to identify trends in Gastrointestinal and Liver Disorders/Infections/Cancer (GI) related age-standardized mortality rate (ASMR) for Hispanic and non-Hispanic males in the border region and compared them to Hispanic and non-Hispanic males in the rest of the US (non-border), respectively.

Using mortality data from the CDC WONDER database from January 1, 1999, to December 31, 2019, we analyzed trends in GI-related ASMR. GI-related diagnoses included GI disorders, liver disorders, GI Infections, or GI Cancers, and data was extracted based on ICD-10 codes. We stratified the results by gender and ethnicity and the average annual percentage change (AAPC) in ASMR was estimated using Joinpoint Regression Analysis. Trends in AAPC were compared between the Hispanic and non-Hispanic males between both the regions (US-Mexico Border and non-Border regions). Pairwise comparisons of AAPC were performed and statistical significance was defined if the value was significantly different than zero at alpha = 0.05 level.

METHODS

RESULTS

From 1999 to 2019, the GI-related ASMR of Hispanic males in the Border region has decreased from 114.4 to 111.7 per 100,000 with an AAPC of -0.11 (non-significant with 95% CI -0.3 to 0.1). On the contrary, the same for Hispanic males in non-Border regions has decreased from 101.2 in 1999 to 82.1 per 100,000 in 2019, with an AAPC of -1.04 (significant with 95% CI -1.1 to -0.9). Similarly, from 1999 to 2019, the GI-related ASMR of non-Hispanic males in the Border region has decreased from 84.9 to 74.1 per 100,000, with an AAPC of -0.74 (significant with 95% CI -1.0 to -0.5) and that in the non-Border region from 99.4 to 86.8 per 100,000, with an AAPC of -0.65 (significant with 95% CI -0.7 to -0.6). Pairwise comparison of AAPC showed a significant difference of 0.9 (95% CI 0.7-1.2) between Hispanic males in border and non-border regions (FIGURE).



CONCLUSION

Age-standardized Mortality Rates from GI etiologies have seen a significant reduction over the last two decades in all population groups except Hispanic males on the US side of the US-Mexico Border Regions. Hispanic Males in the US-Mexico border region have the highest GI-related mortality rates and have seen the least reduction over the last two decades.

On the Feasibility of a Telecoaching Program in Illness Conversations: Creating Effective Interprofessional Relationships During COVID-19

Stephen Berns, MD¹, Benjamin Horn, DO, MA²

¹ University of Vermont, Larner College of Medicine
² Rocky Vista University College of Osteopathic Medicine

BACKGROUND

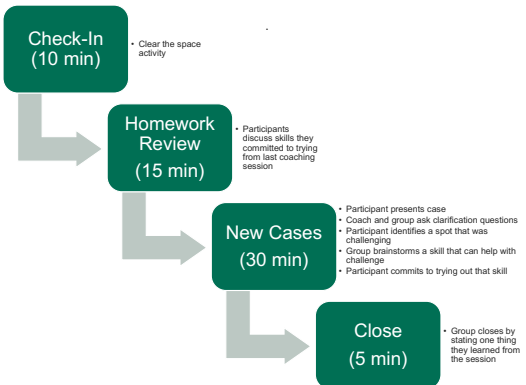
- Several educational interventions to train generalist palliative care skills, particularly in patient-centered communication, have achieved short-term changes in skill improvement after completed workshops.
- Little is known about how to sustain durable change in clinical practice.
- Coaching can provide skill improvement, increase productivity, and increase personal well-being/satisfaction¹⁻³.
- The success of multidisciplinary peer coaching relationships in hospice/palliative care is unknown⁴.
- Rural clinicians in the U.S. have limited access to high quality palliative care specialists.
- Coaching on communication skills may help improve generalist palliative care skills⁵⁻⁷.
- During the era of COVID, the significance of developing and maintaining contact and interpersonal relationships with one another has been a topic of much significance⁸.

EDUCATIONAL INTERVENTION

TalkVermont is a network-wide program for the University of Vermont Health Network with the goal to improve the frequency and quality of serious illness conversations between clinicians and patients through educational workshops.

This coaching project was a feasibility study to see if coaching after a TalkVermont course improves skill confidence and skill use in serious illness conversations. Coaching participants were recruited from TalkVermont graduates. Bimonthly, 1-hour coaching sessions occurred over zoom during a 20-week period from January 2020-May 2020. One expert coach was assigned to a coaching group and utilized educational methods in deliberate practice and coaching to assist participants in identifying learning opportunities. Telecoaching sessions consisted of the following protocol:

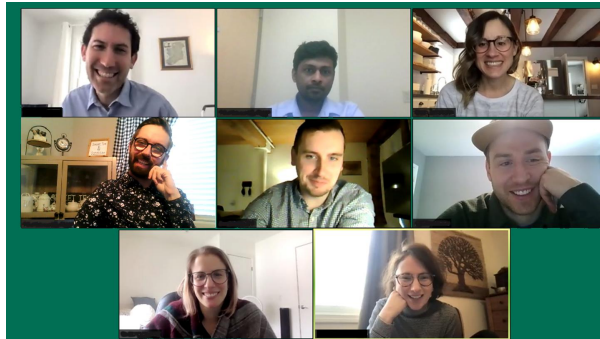Figure 1: Protocol flow scheme



METHODS

Participants before and after each session were asked to complete Pre-call and Post-call surveys to track experiences. This was done synchronously before and after the session started. There were a total of 7 Pre-call and Post-call surveys that each participant was asked to complete during the course of the pilot study.

Image 1: Example of what telecoaching sessions over Zoom look like



RESULTS

- 5 clinicians participated in coaching group (3 physicians, 1 social worker, 1 nurse)

Feasibility of Coaching

- 90% overall attendance rate
- 93% response rate on surveys
- 1 major technological issue that could not be resolved during session (bandwidth issue)
- 2 minor technological issues that could be resolved during session (microphone issues)

Self-Reported Impact on Communication Skills

- All participants reported a 100% increase in goals of care conversations (GOC)
- 2/5 participants had a 200-500% increase in weekly goals of care conversations

Reactions to Coaching

- All participants reported increased job satisfaction because of coaching
- All participants reported they “feel more prepared to navigate these difficult conversations” because of coaching

Table 1: Testimonials from Participants Regarding Pilot Study

“It’s been nice to get to connect with primary care physicians. It will be easier to support one another and understand each other’s roles/language.”
“We were able to use this crisis situation during COVID to regroup and see how we were doing.”
“I don’t think I have had more focused or directed coaching on a specific skill set through all of medical school or all of residency. I wish we could take what we have done and build it into a residency training of other skills.”
“It brought us out of our environments. This is not an easy thing to create a safe space.”

Table 2: Testimonials from Participants Regarding COVID’s Impact

“[My] brain is totally full.”
“I feel powerless in many ways. I am not seeing patients and I feel like I am not making a difference.”
“I need to refocus and reframe in the current pandemic. Take a step back and recognize fear/acknowledge it.”
“There was an ambulance... they then went inside and brought out a stretcher with a loaded body. I was staring out of my house and feeling guilty that I did not know who the person was.”

DISCUSSION

Telecoaching was Feasible

The pilot study was shown to be feasible as most participants were able to attend sessions despite them being in the middle of their workday. There were also few technical issues with microphones, video, or web connection despite being at various locations (home, rural clinical setting, offices).

Telecoaching Promotes Connections

All participants noted that they felt “more connected with one another” throughout the coaching schedule as they moved from a more individual experience towards a collective group mindset. This proved to be even more apparent during the pandemic when the group was feeling isolated from their regular colleagues.

Across Geographical and Clinical Settings

Several tele-mentoring programs in which specialists train healthcare workers to treat medical conditions, especially those in rural or underserved populations, have been shown to improve clinician preparedness and confidence¹⁰. This telecoaching program had similar results, improving preparedness in serious illness communication skills as well as job satisfaction.

Across Disciplines

Interprofessional identity plays a strong role in the connections among ourselves within healthcare¹¹. Telecoaching provided a platform for participants to safely share disciplinary perspectives on challenging cases. Participants commented that sharing perspectives lead to better understanding of each other’s roles.

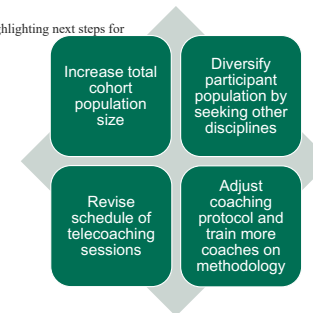
Telecoaching Helped to Process COVID

All participants noted COVID-19 greatly impacted them emotionally, mentally, and physically (Table 2). Despite that, participants noted the coaching group provided a platform to process the pandemic. Narrative sharing has been shown as an effective means for healing and building relationships during traumatic events⁹.

CONCLUSIONS AND NEXT STEPS

Group telecoaching is feasible and valuable for skill consolidation in serious illness communication. It also can build strong interpersonal relationships across professions and distances, particularly during moments of stress. Limitations of our results include low number of participants, self-reported data, response rate linked to session attendance, as well as the impact that COVID played in attendance.

Figure 2: Diagram highlighting next steps for research



REFERENCES

1. Lovell, B., *What do we know about coaching in medical education?* J. Internist. 2016; 324(4): 778-780.
2. Yeh, S., et al., *Coaching in medical education: A systematic review of the literature*. J. Gen. Intern. Med. 2017; 32(9): 1224-30.
3. Ho, Y. Y., et al., *Implementing Coaching from Teaching First: Telecoaching Coaching*. JAMA Surg. 2017; 152(6): 718-725.
4. Robinson, R., *Coaching in medical education: A systematic review of the literature*. J. Gen. Intern. Med. 2017; 32(9): 1224-30.
5. Poth, M., et al., *Coaching in medical education: A systematic review of the literature*. J. Gen. Intern. Med. 2017; 32(9): 1224-30.
6. Poth, M., et al., *Coaching in medical education: A systematic review of the literature*. J. Gen. Intern. Med. 2017; 32(9): 1224-30.
7. Poth, M., et al., *Coaching in medical education: A systematic review of the literature*. J. Gen. Intern. Med. 2017; 32(9): 1224-30.
8. Poth, M., et al., *Coaching in medical education: A systematic review of the literature*. J. Gen. Intern. Med. 2017; 32(9): 1224-30.
9. Poth, M., et al., *Coaching in medical education: A systematic review of the literature*. J. Gen. Intern. Med. 2017; 32(9): 1224-30.
10. Poth, M., et al., *Coaching in medical education: A systematic review of the literature*. J. Gen. Intern. Med. 2017; 32(9): 1224-30.
11. Poth, M., et al., *Coaching in medical education: A systematic review of the literature*. J. Gen. Intern. Med. 2017; 32(9): 1224-30.



Baton Rouge General

Internal Medicine Residency Program

Polycystic Kidney Disease, Beyond The Surface

Yara Mouawad MD, Ifeoluwa Stowe MD, Samuel Jones MD

Baton Rouge General Medical Center, Baton Rouge, Louisiana

Introduction

- Autosomal Dominant Polycystic Kidney Disease (ADPKD) is a subtype of primary renal ciliopathies
- Tolvaptan has been shown to reduce the decline in kidney function in ADPKD patients at high risk of disease progression.
- In addition to possible adverse effects, including fatal liver injury, the cost burden of Tolvaptan is a major factor limiting its use.
- It is therefore crucial to confirm the correct diagnosis and indication before initiating treatment.

Case Description

- A 30-year-old male with history of hypertension and seizures was referred for evaluation of gross hematuria and renal cysts.
- He reported childhood onset decreased hearing loss and a history of headaches and seizures.
- Family history was positive for polycystic kidney disease and a prior CT scan with contrast had revealed multiple bilateral renal cysts.
- His physical exam was unremarkable with the exception of grade II hypertensive changes on fundoscopic examination.
- He was suspected to have ADPKD based on the above and was started on Losartan.
- An MRI was obtained to better characterize renal volume (Right Kidney 173 cc, Left Kidney 321 cc).
- Using the Mayo Clinic imaging classification, his risk of progression to ESRD in 10 years was calculated to be 11%; therefore, treatment with Tolvaptan to slow disease progression was considered.

Investigations

MRI abdomen

Several small cysts in the right kidney measuring up to 1.5 cm. 2 large cysts at the upper pole of the left kidney measuring 4.7 cm and 5.0 cm in greatest dimensions with thin septations but no solid components. Other subcentimetric cysts in the left kidney. No solid renal mass. No hydronephrosis. Right renal measurements are 10.4 x 5.5 x 5.8 cm (volume =173) Left renal measurements are 12.6 x 8.4 x 5.8 cm (volume=321)

Results for ADPKD Prognostic Tool using Total Kidney Volume

Height Adjusted Total Kidney Volume (HtTKV): 281.9 mL/m

Mayo Clinic Class : 1B

Risk of Renal Progression: **Intermediate risk**

Estimated Frequency of ESRD at 10 years (from study cohort): 11%

Answers calculated to formulate result:

- Does this patient have typical morphology of ADPKD (diffuse, bilateral cystic involvement)? — Yes
- Total Kidney Volume, both kidneys (TKV) — 494 ml
- Patient Height — 69 inches
- Age at time of imaging — 30 Years

Natera Renasight™ Result Summary

NEGATIVE

This test is negative for known renal disease causing variants. See below for additional findings of potential clinical relevance

Gene	Condition(s)	Inheritance	Zygosity	Classification
NPHS2	Congenital nephrotic syndrome, Type 2	Autosomal Recessive	Heterozygous	Likely Pathogenic
IFT140	Retinitis Pigmentosa 80, Short-Rib Thoracic Dysplasia 9	Autosomal Recessive	Heterozygous	Likely Pathogenic

Discussion

- Prior to initiating treatment in this patient, genetic profiling was obtained which was negative for variants for ADPKD including PKD1, PKD2 and PKHD1, however it found likely pathogenic heterozygous variants of the genes NPHS2 and IFT140.
- Both genes are inherited in an autosomal recessive manner. IFT140 mutations have been implicated in another subset of cystic kidney disease called nephronophthisis (NPHP).
- The patient expressed the disease despite having heterozygous variants which can be explained by oligogenicity.
- Another plausible explanation is the presence of hypomorphic alleles. These may result from missense mutations leading to reduced expression of the gene and manifestation of the disease later in life.

Conclusions

- This case illustrates the importance of differentiating ADPKD from other cystic kidney diseases using next generation whole genome sequencing.
- Not only does it affect treatment options, misdiagnosing can also lead to missing important disease associations including retinal, hepatic and CNS involvement.
- In patients with cystic kidney disease, it is important to perform genetic profiling to confirm the definitive diagnosis as this can influence treatment options.

References

- Focsa, I., Budășteanu, M., & Bălgrădean, M. (2021). Clinical and genetic heterogeneity of Primary Ciliopathies (review). *International Journal of Molecular Medicine* 48(5). <https://doi.org/10.3892/ijmm.2021.5009>
- Wolf, M. T. F. (2015). Nephronophthisis and related syndromes. *Current Opinion in Pediatrics* 27(2), 201-211. <https://doi.org/10.1097/mop.0000000000000194>
- Irazabal M. V., Rangel, L. J., Bergstralh E. J., Osborn, S. L., Harmon, A. J., Sundsbak J. L., Bae, K. T., Chapman, A. B., Grantham, J. J., Mrug, M., Hogan, M. C., El-Zoghby Z. M., Harris, P. C., Erickson, B. J., King, B. F., & Torres, V. E. (2014). Imaging classification of autosomal dominant polycystic kidney disease: A simple model for selecting patients for clinical trials. *Journal of the American Society of Nephrology*, 26(1), 160-172. <https://doi.org/10.1681/asn.2013101138>

Disseminated blastomycosis mimicking lymphoma in new onset HIV disease

Allyson Larcena, MD; Pavana Sakhamuri, MD; Saifullah Shahid, MD; Benjamin Pickard, MD;
Tammar Williams, MD; Nicholas R. Sells, MD; Karen Curry, MD
Louisiana State University Health Sciences Center at Ochsner University Hospital & Clinics
Department of Internal Medicine- Lafayette, LA

Introduction

Blastomycosis is a fungal infection caused by the Blastomycosis species endemic to North America, particularly in states surrounding the Mississippi, Ohio, and St. Lawrence rivers, and the Great Lakes. Although most commonly a pulmonary infection, extrapulmonary disease can occur via hematogenous dissemination, and can involve any other organ, including the lymph nodes. In immunocompromised hosts, the disease tends to be more severe, with a higher mortality when compared to immunocompetent patients. We report a case of disseminated blastomycosis in a previously untreated human immunodeficiency virus (HIV) patient.

Case Description

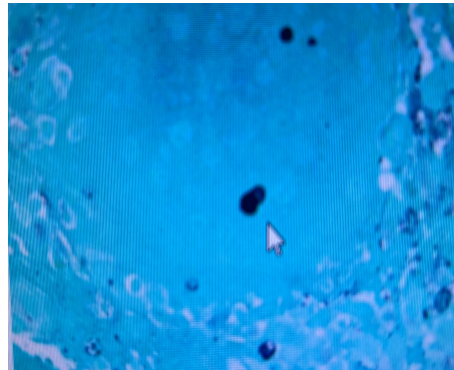
The patient is a 58-year-old Hispanic male with no reported past medical history who presented with a 3-month history of worsening lower abdominal pain, nausea, and vomiting. He reported unintentional weight loss of approximately 20 pounds over 3 months. He reported having immigrated from Venezuela about 7 months prior. He denied any fever, chills, exposure to TB, or recent travel.

On arrival, he was tachycardic with tenderness to palpation throughout the lower abdominal quadrants. Initial laboratory work revealed pancytopenia. Computed tomography of thorax, abdomen, and pelvis revealed bilateral pulmonary nodules, extensive lower mediastinal, mesenteric, and retroperitoneal lymphadenopathy. Findings were suspicious for a metastatic versus lymphomatous process. Further workup revealed a positive HIV fourth-generation test with a CD4 count of 94, CD4 percentage of 14, and viral load of 968,000. Patient also had positive Fungitell and Blastomyces urine antigen. Interventional radiology performed a lymph node biopsy, and histopathology revealed granulomatous inflammation. A silver stain was positive for broad-based budding yeast, consistent with Blastomyces. The patient was initiated on liposomal amphotericin B for two weeks followed by oral itraconazole for 12 months with gradual improvement in his symptoms.

Lab Results

Lab	Result
HIV	Reactive
HIV 1 Ab-LC	Positive
HIV1 RNA PCR-LC	968,000
Log10 HIV-1 RNA- LC	5.986
Fungitell	218
Blastomyces Ag Urine LC	Positive

Silver Stain



Conclusion

- The causative organism of blastomycosis, usually *B. dermatidis*, has an extensive geographic distribution.
- It is co-endemic with, although occurring less frequently than, histoplasmosis in the Ohio and Mississippi areas.
- This infection can disseminate to any organ in the body. It has a wide range of clinical manifestations, including subclinical infection, acute or chronic pneumonia, and acute respiratory distress syndrome.
- When it compromises both the lungs and central nervous system (CNS), it can mimic other entities, such as nocardiosis, cryptococcosis, and tuberculosis.
- Culture of *Blastomyces* leads to a definitive diagnosis; however, characteristic broad-based budding yeast forms with a doubly refractile cell wall visualized on clinical specimens stained with 10% potassium hydroxide, calcofluor white, periodic acid-Schiff, or Gomori methenamine silver can provide a presumptive diagnosis.
- For patients who live in endemic areas, blastomycosis must be recognized as an opportunistic infection in patients with advanced HIV disease.

References

McBride JA, Gauthier GM, Klein BS. Clinical manifestations and treatment of blastomycosis. Clin Chest Med 2017; 38:435–49.

Introduction

- Endometriosis is one of the most common chronic inflammatory conditions known, affecting 6-10% of all women¹.
- While it may be asymptomatic, symptoms and pathology are most commonly limited to the pelvis and its associated structures¹.
- In rare cases endometrial tissue can be found within the thoracic cavity and is known as thoracic endometriosis syndrome (TES)
- TES manifests typically on the right side in a number of ways primarily as pneumothorax, hemoptysis, or hemothorax if pleural or parenchymal involvement is significant.
- We discuss the case of a 45 year old female who presented with chronic right sided pleural effusion and shortness of breath

Review of Literature

There are several theories of the pathogenesis of endometriosis^{2,3,4}:

- Retrograde menstruation theory, or Sampson's theory postulates that retrograde movement of menstrual endometrium would resultantly auto-transplant endometrial tissue into the peritoneal and possibly thoracic cavity (suspected through defects in the diaphragm). endometrial tissue/cells into the peritoneal and thoracic cavities
- Lymphatic and hematogenous dissemination theory suggests metastatic spread of endometrial tissue aided by the lymphatic and vascular systems to the pulmonary circulation.
- Coelomic metaplasia theory is based on the idea that endometriosis develops via metaplasia of mesothelial cells of pleural and peritoneal surfaces
- A final theory known as the prostaglandin theory focuses on PGF2a which results in vasoconstriction mediated rupture of pulmonary alveoli and subpleural bulla. This theory is linked strongly to the explanation of TES.

Case Presentation

- A 45 year old lady with a history of deep vein thrombosis, pulmonary embolism, endometriosis, and iron deficiency anemia presented to the emergency room with worsening, severe right medial back pain for 2 months.
- She had a history of endometriosis identified in 2016 and with thoracic involvement leading to right sided pneumothorax treated with a chest tube. She had been managed with total abdominal hysterectomy 1/26/2021. Since then, she has had no recurrence.
- Vitals on presentation were notable for tachycardia and tachypnea and a chest radiograph in the emergency department showed an opacity involving the right hemithorax.
- Computer tomography and angiography was performed to better characterize the lesion of the chest. Imaging revealed a loculated pleural effusion on the right with acute bilateral pulmonary emboli (figures A,B).
- Laboratory results showed an decrease in hemoglobin down to 6.8. The patient's anticoagulant was held and a thoracentesis was performed. Results of fluid analysis is shown in Table 1.
- Following removal of approximately 300 ml of chocolate colored fluid (figure C), the patient's repeat chest radiograph showed minimal improvement.
- she subsequently underwent a thoracoscopy which demonstrated lung entrapment.
- She was referred to thoracic surgery and successfully underwent video assisted thoracic lung decortication.
- Despite intervention, post operatively she developed restrictive lung disease requiring oxygen and required significant pulmonary rehabilitation prior to being able to wean off of continuous oxygen.

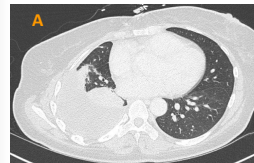


Figure A (top left). Transverse CTA of the chest demonstrating a large right sided effusion with associated atelectasis.

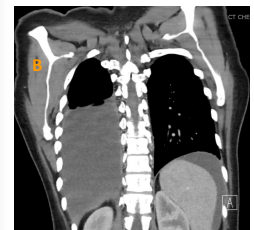


Figure B (bottom left). Coronal CTA of the chest demonstrating a large right sided effusion with associated atelectasis.

Color	Brown
LDH	6952 U/L
Protein	7.2 g/dL
Glucose	7 mg/dL
WBC	188,870/cu mm (86% PMN, 14% monocytes)

Table 1 (above). Pleural fluid analysis following thoracentesis.

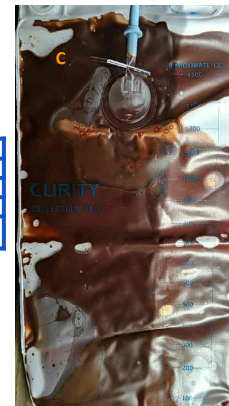


Figure C (right). Pleural fluid following thoracentesis. Procedure was stopped after 300 mL was removed due to development of pain suggestive of entrapment.

Discussion

- Current treatments for TES are similar to treating pelvic disease with goals of suppressing ovarian hormone production.
- Gonadotropin releasing hormone analogues can be used as first line treatments with aims to reduce activation of the pituitary-ovarian hormone pathways⁵.
- Oral contraceptives, aromatase inhibitors, and progestins are other effective therapies to reduce recurrence and decrease symptoms of extra-pelvic endometriosis⁵.
- VATS and multidisciplinary surgical management is used for severe and recurrent symptoms as a result of extra-pelvic endometriosis⁶.

Conclusions

- Here we present a patient with chronic hemothorax associated with lung entrapment secondary to thoracic endometriosis.
- In patients with thoracic endometriosis, pneumothorax and hemothorax are treated with drainage and prevention of recurrence.
- Pulmonary nodules may be treated with excision. Medical therapy is aimed at limiting symptoms and complications.

References

- Pmid 29420391 Clinical Management of Endometriosis
- Vinater D, Orazi G, Cosson M, Dufour P. Theories of endometriosis. Eur J Obstet Gynecol Reprod Biol 2001; 96:21.
- Marshall MB, Ahmed Z, Kucharczuk JC, Kaiser LR, Shrager JB. Catamenial pneumothorax: Optimal hormonal and surgical management. Eur J Cardiothorac Surg. 2005;27:662-666.
- Channabasavaiah AD, Joseph JV. Thoracic endometriosis: revisiting the association between clinical presentation and thoracic pathology based on thoracoscopic findings in 110 patients. Medicine (Baltimore) 2010; 89:183.
- Alifano M, Jablonski C, Kadiri H, et al. Catamenial and noncatamenial, endometriosis-related or nonendometriosis-related pneumothorax referred for surgery. Am J Respir Crit Care Med 2007; 176:1048.
- Hatz RA, Kaps MF, Meimarakis G, Loehe F, Muller C, Furst H. Long-term results after video-assisted thoracoscopic surgery for first-time and recurrent spontaneous pneumothorax. Ann Thorac Surg. 2000;70:253-257.

A Case Report of Neuro Sarcoidosis

Pavana Sakhamuri, MD; Tristan Dao, MD;

Mekha Matthew, DO; Ann Chauffe, DO

Louisiana State University Health Sciences Center at Ochsner University Hospital & Clinics

Department of Internal Medicine- Lafayette, LA

Introduction

- Neuro sarcoidosis is a diagnostic consideration in patients with a diagnosis of sarcoidosis who develop neurological complaints.
- Neurological complications are seen in only 5-10% of patients with established diagnosis of sarcoidosis.
- Generally neuro sarcoidosis responds well to high-dose glucocorticoids in the majority of patients, but relapse is common.

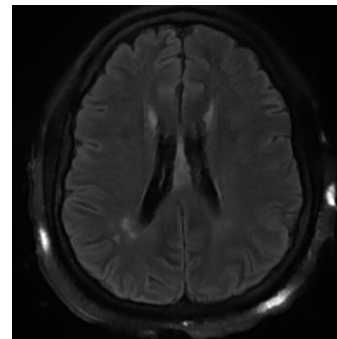
Case Description

- A 31-year-old male presented with chief complaints of double vision and binocular diplopia for 1 day. He also reported that his left eye was pulled inwards 1 day prior.
- He denied any headaches, dizziness, lightheadedness, balance issues, and had no other cranial nerve or motor/sensory deficits.
- The patient was seen in pulmonology clinic a few months prior for ongoing worsening SOB with nonproductive cough for over 2 years. Ct Thorax revealed bilateral hilar opacification with scattered nodules throughout the lungs.
- An extensive autoimmune/infectious work-up along with a bronchoscopy and subsequent biopsy revealed chronic granulomatous inflammation suggestive of pulmonary sarcoidosis.

Case Description cont.

- He was prescribed prednisone 40 mg; however, the prescription was never filled.
- In the background of pulmonary sarcoid his new symptoms of binocular diplopia with left lateral rectus palsy was concerning for neuro-sarcoid prompting an MRI of the brain.
- MRI results revealed multifocal enhancing cerebral cortex nodules, scattered leptomeningeal, optic chiasm distal optic nerve enhancement along with chronic appearing non-enhancing T2 hyperintense foci of cerebellar white matter consistent with neuro sarcoid.
- Neurology and Rheumatology recommended pulse dose steroids followed by a slow steroid taper with plans to start on biologic DMARDs in the outpatient setting. His symptoms slowly but steadily improved.

Imaging



MRI Brain revealing contrast enhancing lesions

Conclusion

- Neuro sarcoidosis is a noncaseating granulomatous disease of unknown etiology that can involve central, peripheral and autonomic nervous system.
- It's fairly uncommon with manifestation of sarcoidosis with <10% patients developing neurologic involvement.
- Neurological features usually develop within 2 years of diagnosis and can range from mono/polyneuropathies to paraparesis/milieu of multiple neuro symptoms.
- Histological analysis of tissue provides definite diagnosis, however lab or radiological support in the right clinical setting is sufficient.
- Corticosteroids are still the main stay of treatment for neuro-sarcoidosis with duration varying with severity of disease.
- Immunomodulators can be considered in addition to steroids in cases of severe/uncontrolled disease or can be used by themselves when steroids are not an option due to intolerance /side effects.

References

Bathla G, Singh AK, Policeni B, Agarwal A, Case B. Imaging of neurosarcoidosis: common, uncommon, and rare. Clin Radiol. 2016; 71:96–106.

Tavee JO, Stern BJ. Neurosarcoidosis. Clin Chest Med. 2015;36: 643–56.



Baton Rouge General

Internal Medicine Residency Program

Spontaneous Bilateral Progressive Intracranial Carotid and Vertebral Arterial Dissection

Associated with Intractable Vomiting

Gift Echefu MD, Rameela Mahat MD, Andikan Udoh MD, Raju Vatsavai MD

Baton Rouge General Internal Medicine Residency Program, affiliate of Tulane University School of Medicine



Baton Rouge General

Internal Medicine Residency Program

Introduction

- ❖ Spontaneous craniocervical (referring to carotid and vertebral arteries) arterial dissections (sCAD) are rare but potentially fatal conditions to be considered in young and middle-aged patients presenting with new neurological deficits.
- ❖ Cases of spontaneous dissections in individuals with normal carotids have been reported after minor trauma and may involve the carotid or vertebral vessels, either unilaterally or bilaterally.
- ❖ Cases of spontaneous bilateral carotid and vertebral artery dissections occurring simultaneously are extremely rare.

Case presentation

- ❖ A 49-year-old woman with past medical history of depression, insomnia, and chronic lower back pain, presented with sudden onset aphasia, right upper extremity numbness, headache and neck pain that began a day prior to presentation.
- ❖ She reported a recent viral infection manifesting with upper respiratory symptoms, associated with multiple episodes of violent vomiting and diarrhea 4 days prior to presentation. She denied any history of trauma or neck manipulation.
- ❖ Head MRI revealed multiple bi-hemispheric embolic infarcts, predominantly affecting the left frontal, parietal lobes, and right internal capsule.
- ❖ There was initial suspicion for septic or cardioembolic phenomena given the presence of infectious process preceding the neurological deficits and MRI revealing embolic infarcts. Therefore, transthoracic echocardiogram followed by transesophageal echocardiogram were obtained but were unremarkable for endocarditis or PFO.
- ❖ Workup for other etiologies of stroke including vasculitis, coagulopathy, connective tissue disease, toxins such as drugs, hypercholesterolemia and thyroid dysfunction were normal.
- ❖ CT angiogram of the head obtained on hospital day 2 revealed bilateral internal carotid artery dissection and pseudoaneurysm with high grade stenosis and near total occlusion of the distal internal carotids bilaterally.
- ❖ Vascular and neurological surgeons were consulted and she was initiated on anticoagulation with Apixaban.
- ❖ She made significant improvement in her neurological deficits with aggressive physical therapy and was discharged 4 days later to continue outpatient therapy.
- ❖ However, she returned the next day with intractable emesis, worsening motor aphasia, new right upper extremity weakness.
- ❖ Repeat MRA head and neck revealed progression of intimal dissection with slight interval progression of stenosis and irregularity of the ascending cervical internal carotid arteries bilaterally.

Case presentation

- ❖ There were new foci of grade 1 vascular injury involving the V2 segment of the bilateral vertebral arteries not present on imaging during previous admission.
- ❖ Vascular surgery was consulted and patient was transferred to a comprehensive stroke center for evaluation for endovascular intervention. She was observed at the center on Apixaban and continued to clinically improve with no intervention required. Aspirin and plavix were initiated at discharge.
- ❖ At 9 months follow up visit, repeat CTA head and neck revealed resolution of dissections. She also had complete resolution of right upper extremity weakness and mild residual dysarthria.

Figures

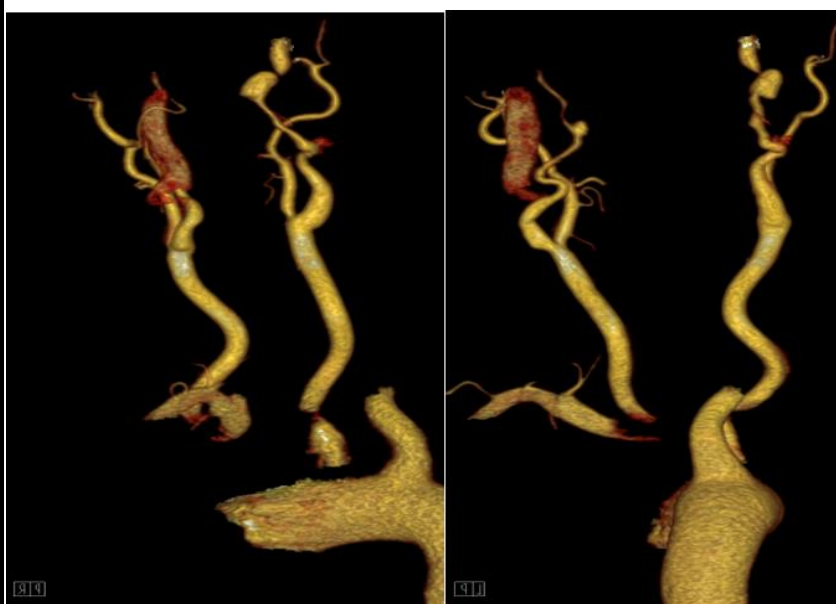


Figure 1 CTA of the brain showing dissection of ICA and pseudoaneurysm

Discussion

- ❖ Presentation may range from benign symptoms such as unilateral headache or neck pain in upto 57-90% of cases to transient ischemic attack or stroke.
- ❖ Conditions such as vasculitis or connective tissue disorders including Ehlers-Danlos syndrome, Marfan syndrome, fibromuscular dysplasia, especially in women confer increased risk of sCAD due to intrinsic vascular structure abnormality.
- ❖ Isolated cases of sCAD usually, unilateral, in individuals with normal carotids have been reported after trivial activities like cough, chiropractic manipulation, yoga, sneezing, receiving anesthesia, following resuscitative measures and non-contact sports.
- ❖ Neck hyperextension or rotation with resultant Injury to the artery from mechanical stretching during these abrupt neck movements.
- ❖ Acute infection has been reported as an independent risk factor in the pathogenesis of sCAD. The proposed mechanisms are indirect inflammation, cytokine and protease induced extracellular matrix degradation of the vessel wall, prothrombotic, oxidative and autoimmune mechanisms.
- ❖ We believe that the mechanical factor induced by violent vomiting in the setting of viral infection may have caused increased stretching of the vessels predisposing to the dissections.
- ❖ Ultrasound, CTA or MRI of the brain with MRA are imaging modalities of choice to establish the diagnosis
- ❖ Expansion and early recurrence of dissection impact morbidity and mortality and occur at a higher rate within the first few days to 1 month. Our patient had progression of the bilateral carotids and new bilateral vertebral artery dissection due to unrelenting violent vomiting and returned 24 hours following initial discharge.
- ❖ Antithrombotic therapy is the management of choice in sCAD. Studies have found no significant difference in the outcomes following management of stroke from CAD with antiplatelet therapy compared with anticoagulation.
- ❖ Endovascular interventional therapy, angioplasty or stenting, is reserved for patients with contraindication to antithrombotic therapy, progressive, profound ischemic symptoms, expanding pseudoaneurysm or hemodynamic instability.

References

- Engelter ST, Tmenka C, Gensicke H, et al. Aspirin versus anticoagulation in cervical artery dissection (TREAT-CAD): an open-label, randomised, non-inferiority trial. *Lancet Neurol.* 2021;20(5):341-350
- Flis CM, Jäger HR, Sidhu PS. Carotid and vertebral artery dissections: clinical aspects, imaging features and endovascular treatment. *Eur Radiol.* Mar 2007;17(3):820-34.
- Lee VH, Brown RD, Mandrekar JN, Mokri B. Incidence and outcome of cervical artery dissection: a population-based study. *Neurology.* Nov 28 2006;67(10):1809-12.
- Guillon B, Berthet K, Benslamia L, Bertrand M, Bousser MG, Tzourio C. Infection and the risk of spontaneous cervical artery dissection: a case-control study. *Stroke.* Jul 2003;34(7):70-81

Coronavirus Disease 2019 Associated Acute Kidney Injury Risk Factors and Outcomes

Alissa Ice, MD¹, Matthew Foy, MD¹, Diana Hamer, PhD^{1,2}, L. Mark Laperouse, Jr., MD², Catherine S. O'Neal, MD^{1,2}, Christopher B. Thomas, MD^{1,2}, Hollis R. O'Neal Jr., MD, MSc^{1,2}

¹Louisiana State University Health Sciences Center, Baton Rouge, LA, ²Our Lady of the Lake Regional Medical Center, Baton Rouge, LA

Introduction

Severe Acute Respiratory Syndrome Coronavirus 2 (SARS-CoV-2) infection is frequently complicated by acute kidney injury (AKI), a poor prognostic indicator, with incidence, risk factors, and outcomes variably described in the literature. We aimed to assess clinical characteristics and outcomes of patients with SARS-CoV-2 infection complicated by AKI.

Methods

- **Design:** single center, retrospective cohort study at a large academic medical center in Baton Rouge, Louisiana, USA early during the Coronavirus Disease 2019 (COVID-19) pandemic.
- **Inclusion Criteria:** adults diagnosed with COVID-19 after presenting to the emergency department with respiratory symptoms and labs drawn within 4.5 hours of initial vitals between April 7-April 28, 2020, three weeks after the first confirmed case in the city.
- **Exclusion Criteria:** end stage renal disease patients were excluded from the study.
- **AKI Definition:** according to Kidney Disease Improving Global Outcomes (KDIGO) criteria, although urine output was not included due to concerns regarding the reliability.

Primary Outcome	AKI
Secondary Outcomes	Clinical Characteristics In-hospital Mortality Hospital Admission ICU Admission ICU Length of Stay (LOS) AKI Stage Renal Replacement Therapy (RRT) Renal Recovery

Results

Table 1: Baseline Characteristics and Clinical Outcomes of Patients with COVID-19

Characteristic	All Patients (n=89)	AKI (n=46)	Non-AKI (n=43)	p-Value
Demographics				
Age, years, median (Q1-Q3)	65 (51.5-75)	68.5 (59-75)	54 (42-73)	0.003*
Male	47 (52.8)	30 (65.2)	17 (39.5)	0.020*
Race/Ethnicity				
White	30 (33.7)	15 (32.6)	15 (34.9)	0.963
Black	51 (57.3)	27 (58.7)	24 (55.8)	0.963
Other	8 (9.0)	4 (8.7)	4 (9.3)	0.963
Comorbidities				
Any	83 (93.3)	44 (96.7)	39 (90.7)	0.424
Hypertension	63 (70.8)	38 (82.6)	25 (58.1)	0.019*
Diabetes	34 (38.2)	22 (47.8)	12 (27.9)	0.080
Obesity (BMI≥30kg/m ²)	39 (43.8)	17 (37.0)	22 (51.2)	0.177
Dyslipidemia	33 (37.1)	20 (43.5)	13 (30.2)	0.272
Heart Failure	17 (19.1)	14 (30.4)	3 (7.0)	0.006*
Chronic Kidney Disease	14 (15.7)	10 (21.7)	4 (9.3)	0.147
Coronary Artery Disease	17 (19.1)	11 (23.9)	6 (14.0)	0.286
Chronic Obstructive Lung Disease	9 (10.1)	7 (15.2)	2 (4.7)	0.147
Outcomes				
Hospital Admission	74 (83.1)	44 (95.7)	30 (69.8)	0.001*
ICU Admission	29 (32.6)	24 (52.2)	5 (11.6)	<0.001*
ICU Length of Stay, days, median (Q1-Q3)	7 (2-13)	9.5 (5.3-13.8)	2 (1.5-3)	<0.001*
In-hospital Mortality	20 (22.5)	20 (43.5)	0 (0)	<0.001*

- A total of 89 patients with COVID-19 were included in our study, and 51.7% of patients developed AKI during admission.
- Patients who developed AKI were more likely to be male, older, and have heart failure or hypertension compared to those who did not.
- Patients who developed AKI had higher hospital admission rates and were more likely to be admitted to the ICU with longer ICU LOS compared to those in the non-AKI group.
- Notably, in-hospital death occurred only in the AKI cohort.
- Of patients with AKI who were discharged alive, 65.4% had renal recovery at the time of discharge; nine patients did not have renal recovery at the time of discharge. Of these nine, six had repeat labs done within one month post hospitalization, and five demonstrated subsequent recovery.

Table 2: Characteristics of Patients with AKI

Characteristic	AKI (n=46)
AKI at the Time of Presentation	38 (82.6)
Mean Time to AKI, days (SD)	1.52 (3.65)
Peak AKI Stage	
Stage 1	22 (47.8)
Stage 2	15 (32.6)
Stage 3	9 (19.6)
Renal Replacement Therapy	4 (8.7)
In-hospital Mortality	20 (43.5)
Renal Recovery at Discharge	17 (37.0)

Conclusion

Early in the COVID-19 pandemic, before natural or vaccine-induced immunity and current proven beneficial therapies, we found older age, male sex, hypertension, and heart failure to be associated with AKI. These risk factors have also been noted in the literature. Chronic kidney disease, coronary artery disease, diabetes, and black race were not found to reach significance in this study. Though the majority of patients who survived to discharge demonstrated renal recovery, AKI was associated with high in-hospital mortality and is common amongst patients with COVID-19.

References

1. Chan, L., et al. (2021). "AKI in Hospitalized Patients with COVID-19." J Am Soc Nephrol 32(1): 151-160.
2. Fisher, M., et al. (2020). "AKI in Hospitalized Patients with and without COVID-19: A Comparison Study." J Am Soc Nephrol 31(9): 2145-2157.
3. Hansrivijit, P., et al. (2021). "Risk Factors, Clinical Characteristics, and Prognosis of Acute Kidney Injury in Hospitalized COVID-19 Patients: A Retrospective Cohort Study." Medicines (Basel) 8(1).
4. Hirsch, J. S., et al. (2020). "Acute kidney injury in patients hospitalized with COVID-19." Kidney Int 98(1):209-218.
5. Khwaja, A. (2012). "KDIGO clinical practice guidelines for acute kidney injury." Nephron Clin Pract 120(4): c179-184.

Masquerading as TTP: An Insidious Presentation of B12 Deficiency

Zoya Mohammad MD MPH, Mohammad Nour Salloum MD

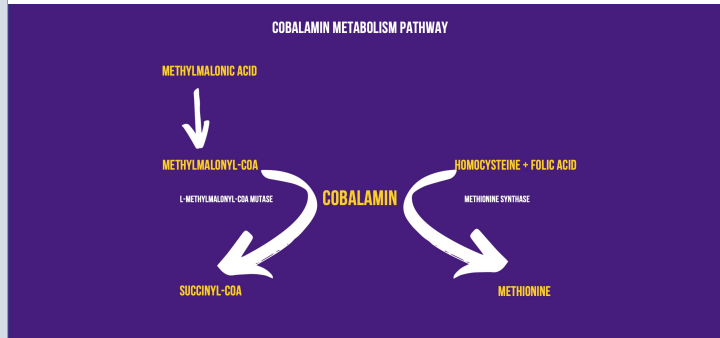
Louisiana State University School of Medicine, Dept. of Internal Medicine, Shreveport, LA

Background

- Pseudothrombotic microangiopathy is a rare presentation of B12 (cobalamin) deficiency.
- Patients appear severely ill in the setting of elevated reticulocyte count and LDH, low haptoglobin, increased total bilirubin, low platelet count, and anemia - deceptively suggestive of thrombotic thrombocytopenic purpura (TTP), a type of true microangiopathic hemolytic anemia.
- TTP requires prompt and intense treatment as it can be life threatening, whereas B12 deficiency simply requires B12 replacement.

Objective

- We present a case of B12 deficiency mimicking microangiopathic hemolytic anemia.



Case Description

- A 36 year old Black American female with a history of hypothyroidism presented for symptomatic anemia with hemoglobin of 5.1 g/dL and symptoms of lightheadedness, fatigue, shortness of breath, palpitations, sweats, chills, nausea and vomiting for the past 1 month diagnosed at an outside facility. She also had hair loss, cold intolerance, 54 lb weight loss, easy bruising and tingling in her fingertips and toes.
- Exam was largely unremarkable other than pallor.
- She was found to have an LDH >4,000, haptoglobin <4, platelets as low as 13K, and peripheral smears showing hypersegmented neutrophils, schistocytes and tear drop cells. B12 levels are normal (295 pg/mL) and methylmalonic acid (MMA) is 1.56 $\mu\text{mol}/\text{mmol}$. Thyroid function panel was near normal.
- With fear that this was TTP, she received high dose IV steroids and 3 days of plasma exchange with minimal improvement in platelets or symptoms, but with hopes that it would improve. Shockingly, ADAMTS13 is found to be negative.
- Hematology now suggests this to be an insidious presentation of B12 deficiency and daily B12 injections were started. Her symptoms improve within days. Patient is discharged with weekly injections thereafter and intrinsic factor (IF) antibody is found to be positive after she has left and pernicious anemia is uncovered.

Discussion

- Cobalamin is necessary for DNA synthesis, but humans cannot synthesize it. It is taken in through diet. Dietary deficiency is typically uncommon as our body can store 5-10 years worth. Rather, malabsorption is oftentimes the culprit of deficiency.
- B12 is more available for absorption in an acidic environment and most of the absorbed form is done by binding to IF produced by gastric parietal cells, which enhances absorption of B12 in the terminal ileum.
- Pernicious, or autoimmune, anemia causes malabsorption by ways of antibodies that impede the B12-IF complex - either targeted at gastric parietal cells or to IF itself.
- In severe cases as such, it can present with neuropathy, generalized weakness and tissue hypoxia symptoms such as shortness of breath in the setting of elevated LDH, reticulocyte count, total bilirubin with low haptoglobin, hemoglobin and platelets – known as Pseudo-microangiopathic hemolytic anemia.
- However, unlike TTP, the reticulocyte production index (RPI) is <2.0% (reflects inadequate bone marrow response), will not improve significantly with plasmapheresis, MMA will be elevated and median LDH is 3000 (median 1400 in TTP).
- Mechanism: The exact mechanism is not well understood, but has been demonstrated that elevated homocysteine levels cause intramedullary hemolysis, likely due to the pro-oxidative qualities of homocysteine while other in vitro studies demonstrated endothelial damage and thrombosis in association with elevated homocysteine levels, positing an additional intravascular component to the hemolysis.
- Interestingly, B12 levels may falsely appear normal in pernicious anemia because of buildup of homocysteine and MMA as a consequence of high levels of IF-Ab, which in turn alters the lab assay.
- Treatment:
 - Oral cobalamin 1000 to 2000 μg daily regardless of cause
 - an adequate amount of this dose will be absorbed, even if intrinsic factor is lacking or malabsorption is ongoing
 - Parenteral cobalamin is more expensive but also option
 - Our patient – daily IM B12 1000 mcg x7 days, followed by weekly x4 weeks, then monthly
 - Intranasal and oral gel formulations available but not clearly superior to tablets

References

1. Fahmawi Y, Campos Y, Khushman M, et al. Vitamin B12 deficiency presenting as pseudo-thrombotic microangiopathy: a case report and literature review. Clin Pharmacol. 2019;11:127-131. Published 2019 Aug 27. doi:10.2147/CPAA.S207258
2. Hassouneh R, Shen S, Lee O, Hart RA, Rhea LP, Fadden P. Severe Vitamin B12 Deficiency Mimicking Microangiopathic Hemolytic Anemia. J Hematol. 2020;10(4):202-205. doi:10.14740/jh899
3. Veit K. Pseudothrombotic microangiopathy and vitamin B12 deficiency in pernicious anemia. Proc (Bayl Univ Med Cent). 2017;30(3):346-347. doi:10.1080/0898280.2017.11929643

Thyroid Storm Leading to Cardiogenic Shock

Anjali Kakkar, DO

Department of Internal Medicine, Ochsner Medical Center, LA, USA

Introduction

Thyroid storm is rare, acute hypermetabolic state that presents with a variety of constitutional, GI, cardiac, and neurological symptoms. Tachyarrhythmias are a common early manifestation. Quick diagnosis and familiarity with complications of this state is imperative to prevent a fatal outcome, which has been noted to be as high as 30%.

Case Description

A 65 yo woman with PMH of Grave's Disease, hypertension, and medication non-adherence presented with lower extremity edema and dyspnea ongoing for three weeks. Other relevant symptoms included feeling overheated, fatigue, nausea, and orthopnea. She had not taken her prescribed medications in over a year. On physical exam, temperature 97.9F, HR 164, other vitals wnl. She had an irregular rhythm, bulging eyes, 3+ pitting edema of the legs bilaterally, and was axo x3. Her extremities were warm to the touch. Patient had no recent cardiac workup.

Diagnostic Studies

Day 1:	Day 2:	TTE: EF 20%, global hypokinesis, moderate RV dysfunction, biatrial enlargement, RVSP 45 mmHg, CVP 15 mmHg
• EKG – afib RVR	• Free T4: 1.84 ng/dL	
• Creatinine: 0.6 mg/dL	• Lactic acid: 6.0 mmol/dL	
• AST/ALT: normal	• Total bilirubin: 3.2	
• Total bilirubin: 1.5 mg/L	• AST/ALT: 1354/326	
• BNP: 670 pg/mL	U/L	
• Troponin: normal	• Creatinine: 1.3 mg/dL	
• Lactic acid: 2.0 mmol/L		
• TSH: <0.01 uIU/mL		
• Free T4: 2.50 ng/dL		

Imaging

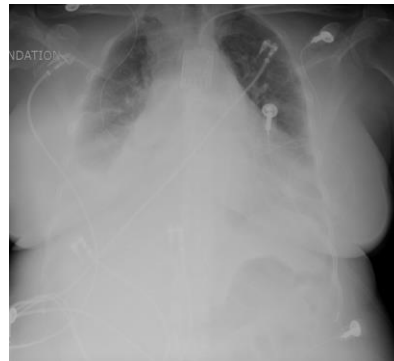

Fig 1 (left): AP X-ray chest Demonstrating enlarged cardiac silhouette, right pleural effusion, coarse interstitial attenuation, suspicious for pulmonary edema

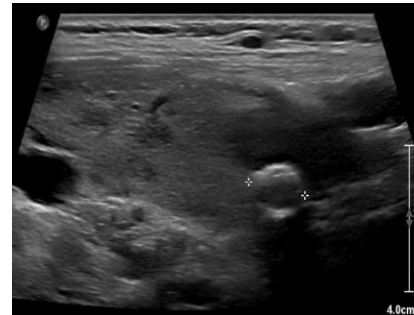


Fig 2 (right): US soft tissue head/neck/thyroid Thyromegaly with heterogeneous echotexture, multiple thyroid nodules (right lobe seen here)

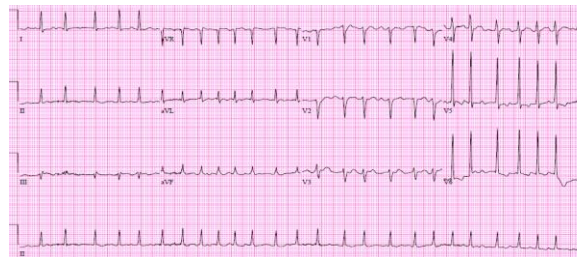


Fig 3 (left): Initial ECG demonstrating atrial fibrillation with rapid ventricular response

References

Burch HB, Wartofsky L: Life-threatening thyrotoxicosis. Thyroid storm. *Endocrinol Metab Clin North Am.* 1993, 22:263-77.
Siu, C.-W., Yeung, C.-Y., Lau, C.-P., Kung, A., & Tse, H.-F. (2006). Incidence, clinical characteristics and outcome of congestive heart failure as the initial presentation in patients with primary hyperthyroidism. *Heart*, 483-487. <https://doi.org/10.1136/jrt/2006.100628>

Management & Outcome

Patient was started on propranolol, propylthiouracil (PTU), steroids, apixaban (CHADSVasc 2), and IV furosemide. 24 hours later, she had acute decompensation with rising lactate, LFTs, and creatinine. On exam, she was hypoxic and cold with signs of low flow state. Hemodynamics revealed cardiac index of 1.5 L/min/m². Propranolol was discontinued & she was started on dobutamine, and transferred to ICU. Dobutamine was switched to milrinone. Endocrine switched PTU to methimazole given her ischemic hepatitis. Esmolol added for heart rate control. Clinically, patient responded and was transitioned to an oral regimen of digoxin, apixaban, metoprolol succinate, sacubitril/valsartan, and methimazole.

Discussion

This case highlights the potential for cardiopulmonary collapse in thyroid storm. In this case, early recognition of thyroid storm was made and guideline therapy was started. Beta blockers are recommended to treat thyroid storm to decrease hyperadrenergic symptoms, and medications such as propranolol also have been shown to decrease peripheral conversion of T4 to T3. It is also well known that initiation of beta blockers in acute heart failure can worsen outcome due to the negative inotropy. Familiarity with decompensated HF as a manifestation of severe thyrotoxicosis is imperative in order to make a clinical decision on whether to start or hold beta blockers. A bedside echo, not done here, is a cheap and effective way to assess cardiac function given the prolonged tachyarrhythmias these patients tend have. Prompt treatment of thyroid storm is crucial, however starting a beta blocker should be done only after acute heart failure is ruled out due to the risk of cardiac compromise, as seen in our patient.

An Ominous Presentation of *Staph hominis*

Lauren Dartez MS III LSUHSC New Orleans; Haider Mir M.D., Taylor Roussel M.D., David Mickey, M.D., Carl Giffin M.D.,
LSU Department of Internal Medicine

Introduction

- We present a case of acute aortic valve insufficiency caused by infectious endocarditis secondary to an unlikely pathogen
- Coagulase-negative staphylococci cause less than 5% of native valve infectious endocarditis cases. Of that subset, most cases are due to *Staphylococcus epidermidis*, making *Staphylococcus hominis* exceedingly rare¹
- The patient's only known risk factor for such infection was a spinal epidural injection

Case History

- Patient: 79-year-old Caucasian woman
- Medical history: COPD, tobacco abuse, GERD, hyperlipidemia, osteoporosis, lumbar radiculopathy, anxiety/depression, and a Schatzki's ring
- Chief complaint: several months of progressive dyspnea, orthopnea, nonproductive cough, and weight loss
- Physical exam: Vitals were notable for a widened pulse pressure (BP 119/31), tachycardia (107), and temperature of 97.9. She had a diastolic decrescendo murmur at the left 3rd intercostal space and bounding symmetrical radial pulses

Evaluation and Treatment

- We had a strong suspicion for aortic valve insufficiency
- TTE demonstrated severe aortic valve and moderate mitral valve regurgitation, Figure 1
- TEE showed a 0.5-1cm vegetation of the native aortic valve, Figure 2
- Blood cultures revealed growth in ¾ bottles for coagulase negative *Staphylococcus* which speciated as *Staphylococcus hominis*, a common noninvasive bacteria of common skin flora
- She denied prior abrasions, skin lesions, or IV drug use as a site of entry for staphylococcus hominis
- She underwent urgent aortic and mitral valve replacement surgery and received six additional weeks of antibiotic therapy

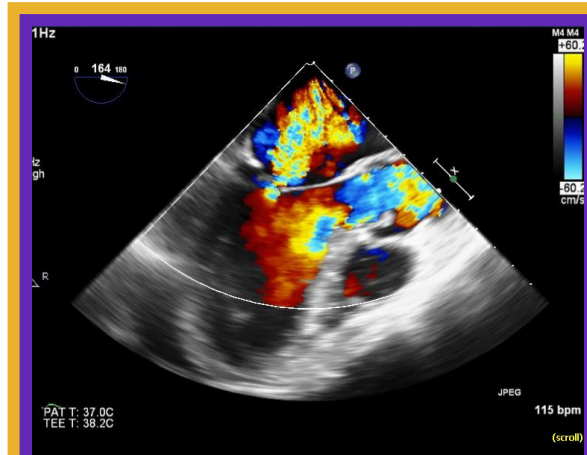


Figure 1: TEE with Doppler showing aortic valve regurgitation

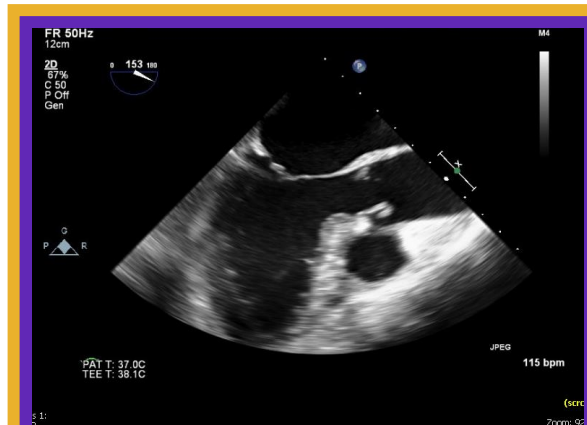


Figure 2: TEE showing aortic valve endocarditis

Discussion

This case demonstrates the importance of considering infectious causes such as endocarditis in the differential for acute aortic valve insufficiency, even in the absence of fever. Despite remaining afebrile and undergoing a relatively safe, common procedure of spinal epidural steroid injection², she developed an infectious complication. A review of adverse events from 11,980 intra-articular facet joint injection procedures performed from 2007-2017 found only one incident of infective endocarditis⁴.

Conclusion

- A newly recognized widened pulse pressure along with a diastolic murmur raises consideration for aortic valve insufficiency
- Infectious endocarditis should remain in the differential for acute aortic valve insufficiency
- While infectious complications from spinal epidural injections are rare, it is important to recognize this risk as these procedures become more commonplace.

References

1. Burke A, Cunha, Michael D, Esrick, Melissa LaRusso, *Staphylococcus hominis* native mitral valve bacterial endocarditis (SBE) in a patient with hypertrophic obstructive cardiomyopathy, *Heart & Lung*, Volume 36, Issue 5, 2007, Pages 380-382, ISSN 0147-9563, <https://doi.org/10.1016/j.hrtlung.2006.11.002>.
2. Helm Ii S, Harmon PC, Noe C, Calodney AK, Abd-Elseyed A, Knezevic NN, Racz GB. Transforaminal Epidural Steroid Injections: A Systematic Review and Meta-Analysis of Efficacy and Safety. *Pain Physician*. 2021 Jan;24(S1):S209-S232. PMID: 33492919.
3. Osama Nweiran Al-Khalaila, Laith Fawzat Tbishat, Mohamed Salah Abdelghani, Ahmad A.A. Al Bishawi, Adila Shaikat Kashaf, Dina Alwaheidi, Abdulwahid Al Mulla, Native tricuspid valve infective endocarditis with *Staphylococcus lugdunensis*: An unusual complication post spinal epidural injection – Case report and literature review, *IDCases*, Volume 24, 2021, e01097, ISSN 2214-2509, <https://doi.org/10.1016/j.idcr.2021.e01097>.
4. Kim BR, Lee JW, Lee E, Kang Y, Ahn JM, Kang HS. Intra-articular facet joint steroid injection-related adverse events encountered during 11,980 procedures. *Eur Radiol*. 2020 Mar;30(3):1507-1516. doi: 10.1007/s00330-019-06483-3. Epub 2019 Nov 11. PMID: 31712959.



Acute Disseminated Encephalomyelitis in a Pregnant Patient with Multiple Sclerosis

Ali Yousuf, DO; Matt Perkins MD; Shakira Harding, MS-3;
Nataliya Uhrynychuk, MS-4; Shaun Walker, DO

Louisiana State University Health Sciences Center at Ochsner University Hospital & Clinics
Department of Internal Medicine- Lafayette, LA

Introduction

- Current literature demonstrates that during pregnancy, patients with Multiple Sclerosis (MS) have a decreased relapse rate as opposed to during the postpartum period, when they have an increased rebound relapse rate of MS (Voskuhl).
- Temporarily terminating MS medications, especially in the case of a patient attempting for pregnancy, carries the risk of neuro-immunological relapses despite pregnancy serving as a protective factor.
- Acute Disseminated Encephalomyelitis (ADEM) is an immune mediated demyelinating disease that can present similarly to an acute Multiple Sclerosis flare. While pregnancy is generally considered protective in MS, it is also known to exacerbate the symptoms of ADEM. These findings can be due to the immunological changes during pregnancy. The timing of treatment of these acute disease processes need great consideration in the setting of a pregnant patient.
- We report a case of a patient with a past medical history of Multiple Sclerosis presenting with Acute Disseminated Encephalomyelitis at 6 weeks gestation requiring high dose steroid treatment and plasmapheresis resulting in a spontaneous abortion.

Case Description

- On 8/9/2021, an AAF 32-year-old female with a history of MS presented at 6 weeks gestation with altered mentation, limb weakness, poor oral intake, and difficulty conversing. Her symptoms had been progressively worsening over the previous 2 weeks.
- One month prior, she stopped taking her MS medications in order to conceive. On arrival, the patient was noted to be in acute respiratory distress, unresponsive, and unable to follow commands. She was hypertensive, tachycardic, and had an anion gap metabolic acidosis. Her acidosis was determined to be secondary to severe uremia requiring emergent hemodialysis (HD). HD provided no clinical improvement in neurological status. She was admitted to the intensive care unit and intubated.

Case Description cont.

- Based on magnetic resonance imaging and cerebrospinal fluid analysis, a diagnosis of ADEM was established. Plasma exchange was performed without improvement.
- At this time, it was determined that treatment with high dose steroids would outweigh the risk of pregnancy complications. She received this regimen of plasmapheresis and high dose steroids for the next few days. Approximately 4 days later the patient had a spontaneous abortion, confirmed by pathology.
- Ultimately, the decision was reached for placement of Tracheostomy and percutaneous endoscopic gastrostomy tube for the chronic management of the patient's respiratory and nutritional status.
- On 8/27/2021, patient was discharged to a long-term acute care facility.

Imaging

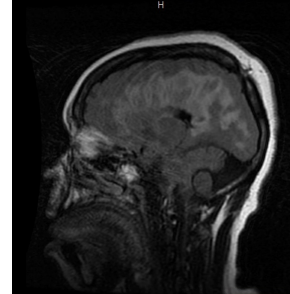


Image 1. MRI- Brain

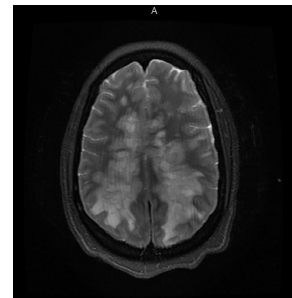


Image 2. MRI-Brain

Conclusion

- Although MS and ADEM may initially present in a similar manner, MRI results can aid in distinguishing the two. This is because MS lesions tend to be more defined and disseminated in time while ADEM lesions are less precise, monophasic, and not disseminated in time, thus appearing the same age on imaging.
- Thalamus lesions are more common in ADEM while periventricular lesions are more characteristic in MS. (Anilkumar).
- The patient's condition worsened after conception, which may indicate that the onset of ADEM was related to pregnancy. The majority of ADEM cases were exacerbated during pregnancy and improved by plasmapheresis and/or steroids. However, our patient's clinical symptoms did not improve with the previously mentioned therapy. It is possible that the superimposition of MS on ADEM contributed to our patient's poor prognosis.
- Special consideration needs be made for timing of therapy. The previously mentioned therapy to treat the patient's situation was detrimental to the pregnancy itself. Once the decision was made to treat the patient irrespective of the pregnancy, more therapeutic treatments were able to be administered.
- Nonetheless, the relationship between autoimmune demyelinating diseases and pregnancy is complex and warrants further study.

References

- Anilkumar AC, Foris LA, Tadi P. Acute Disseminated Encephalomyelitis. [Updated 2021 Jul 19]. In: StatPearls [Internet]. Treasure Island (FL): StatPearls Publishing; 2021 Jan-. Available from: <https://www.ncbi.nlm.nih.gov/books/NBK430934/>
- Gaudry P, Lantheaume S, Renard JL, Koullmann PH, Ponties JE. The follow-up of acute disseminated encephalomyelitis in a comatose pregnant woman. Eur J Obstet Gynecol Reprod Biol. 2006 Jan 1;124(1):123-5. doi: 10.1016/j.ejogrb.2005.06.031. Epub 2005 Aug 15. PMID: 16099583.
- Kaur G, Neekhra A, Houghton D, Scarff JR, Lippmann S. Resolution of acute disseminated encephalomyelitis following termination of pregnancy. Psychosomatics. 2014 Jan-Feb;55(1):101-4. doi: 10.1016/j.psych.2013.05.010. Epub 2013 Sep 5. PMID: 24012291; PMCID: PMC7111698.
- Macerollo A, Dalfino L, Brienza N, Campobasso N, Pertosa G, Dicuonzo F, Simone IL, Tortorella C. Life-threatening ADEM in an immunocompetent pregnant woman with concomitant asymptomatic Cytomegalovirus infection. J Neurol Sci. 2016 May 15;364:53-5. doi: 10.1016/j.jns.2016.03.015. Epub 2016 Mar 9. PMID: 27084216.
- Qiu K, He Q, Chen X, Liu H, Deng S, Lu W. Pregnancy-Related Immune Changes and Demyelinating Diseases of the Central Nervous System. Front Neurol. 2019;10:1070. Published 2019 Oct 9. doi:10.3389/fneur.2019.01070
- Shah AK, Tselis A, Mason B. Acute disseminated encephalomyelitis in a pregnant woman successfully treated with plasmapheresis. J Neurol Sci. 2000 Mar 15;174(2):147-51. doi: 10.1016/s0022-510x(00)00260-4. PMID: 10727701.
- Voskuhl R, Momtazee C. Pregnancy: Effect on Multiple Sclerosis, Treatment Considerations, and Breastfeeding. Neurotherapeutics. 2017 Oct;14(4):974-984. doi: 10.1007/s13311-017-0562-7. PMID: 28766273; PMCID: PMC5722767.



A comparison of a novel cellular host response test to the PSI prediction score in identification of high-risk CAP patients

Hannah E. Bunch, MD; Christopher B. Thomas, MD; Hollis R. O'Neal, Jr., MD.

LSUHSC Baton Rouge Internal Medicine Residency Program



Introduction

- Community Acquired Pneumonia (CAP) is a common cause for ED visits.¹
- The Pneumonia Severity Index (PSI) is a complex risk-stratification tool.
- Our aim was to compare the IntelliSep test, a novel, rapid (< 10 min) sepsis diagnostic, with the PSI for identification of high-risk patients with CAP.

Methods

- The IntelliSep test is an investigational in-vitro diagnostic that quantifies the state of immune activation by measuring the biophysical properties of leukocytes from a routine, EDTA-anticoagulated blood sample in under 10 minutes.²
- The test provides a single score, the IntelliSep Index (ISI), between 0.1-10.0 (inclusive), stratified into three discrete interpretation bands of risk for disease severity: Green, Yellow, and Red.
- We analyzed a subgroup of patients with respiratory infection enrolled in two prospective cohorts performed to assess the performance of the ISI as a sepsis diagnostic.
- We included patients who were determined to have a respiratory infection by retrospective physician adjudication in this study.
- Chart review was used to retrospectively calculate PSI scores for each patient.
- Each patient had a previously documented IntelliSep test obtained in the ED.
- The Green, Yellow, and Red bands were compared to PSI scores of < 90, 90-130, > 130 respectively.
- High-risk outcomes including in-hospital mortality, ICU admission, 3-day minimum P/F ratio < 200 and the need for vasopressors were evaluated for comparison between risk categories.

Figures

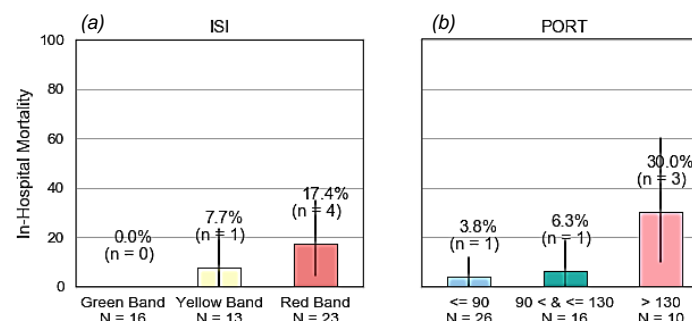


Figure 1: In-Hospital Mortality for (a) ISI and (b) PORT score.

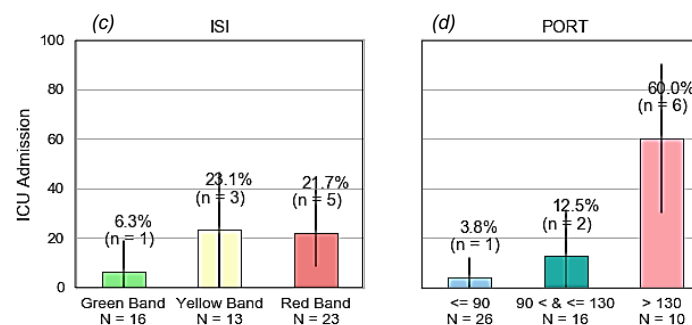


Figure 2: ICU Admission for (c) ISI and (d) PORT score.

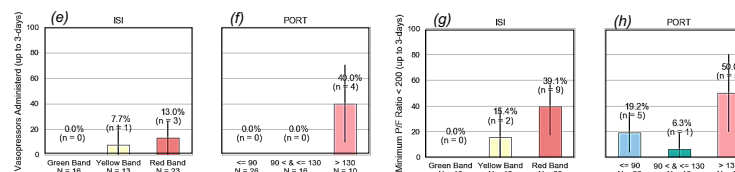


Figure 3: Vasopressors administered for (e) ISI and (f) PORT score.

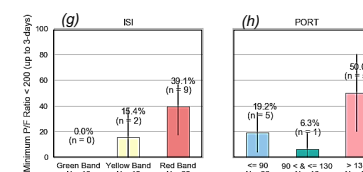


Figure 4: 3-day minimum P/F ratio <200 for (g) ISI and (h) PORT score.

Results

- A total of 52 patients were included, 48 were admitted.
- The ISI was found to correspond well with the PSI (Green band median PSI = 75, Red band median PSI = 105, $p < 0.05$), with 16, 13, and 23 patients stratified to Green, Yellow, and Red bands respectively and 26, 16, and 10 patients with PSI scores of < 90, 90-130, and > 130 respectively.
- Of the five patients that died, the ISI stratified four to the Red band; three had a PSI > 130.
- Nine patients required ICU admission, including one patient in each low-risk category.
- A P/F ratio < 200 was found in 11 patients, all of which were in Yellow or Red bands of the ISI; the PSI determined five of these to have PSI scores < 90. Four patients required vasopressors during the first three hospital days, with none in the lowest-risk categories of the ISI or PSI.

Conclusion


- The ISI is single lab test that may yield similar risk stratification to the PSI in identifying high risk patients with CAP.
- Further study with a prospective cohort is needed to better compare ISI to the PSI for its potential application in the clinical setting.

References

- Cairns C, Kang K, Santo L. National Hospital Ambulatory Medical Care Survey: 2018 emergency department summary tables.
- Guillou, Lionel, et al. "Development and Validation of a Cellular Host Response Test as an Early Diagnostic for Sepsis." PLOS ONE, edited by Aleksandar R. Zivkovic, vol. 16, no. 4, 2021, p. e0246980.

An Unexpected Cause of Hypercalcemia in Primary Hyperparathyroidism

Griffin Farrish, MD; William Benton, MD; Carl Giffin III, MD; Jolene Johnson, MD
Louisiana State University Internal Medicine Program, Baton Rouge, LA
Our Lady of the Lake Regional Medical Center, Baton Rouge, LA



Introduction

- Primary hyperparathyroidism (PHPT) is the most common cause of hypercalcemia
- PTH levels are inappropriately raised due to parathyroid gland overactivity that resists suppression from high calcium
- Elevated PTH promotes bone resorption and decreases bone density, which can predispose to fractures
- PTH-independent mechanisms of bone resorption leading to elevated calcium include malignancy, thyrotoxicosis and immobilization
- PHPT that occurs concomitantly with these other conditions can manifest in very severe presentations of hypercalcemia and fracture

Case Presentation

- A 57-year-old woman with a history of PHPT and chronic hypercalcemia presented to the ED after routine labs showed a severely elevated calcium
- Repeat lab work confirmed hypercalcemia, AKI, anemia and a PTH within normal limits
- 11 months ago she had presented to the ED with lower back pain and was diagnosed with multiple vertebral fractures, but had not experienced any more fractures since that event
- She was treated with normal saline resuscitation, calcitonin 200 mg and zoledronic acid 4 mg
- Her calcium normalized and her AKI resolved, and she was discharged to follow-up with endocrinology, but later that month she re-presented with acute back pain
- MRI's revealed multiple new vertebral fractures
- Further hypercalcemia work-up revealed elevated serum and urine free light chains
- She was referred to Hematology/Oncology, and a bone marrow biopsy was diagnostic for multiple myeloma (MM)

Laboratory

	12/2020	2/2021
Calcium	11.0	15.4
PTH	84.9	43.6
Creatinine	0.99	1.56
Hemoglobin	12.4	11.1

- Vit D: 61.1
- PTHrP: <2.0
- Serum Free Light Chains: **Kappa 239.5**, Lambda 5.9, **Kappa/Lambda Ratio 40.59**
- Urine Immunoelectrophoresis: "monoclonal protein present of the following type: free kappa light chains"
- Bone Marrow Biopsy: "hypercellular bone marrow (70%) with involvement by plasma cell myeloma (80% involved)"
- FISH Panel: "gain of chromosomes 7 and 9, monosomy for chromosome 13, loss of IGH/14q"

Imaging

	3/2020	2/2021
Thoracic MRI	"Subacute traumatic compression fracture at T12"	"There is significantly worsened thoracic kyphosis compared to 3/2020. There are new osteoporotic compression deformities of the T2, T3, T4, T9, T10, T11, T12 vertebral bodies"
Lumbar MRI	"Subacute traumatic compression fractures at L1, L3 and L5"	"Nondisplaced acute appearing osteoporotic compression fracture L2. Further interval loss of height of compression deformities L1, L3, L4 and L5"

- DEXA Scan (8/2020)
 - L1-L4 T-score: -1.0
 - Left Femoral Neck T-score: -1.7
- FRAX: 6% risk of major osteoporotic fracture and 0.6% of hip fracture in the next 10 years

Discussion

- This patient with previously diagnosed PHPT was known to have chronically elevated calcium
- Her presentation with a calcium of 15.4 mg/dL and new fractures was initially attributed to progression of her disease
- In retrospect, it is rare for PHPT to cause calcium elevations >12 mg/dL
 - Especially with adequate vitamin D levels and no calcium-raising drugs (thiazide diuretic, lithium)
- Additionally, the DEXA scan completed months after her initial fractures showed only mild osteopenia inconsistent with the severity of her fractures
- The decrease in her PTH from 84.9 pg/mL to 43.6 pg/mL in the setting of worsening calcium suggested the presence of a separate pathologic mechanism
- Multiple myeloma (MM) is a hematologic malignancy in which monoclonal plasma cells proliferate in bone marrow and produce paraproteins such as free light chains
- MM is often characterized by the "CRAB" criteria which were all present in this patient
 - Elevated calcium, renal injury, anemia and bone disease
- Fractures are the most common presenting sign of MM, and her chronic PHPT weakened her bones making them more susceptible to an aggressive and destructive malignancy
- Biopsy confirmed diagnosis and treatment will be determined by Hematology/Oncology, but typically it involves:
 - Evaluation for hematopoietic cell transplantation
 - Induction chemotherapy with bortezomib, lenalidomide and dexamethasone

References

- Bilezikian J. Primary Hyperparathyroidism. *The Journal of Clinical Endocrinology & Metabolism*. Volume 103, Issue 11, November 2018, Pages 3993–4004. <https://doi.org/10.1210/nc.2018-01225>
- Vestergaard P, Mollerup CL, Frekjaer VG, Christiansen P, Blichert-Toft M, Mosekilde L. Cohort study of risk of fracture before and after surgery for primary hyperparathyroidism. *BMJ*. 2000 Sep 9;321(7261):598-602. doi: 10.1136/bmj.321.7261.598. PMID: 10977834; PMCID: PMC27473.
- Renaghan A, Roemer M. Hypercalcemia: etiology and management. *Nephrology Dialysis Transplantation*. Volume 33, Issue 4, April 2018, Pages 549–551. <https://doi.org/10.1093/ndt/gfy054>
- van de Donk NWJC, Pawlyn C, Yong KL. Multiple myeloma. *Lancet*. 2021 Jan 30;397(10272):410–427. doi: 10.1016/S0140-6736(21)00135-5. PMID: 33516340.
- Kumar SK, Callander HS, Adekola K, Anderson L, Baljevic M, Campagnaro E, Castillo JJ, Chandler JC, Costello C, Eleba Y, Fauman M, Garfall A, Godby K, Hillengass J, Holmberg L, Hut M, Huff CA, Kang Y, Hultcrantz M, Larson S, Liedtke M, Martin T, Omel J, Shain K, Sborov D, Stocker-Goldstein K, Weber D, Keller J, Kumar R. Multiple Myeloma, Version 3.2021. NCCN Clinical Practice Guidelines in Oncology. *J Natl Compr Canc Netw*. 2020 Dec 2;18(12):1685–1717. doi: 10.6004/jnccn.2020.0057. PMID: 33285522.

Introduction

- Eosinophilic Granulomatosis with Polyangiitis (EGPA) is a very rare form of vasculitis that affects approximately 5000 individuals in the United States.
- The vasculitis involved in the disease process normally affects small to medium sized vessels, causing inflammation, blockage, and eventually end organ damage.
- Although this damage process can affect any organ in the body, this type of vasculitis is most commonly seen in the lungs with other skin manifestations.
- EGPA usually develops in three phases: the prodromal phase, eosinophilic phase, and vasculitic phase.
- The phases are encountered normally in order, with more serious disease found in later phases.

Case Description

- 37 year old female presented to the ER with chest pain after an EKG at an outside urgent care showed ST depression with a troponin elevation of 22. Angiogram and TTE done at the time were unremarkable. Patient was then presumed to have myocarditis and discharged with indomethacin.
- 5 days later, patient was readmitted for left upper extremity weakness that had started overnight. An MRI of the brain showed acute watershed ischemia with hemorrhagic transformation.
- On further interview, the patient stated she had a history of SLE diagnosed in 2010 but was never on DMARD therapy. Instead, she was placed on prednisone for 9 years and had stopped recently because of no SLE symptoms.
- The TEE was negative for vegetations and the patient's labs revealed hyper eosinophilia. At this point, the patient was discharged from the hospital with scheduled bone marrow biopsy to rule out malignancy. She was also restarted on prednisone 60mg daily and instructed to follow up in Rheumatology clinic for further workup
- Further labs showed the patient had positive MPO antibody suggestive of EGPA as well as a component of hypereosinophilia syndrome suggested by results of the bone marrow biopsy.
- With prednisone treatment, the patient's labs normalized and symptoms seemed to resolve, however they would reoccur with any tapering of the steroids. Patient was also started on mepolizumab 300mg every 4 weeks.
- Ultimately the patient's eosinophilia resolved with improvement in symptoms while on medications

Labs

Lab View	11/3/2020 8:04 CST	11/3/2020 5:00 CST
ANA Titer-ARUP		* A 1:160
ANA, HEp-2, IgG-ARUP		A Detected
ANA Interp-ARUP		* See Note
Smith (5m) Ab		Equivocal
SSA (Ro) Ab		
SSB (La) Ab		
dsDNA IFA-ARUP		* < 1:10
RNP Ab IgG-ARUP		* 19
Cardiolipin IgG-ARUP		* 0
Cardiolipin IgM-ARUP		* H 21
MPO Ab IgG-ARUP		* H 57
Serine Prot 3-ARUP		* 3
ANCA IgG-ARUP		* < 1:20
HIV		Nonreactive
Smith Ab IgG-ARUP		* 5
Hep Bs Ag		* Nonreactive
Hep C Ab		* Nonreactive
Ascaris-ARUP		* < 0.10
Immcap Score-ARUP		* See Note
Rheum Factor Qnt		< 13
IgE-LC		* 38
MTHFR-LC	* Comment	
CH50-LC		* > 60
Toxoplasma IgG-LC		* < 3.0
Toxocara Antibodies-LabCorp		* Negative
Strongyloid IgG-LC		* Negative

Table 1. Labs indicating elevated eosinophils, + MPO Ab, and low positive APLA antibodies

Imaging

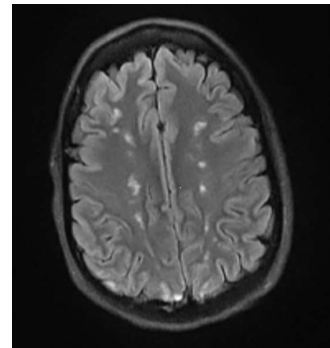


Image 1. MRI Brain demonstrating acute watershed ischemia

Conclusion

- The combination of Glucocorticoids and Mepolizumab worked for this patient well and should be continued to be used in situations that combine EGPA with hyper-eosinophilic syndrome in the future.
- This case illustrates the thought process that should be involved with making a broad differential diagnosis when dealing with a very rare disease, and always considering an autoimmune process with multi-organ involvement in a young adult.
- EGPA is approximately 2-10 times less common than other ANCA associated vasculitis with prevalence and annual incidence estimated at 2-22 and 0.5-3.7 per million respectively. + ANCA antibodies, usually p-ANCA/myeloperoxidase ANCA, may be found in only 30–40% of EGPA patients.
- This case report demonstrates the unusual presentation of EGPA with no asthma related issues, skin issues or lung involvement: all of which are usually hallmarks.
- Literature indicates that lung infiltrates are more related to negative ANCA, which correlates with our patient's case.
- A peripheral blood eosinophilia >10% is one of the clinical criteria for EGPA diagnosis. In this case, the patient's blood exams demonstrated leukocytosis with marked eosinophilia (34%)
- This case illustrates that EGPA and Hyper-Eosinophilia can present with an additional Antiphospholipid Syndrome leading to CVA and other catastrophic complications. Thorough investigation of patient's history can be crucial when dealing with complicated autoimmune disease processes.
- Because EGPA is a rare disease, there is a lack of high quality clinical trials. Thus, expert recommendations for the treatment of EGPA are commonly made by an analogy to clinical trial data derived for other forms of ANCA-associated vasculitis.

References

- Santos, Yuri Albuquerque Pessoa. "Eosinophilic Granulomatosis with Polyangiitis (Formerly Known as Churg-Strauss Syndrome) as a Differential Diagnosis of Hypereosinophilic Syndromes." *Respiratory Medicine Case Reports*, Elsevier, 8 Mar. 2017.
- Moosig F. Eosinophilic granulomatosis with polyangiitis: future therapies. *Presse Med.* 2013 Apr;42(4 Pt 2):510–512.
- Mahra A., Moosig F., Neumann T., Szczekliki W., Taillé C., Vaglio A. Eosinophilic granulomatosis with polyangiitis (Churg-Strauss): evolutions in classification, etiopathogenesis, assessment and management. *Curr. Opin. Rheumatol.* 2014 Jan;26(1):16–23.
- Moosig F., Gross W.L., Herrmann K., Bremer J.P., Hellmich B. Targeting interleukin-5 in refractory and relapsing Churg-Strauss syndrome. *Ann. Intern. Med.* 2011 Sep;115(5):341–343.

Introduction

In the age of antibiotics, rates of syphilis and neurosyphilis hit historic lows in the early 2000s. However, even with well established treatments and testing in place, the absolute number of cases of syphilis have steadily increased since that time. In 2019 alone, close to 40,000 cases in the United States were reported. Louisiana, in particular, faces a disproportionate amount of patients with syphilis and ranks in the top 10 states in regard to prevalence. Further, while development of neurosyphilis is increasingly rare, a review of multiple studies found approximately 0.7-3.5% of patients with syphilis had confirmed neurosyphilis, and that neurological complications may occur in up to 10% of patients. Here we report a case of symptomatic neurosyphilis in a high risk patient.

Case Presentation

A 71 year old gentleman with a history of trigeminal neuralgia presented to the hospital for evaluation following a brief period of unresponsiveness, concerning for seizure. The patient clutched his friend's arm for 5-10 minutes and became unresponsive to verbal stimuli. Per collateral history, there was also a short post-ictal state which subsequently resolved. Though the patient has no recollection of the episode, he reported having similar, occasional episodes in the last ten years. Prior neurologic workup, including EEG and MRI brain, was unremarkable for seizure activity or underlying medical cause. On this admission, he had a blood pressure of 152/88, pulse of 90, was afebrile and saturating well on room air. Neurologic examination was unremarkable without any focal deficits, cerebellar findings or decreased peripheral sensation. However, further history from the patient prompted a comprehensive workup. He reported acute memory loss within the last three months, difficulty caring for himself, occasional gait imbalance and decreased sensation in his feet. Patient denied any other systemic or acute symptom, though noted being a sex worker in a bath house for an extended period of time in the 1970s. He was unaware of any previous sexual transmitted infections.

Lab work was significant for a reactive serum treponema pallidum antibody. RPR titer was non-reactive. Electroencephalography revealed evidence of right focal temporal spikes and cortical excitability. Cerebrospinal fluid (CSF) protein and glucose were elevated at 82.7 mg/dL and 81 mg/dL, respectively. CSF gram stain did not show any organisms, though had a few white blood cells. Meningitis and encephalitis panel were negative.

Given these results, intravenous, continuous penicillin was initiated to treat neurosyphilis. This management decision was made while CSF VDRL and CSF treponema pallidum antibody were pending. Elevated CSF protein, reactive serum antibody, high risk patient history and lack of reported treatment of syphilis collectively crossed the threshold to treat for neurosyphilis. Data show that RPR titer can be negative in late course neurosyphilis. In fact, guidelines recommend treatment when CSF protein is greater than 45 mg/dL, even in the setting of a non-reactive CSF-VDRL or CSF white cell count less than 5.

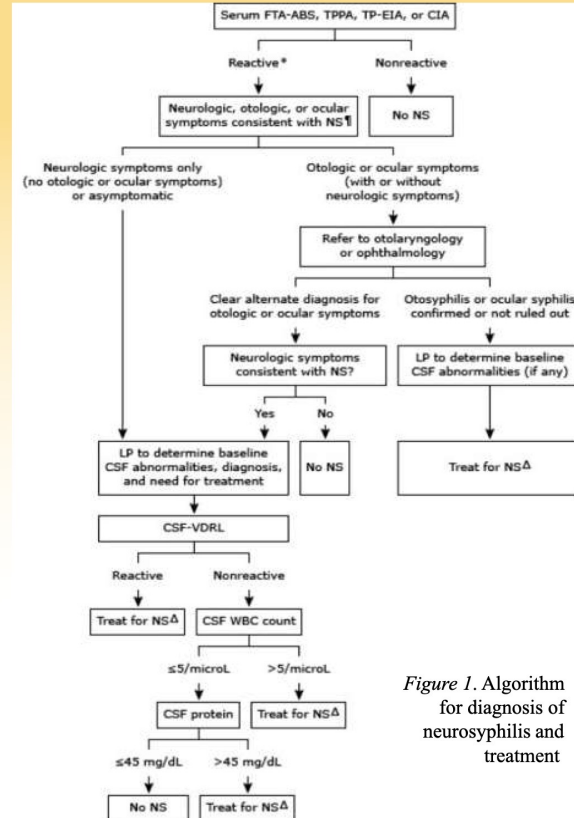


Figure 1. Algorithm for diagnosis of neurosyphilis and treatment

Discussion

Data on response to treatment of neurosyphilis is constricted with no real conclusive evidence. On outpatient follow up, patients are evaluated with neurologic physical exams and typically will have a lumbar puncture performed at six months or until CSF VDRL and WBC normalize. Upon review of current case reports and reviews, most patients seem to have resolution of objective findings of syphilis within a year of treatment.

In cases of neurosyphilis with symptomatic involvement, as in this patient, return of cognitive function and improvement of impairment is limited. Though prompt treatment with antibiotics likely halts progression of neurologic symptoms, there is no clear, consistent reversibility in these patients. Anecdotally, the patient presented here initially decided to pursue assisted living given his concern of cognitive decline and difficulties with daily living activities. By the end of his inpatient IV antibiotic treatment, he reported subjective return to mental baseline and decided to return to his apartment. This improvement initially occurred within two weeks of antibiotic initiation. Again, though extremely limited, this case could indicate reversibility of mental deficits in neurosyphilis.

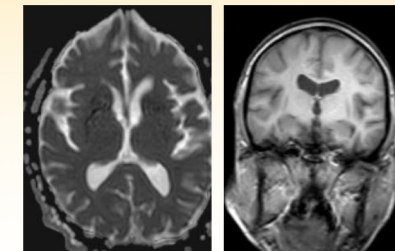


Figure 2. MRI of brain. Findings notable for moderate ventricular prominence. No parenchymal abnormalities.

References

1. Taylor, M. M. et al. A Consequence of the Syphilis Epidemic Among Men Who Have Sex With Men (MSM): Neurosyphilis in Los Angeles, 2001–2004. *Sexually transmitted diseases* 85, 430 (2006).
2. Ha, T., Tadi, P. & Dubensky, L. Neurosyphilis. *StatPearls* (2021).
3. Donbrowski, J. C., Pedersen, R., Marra, C. M., Kern, R. P. & Golden, M. R. Prevalence estimates of complicated syphilis. *Sexually Transmitted Diseases* 42, 702–704 (2015).
4. Quilley, L. A. S. et al. Prevalence of Self-reported Neurologic and Ocular Symptoms in Early Syphilis Cases. *Clinical Infectious Diseases* 72, 961–967 (2021).
5. Clark, E. G. & Danbolt, N. The Oslo study of the natural history of untreated syphilis: an epidemiologic investigation based on a restudy of the Boeck-Brenneke material: a review and appraisal. *Journal of chronic diseases* 2, 311–344 (1955).
6. Ho, E. L. & Marra, C. M. Treponema Tests for Neurosyphilis – Less Accurate Than What We Thought? *Sexually transmitted diseases* 39, 298 (2012).
7. Birnbaum, N. R., Goldschmidt, R. & Butler, W. Resolving the Common Clinical Dilemmas of Syphilis. *American Family Physician* 59, 2233 (1999).
8. van Eijk, R. S. et al. Effect of early and late syphilis on central nervous system: cerebrospinal fluid changes and neurological deficits. *Geriatrics* 63, 77 (1987).
9. O'Neary, P. A. et al. COOPERATIVE CLINICAL STUDIES IN THE TREATMENT OF SYPHILIS: ASYMPTOMATIC NEUROSYPHILIS. *Archives of Dermatology and Syphilology* 35, 387–401 (1937).
10. Zhang, H. L. et al. Clinical spectrum of neurosyphilis among HIV-negative patients in the modern era. *Dermatology (Basel, Switzerland)* 126, 148–156 (2013).
11. Marra, C. M., Maxwell, C. L., Tantalos, L. C., Sahi, S. K. & Lakehart, S. A. Normalization of serum rapid plasma reagin titer predicts normalization of cerebrospinal fluid and clinical abnormalities after treatment of neurosyphilis. *Clinical Infectious Diseases* 47, 893–899 (2008).
12. Marra, C. M. et al. Normalization of cerebrospinal fluid abnormalities after neurosyphilis therapy: Does HIV status matter? *Clinical Infectious Diseases* 38, 1001–1006 (2004).
13. Beauchemin, P. & Laforce, R. Neurocognitive Changes in Tertiary Neurosyphilis: A Retrospective Chart Review. *Can J Neurol Sci* 41, 452–458 (2021).
14. Ibbai, S. & Lyons, J. L. Neurosyphilis Update: Atypical is the New Typical. *Current infectious disease reports* 17, 1–6 (2015).
15. Vargas, A. P., Cano-Arteaga, F. J., del Negro, M. C. & Rodriguez, M. P. C. Deterioración por neurosífilis: evolución clínica e neuropsicológica de un paciente. *Revista de Neuro-Psiquiatria* 58, 578–582 (2000).

Covid-19 Vaccine and Atrial Fibrillation Risk: A Pharmacovigilance Analysis

Ayeesha Kattubadi MD, Juan I. Solórzano MD, Katey Feng PhD, Vijaywant Brar MD, Paari Dominic MD.

Department of Internal Medicine, Louisiana State University Health Sciences Center – Shreveport.

Department of Medicine and Center for Cardiovascular Diseases & Sciences, Louisiana State University Health Sciences Center – Shreveport.

BACKGROUND

- COVID-19 vaccines have proven to be safe and efficacious in reducing transmissibility and severity of infection.
- As they are new there is need for understanding potential adverse effects(AE) and take appropriate measures to reduce untoward disease burden.

OBJECTIVE

To observe if a relationship exists between COVID vaccines and Atrial Fibrillation (AF).

METHOD

- The FDA Adverse Event Reporting System (FAERS) and Vaccine Adverse Event Reporting System (VAERS) are two publicly available databases that collect AE reports globally.
- These databases were used to search AF as an AE reported with the use of Moderna, Pfizer, and Johnson & Johnson (J&J) COVID vaccines.
- The Proportional Reporting Ratio (PRR) was used to detect disproportionate reporting of AF amongst the different COVID vaccines.
- With the VAERS data the AF events were subcategorized as new onset vs recurrence of chronic AF. Patient demographics, comorbidities, onset interval from the last dose and hospitalization due to AF were also analyzed.

Demographics of People Reporting Atrial Fibrillation in the VAERS database			
	Pfizer	Moderna	Johnson & Johnson
Total number of reports	705	324	73
Mean Age (years) ± SD	69.4 ± 13.3	67.6 ± 11.4	59.1 ± 14.9
Sex	Male (%)	48.5	53
	Female (%)	51	47
	Unknown (%)	0.05	0.006
Median Onset Interval (Days)	3	5	7
% New Onset AF of total reported cased	68	69	1
% Hospitalized of total reported	50	55	79
% Of subjects with Cardiac comorbidities amongst total reported	52	44	71
% Of subjects with non-Cardiac comorbidities amongst total reported	38	64	41

RESULTS

- The FAERS data showed the PRR for reported AF was highest with Pfizer 4.19, followed by Moderna 2.38, and there were no AF events reported with J&J vaccine.
- The VAERS data showed that the PRR for all AF events reported was comparable among vaccines (Moderna 1.08, J&J 0.95, Pfizer 0.94).
- With VAERS the PRR for new onset AF events were also comparable (Moderna 1.2, Pfizer 1.15, J&J 0.02).

DISCUSSION

- PRR can be used as a signal generation tool to assess adverse drug reaction events.
- A PRR value of > 2 is considered statistically significant. In our analysis we found the PRR for AF with Pfizer was 4.19 and Moderna 2.38 with the FAERS database.
- With the VAERS database the PRR for AF was not statistically significant amongst the vaccines.

CONCLUSION

While data reported to FAERS shows a disproportionately higher AF AE with Pfizer COVID vaccine, more detailed reports from VAERS shows comparable AF events with the vaccines. Further systematic studies are indicated to better understand the true relationship.

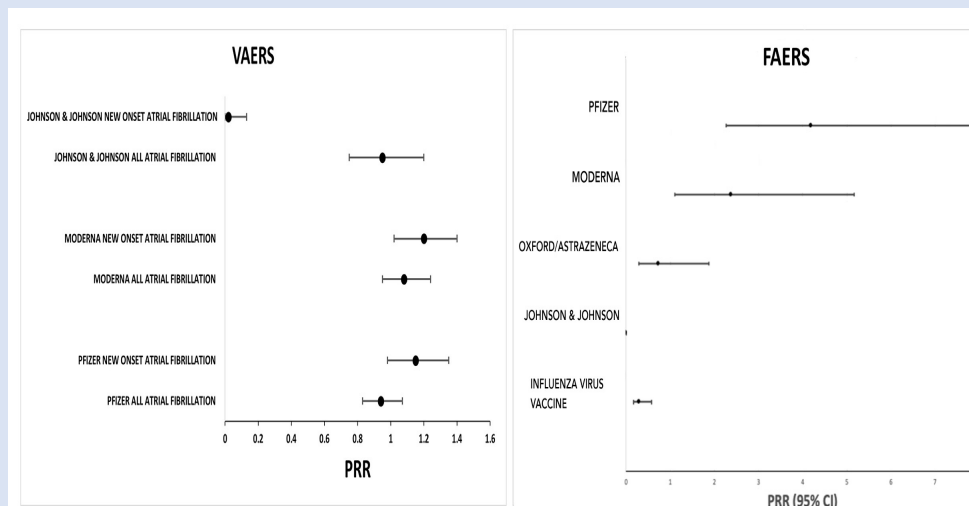


Fig 2: Forest graph depicting PRR and CI for Atrial Fibrillation with COVID vaccines with VAERS and FAERS database



Baton Rouge General

Internal Medicine Residency Program

Anorectal Mucosal Melanoma: A rare but potentially fatal cause of rectal bleeding

Rameela Mahat MD, Gift Echefu MD, Deepti Kantamani MD, M. Patrick Stagg MD

Baton Rouge General Medical Center, Baton Rouge, Louisiana



Introduction

Anorectal Mucosal Melanoma (ARM) is a rare and aggressive malignancy which accounts for less than 1% of all melanomas, less than 0.1% of all colorectal malignancies, and 4% of anal malignancies[3].

Case Description

- ❑ A 71-year-old African American male was seen in the gastroenterology clinic for complaints of rectal bleeding. He reported on and off episodes of rectal bleeding three to four times a week, associated with rectal pain and pruritus for past two years. He endorsed a 10-pound weight loss over the last three months. He denied abdominal pain, appetite change, altered bowel habits, or change in stool caliber.
- ❑ Past medical history was significant for hypertension, mild cognitive impairment, Covid-related cerebellar stroke, previously treated prostate cancer 10 years prior with radiotherapy, diverticulosis.
- ❑ Colonoscopy performed 6 months prior revealed non-bleeding thrombosed external and internal hemorrhoids and 4 mm sessile polyp in the rectum. The polyp was completely resected at that time, and the biopsy revealed tubular adenoma.
- ❑ His primary care doctor treated his hemorrhoids with suppositories. He was then seen by a gastroenterologist for persistent rectal bleeding despite therapy for hemorrhoids.
- ❑ Digital rectal examination showed grade II internal hemorrhoids. Flexible sigmoidoscopy showed a 14 mm oozing, polypoid, semi-pedunculated lesion in the distal rectum.
- ❑ A pre-operative computed tomography (CT) scan of the abdomen and pelvis in the hospital showed an ill-defined soft tissue thickening of the inferior 4.5 cm of the rectum and anorectal junction suspicious for malignancy.
- ❑ He underwent a full thickness trans anal resection of a relatively fixed posterior midline anorectal mass.
- ❑ Histopathology revealed malignant melanoma, a nodular type.
- ❑ Immunohistochemical stains were positive for Melan-A and HMB-45. Genetic analysis was negative for BRAF V600, MEK, KIT, NF-1, NRAS mutation.
- ❑ One week later, his initial PET scan revealed 14 x 13 mm metastasis in a left internal iliac chain lymph node and a posterior mesorectal lymph node without evidence of distal metastasis.
- ❑ He was staged as a stage II ARM. After a multidisciplinary conference discussion, the patient was discharged home with a plan of outpatient immunotherapy.
- ❑ He was allowed to recover for eight weeks post-operatively. A repeat PET two months later revealed a new right hepatic lobe lesion, a left mesorectal, and subcutaneous lymph node and several new lung nodules bilaterally
- ❑ He received three cycles of therapy with pembrolizumab. A third PET scan revealed no intra-abdominal nodes and no liver lesions at five months follow up. Mixed response to therapy was noted in the metastatic pulmonary nodules. He currently remains on therapy.

Figures

Endoscopic Finding

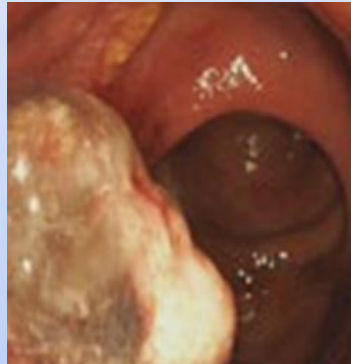

Figure 1: A 14 mm polypoid lesion in the distal rectum. Mass was semi-pedunculated, and oozing was present

Pathology

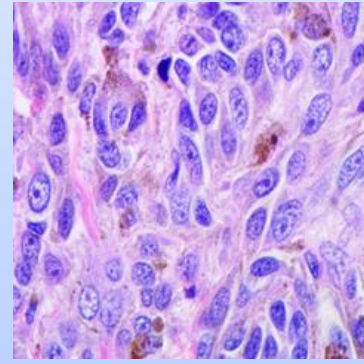


Figure 2A: Biopsy specimen hematoxylin and eosin stain showing an atypical spindle cell proliferation

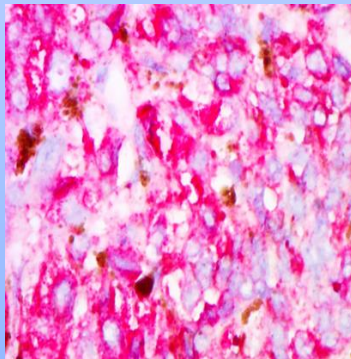


Figure 2B: Positive Immunostaining for HMB 45.

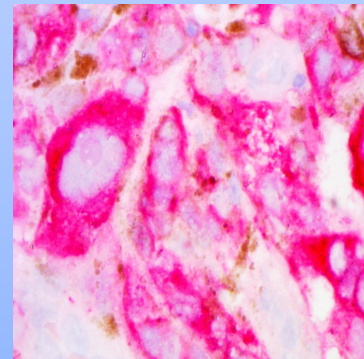


Figure 2C: Immunostaining for Melan A

Discussion

- ❑ Anorectal Mucosal Melanoma is a rare and aggressive malignancy which is poorly described and infrequently studied.
- ❑ The presenting symptoms of ARM are non-specific and may include hematochezia, constipation, perianal pain, and anal soreness.
- ❑ The lesions on examination are usually firm, polypoid, submucosal, lack typical melanoma pigmentation in up to 80%, and are amelanotic in 20-30% of the cases.
- ❑ Histopathology is the gold standard of diagnosis. In difficult cases, immunohistochemistry can support the diagnosis. Immunohistochemical markers may include S-100 protein, Melan A, HMB-45, vimentin, Mart-1 antibodies [2].
- ❑ Therapy for ARM is primarily total surgical resection with a goal of achieving no residual disease [1]. Surgery includes Abdominoperineal resection (APR) and wide local excision.
- ❑ Staging for ARM is clinical, focusing on local, regional, and distant metastasis. Stage I is a local disease. Stage II is local disease with regional lymph nodes. Stage III refers to metastatic disease [1].
- ❑ The prognosis is grim, with a 5-year survival rate for ARM at 20% [4]. Immunotherapy is the best option in ARM as in cutaneous melanoma, but it appears less effective [5].

Conclusion

- ❑ ARM remains a challenge for physicians because of its rarity, unclear pathogenesis, non-specific presentation, and aggressive disease course leading to an inferior prognosis.
- ❑ Increased awareness of ARM and an increased index of suspicion may help improve outcomes by helping to mitigate the high burden of late diagnoses and advanced disease.
- ❑ The threshold for biopsy should be low as the disease frequently masquerades as a benign disease.
- ❑ Robust, consistent reporting of clinical information and increased enrollment in clinical trials are warranted.

Reference

- [1] Singer M, Mutch MG. Anal melanoma. Clin Colon Rectal Surg. 2006 May;19(2):78-87. doi: 10.1055/s-2006-942348. PMID: 20011314; PMCID: PMC2780102.
- [2] Kobakova I, Stoyanov G, Popov H, Spasova-Nyagulova S, Stefanova N, Stoev L, Yanulova N. Anorectal Melanoma - a Histopathological Case Report and a Review of the Literature. Folia Med (Plovdiv). 2018 Dec 1;60(4):641-646. doi: 10.2478/foimed-2018-0040. PMID: 31188769.
- [3] Dadds TJ, Wilmott JS, Jackett LA, Lo SN, Long GV, Thompson JF, Scolyer RA. Primary anorectal melanoma: clinical, immunohistochemistry and DNA analysis of 43 cases. Pathology. 2019 Jan;51(1):39-45. doi: 10.1016/j.pathol.2018.09.060. Epub 2018 Nov 26. PMID: 30497801.
- [4] Meguerditchian AN, Meterisian SH, Dunn KB. Anorectal melanoma: diagnosis and treatment. Dis Colon Rectum. 2011 May;54(5):638-44. doi: 10.1007/DCR.0b013e31820c9e1b. PMID: 21471767.
- [5] Mao L, Qi Z, Zhang L, Guo J, Si L. Immunotherapy in Acral and Mucosal Melanoma: Current Status and Future Directions. Front Immunol. 2021 Jun 4;12:680407. doi: 10.3389/fimmu.2021.680407. PMID: 34149716; PMCID: PMC8212860.



Baton Rouge General

Internal Medicine Residency Program

Arterial thromboembolism: A rare but catastrophic extraintestinal manifestation of ulcerative colitis.

Rameela Mahat MD, Sowbarnika Arivazhagan MD, Guru Prasad Parthiban MD, Karthik Reddy MD

Baton Rouge General Medical Center, Baton Rouge, Louisiana



Introduction

Arterial thromboembolism (AT) is a rare, yet serious extraintestinal manifestation of inflammatory bowel disease (IBD). Patients with IBD who develop AT often have active disease at the time of thromboembolism. Clear guidelines on the initiation and duration of treatment and indication for primary prophylaxis need to be established.

Case Description

- ❑ This is a 48-year-old male with who initially presented to the Gastroenterology office with the complaints of 10-15 loose bloody bowel movements daily with associated abdominal cramps and nausea.
- ❑ Past medical history was significant for ulcerative colitis diagnosed in 2001 and was subsequently treated with Azathioprine for a year followed by Infliximab for another year. Following remission, treatment was discontinued. Except for occasional flares characterized by increased frequency of bowel movements and abdominal cramps, he had been doing overall well in the past 20 years. His disease flare in the past would last for two to three days then resolved spontaneously.
- ❑ He was a non-smoker and drank about 10-12 beers per week. Family history was negative for blood clots, deep vein thrombosis, pulmonary embolism, or another thromboembolism.
- ❑ During his outpatient visit with GI, colonoscopy revealed severe colitis with frank ulceration and friability extending continuously from the anal verge to the mid transverse colon. Pathology confirmed ulcerative colitis. Stool PCR was negative for *Clostridium difficile*. He was started on prednisone and was planned to initiate Adalimumab as an outpatient.
- ❑ Unfortunately, a week later, he was admitted to our hospital with acute pain, weakness, and transient discoloration of his left lower extremity concerning acute limb ischemia.
- ❑ The patient was found to have thrombus in the peroneal and anterior tibial artery. Catheter-directed thrombolysis and heparin anticoagulation were initiated. Despite treatment, he continued to have worsening pain and weakness with no blood flow to his foot requiring amputation below the knee. Hypercoagulability and vasculitis workup was negative.
- ❑ The patient's ulcerative colitis flare up was treated with Intravenous corticosteroid, while in hospital. Following resolution of symptoms, he was discharged home on prednisone with an advice to taper the dose. He was also instructed to follow up with GI outpatient service to start biological therapy for ulcerative colitis. Anticoagulation with rivaroxaban was added following further discussion with vascular surgery and gastroenterology service.

Conclusion

- ❑ Arterial thromboembolism (AT) is a rare, yet serious extraintestinal manifestation of inflammatory bowel disease.
- ❑ Only 20 cases of acute arterial thromboembolism are available in the literature [2].
- ❑ Patients with inflammatory bowel disease (IBD) appear to have a 3-4fold risk of developing thromboembolism (TE) [1]. Active flare of the disease further doubles the risk to eight-fold [1].
- ❑ It has also been found in several literature that thromboembolism in IBD occurs in younger age groups. Mechanism and risk appear to be multifactorial.
- ❑ One of the proposed mechanisms is that active inflammation activates the coagulation cascade and upregulates prothrombotic mediators.
- ❑ Unfortunately, there are no definitive lab markers to identify the patient at risk so that timely intervention could be done.
- ❑ For IBD patients who are hospitalized with moderate-severe flare, anticoagulant prophylaxis is recommended and is associated with reduced risk of TE.
- ❑ Canadian college of gastroenterology guidelines suggest anticoagulant thromboprophylaxis for non-hospitalized patients with moderate-severe flares who has a previous history of TE.
- ❑ However, they recommend against anticoagulant prophylaxis for patient who have not had a previous episode.
- ❑ IBD was counted as one of the strong provoking factors for TE. However, in several studies it was estimated that 32 IBD patients would have to receive anticoagulant prophylaxis during every IBD flare of their life to prevent one episode of VTE, which was found to be non-cost effective [3].

Discussion

From our case, it is imperative to have further studies to initiate thromboprophylaxis and anticoagulation regimens in Ulcerative colitis and more definitive guidelines must be established to prevent such catastrophic event.

Reference

- [1] Goh IY, Saric S, Leschke P, McFarlane M, Jha PK. Thromboembolism in active ulcerative colitis. *BMJ Case Rep.* 2017;2017: bcr2016218608. Published 2017 Jun 20. doi:10.1136/bcr-2016-218608
- [2] O. zizi et al. Embolic lower limb ischemia as a rare complication of Ulcerative colitis. doi:10.1016/j.jm.2016.05.011
- [3] Nguyen GC, Bernstein CN, Bitton A, et al. Consensus statements on the risk, prevention, and treatment of venous thromboembolism in inflammatory bowel disease: Canadian Association of Gastroenterology. *Gastroenterology.* 2014;146(3):835-848.e6. doi: 10.1053/j.gastro.2014.01.042
- [4] Grainge MJ, West J, Card TR. Venous thromboembolism during active disease and remission in inflammatory bowel disease: a cohort study. *Lancet.* 2010;375(9715):657-663. doi:10.1016/S0140-6736(09)61963-2

Introduction

- Acute intermittent porphyria (AIP) is one of four rare inherited porphyrias caused by an autosomal dominant mutation leading to a deficiency in hepatic uroporphobilinogen deaminase (also known as hydroxymethylbilane synthase: HMBS) necessary for heme synthesis.
- It is most common in females of European decent, however 90 percent of patients are asymptomatic.
- Onset is usually acute with a vague presentation of generalized non-specific abdominal pain, nausea, vomiting, constipation, palpitations, confusion, hallucinations, anxiety.
- Frequency and acuity of episodes can vary even among family members as AIP has low penetrance. General triggers can include medications, tobacco use, alcohol, hormones, starvation, and certain foods amongst other internal and external stressors.
- Here we present a case of new-onset AIP in an African-American male.

Case Description

- A 25-year-old African-American male with PMH of Asthma and marijuana use presented with a 2-day history of worsening abdominal pain associated with nausea, non-bloody, non-bilious emesis, and bilateral lower extremity paresthesias.
- He later recalled noticing orange-tinged urine during the initial onset.
- The pain started in the middle of the night, was constant, sharp, and worse at the midline and lower quadrants.
- No prior episodes or significant family history. He denied any other drug, tobacco, or alcohol use, recent illnesses, or travel history.

Physical Exam/Laboratory Data

- On examination patient was tachycardic and hypertensive.
- Abdomen notable for diffuse guarding and tenderness to palpation worse at the umbilicus, left upper and lower quadrant.
- Labs revealed indirect hyperbilirubinemia (total 2.3, indirect 1.6), mild transaminitis (AST 39, ALT 62), and polycythemia (Hgb 19.4, Hct 51.1, Jak2 negative).
- Urine was positive for ketones, urobilinogen and protein. Patient's urine sample from Day 3 is shown below
- CXR, RUQ US, and CT Abdomen and Pelvis with contrast were unremarkable.

Orange-Tinged Urine from Day 3 of Admission



Discussion

- This case highlights the importance of ascertaining a wide differential diagnosis when evaluating patients with non-specific abdominal pain.
- Early recognition of AIP and Hemin administration during an acute attack is crucial for prompt treatment.
- Unless there is high suspicion initially, AIP is usually a diagnosis of exclusion and can easily be misdiagnosed.

Clinical Course

- His pain and intractable nausea remained refractory despite aggressive IV fluid hydration, multimodal-pain control, and utilization of various anti-emetics.
- Urine remained concentrated and orange tinged.
- After multiple etiologies of abdominal pain had been ruled out, including mesenteric ischemia with CT Angiography, an AIP work-up was initiated.
- Meanwhile, he was started on a high-carbohydrate diet with Glucola and a D10 infusion with D50 pushes.
- Urine porphobilinogen (PBG) resulted with elevation >5 times the upper limit of normal (124 umol/L, reference range 0-8.8 umol/L), confirming AIP.
- Hemin was administered for 6 days with improvement in symptoms and resolution of hyperbilirubinemia with plans for outpatient infusions.
- He received 7 additional Hemin infusions in the outpatient setting, with eventual resolution of symptoms after completing a total of 13 session

References

1. Gázquez Sisteré I, Luján Mavila K, Chordá Ribelles J, Touzón López C. La porfiria aguda intermitente, un problema diagnóstico [Acute intermittent porphyria: a diagnostic dilemma]. Gastroenterol Hepatol. 2010 Jun-Jul;33(6):436-9. Spanish. doi: 10.1016/j.gastrohep.2010.02.007. Epub 2010 Jun 24. PMID: 20435380
2. Tollåli G, Nielsen EW, Brekke OL. Akutt intermitterende porfyri [Acute intermittent porphyria]. Tidsskr Nor Lægeforen. 2002 Apr 30;122(11):1102-5. Norwegian. PMID: 12043053
3. Zhao L, Wang X, Zhang X, Liu X, Ma N, Zhang Y, Zhang S. Therapeutic strategies for acute intermittent porphyria. Intractable Rare Dis Res. 2020 Nov;9(4):205-216. doi: 10.5582/irdr.2020.03089. PMID: 33139979; PMCID: PMC7586882

Introduction

- Acute mitral regurgitation with resultant papillary muscle rupture is a medical and surgical emergency.
- Etiologies can include ischemic, nonischemic, or iatrogenic.
- Typical presentations range from acute pulmonary edema to cardiogenic shock to cardiac arrest.
- Roughly 50% of patients have no audible murmur and early in the disease course many patients are misdiagnosed as having an acute pulmonary process.
- Here we present a case of papillary muscle rupture sustained after blunt chest trauma.

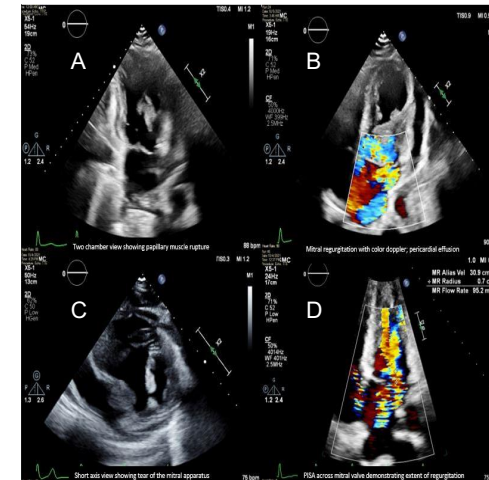
Case Description

- A 35-year-old African-American female with a history of epilepsy presented to the ED after a seizure event resulted in a motor vehicle collision.
- She had no recollection of the incident, was approximately at 8 weeks gestation, and endorsed diffuse, nonspecific anterior chest pain.
- CT chest, abdomen, and pelvis with contrast revealed an intermediate density pericardial effusion and a large hepatic dome hemangioma.
- Transthoracic echocardiogram (TTE) demonstrated preserved left ventricular (LV) systolic function, possible LV thrombus, moderate to severe mitral regurgitation with a posterior directed eccentric jet, and moderate pericardial effusion with early signs of tamponade.

Case Description (Continued)

- The patient remained hemodynamically stable. Initial troponin was 19 mg/mL and ECG showed no signs of ischemia. She was admitted to the ICU. Cardiology and Cardiothoracic surgery were consulted.
- The initial plan involved trending cardiac enzymes and performing serial transthoracic echocardiograms as warranted for hemodynamic changes.
- Ultimately, a transesophageal echocardiogram (TEE) was warranted. However, prior to TEE, the patient developed hypotension, tachycardia, pulmonary edema, and had seizure-like activity.
- She again endorsed diffuse chest pain and telemetry revealed premature ventricular complexes. Soon thereafter, she developed non-sustained ventricular tachycardia.
- Amiodarone was initiated, which temporarily controlled rhythm, but eventually the patient required the addition of lidocaine.
- Repeat TTE revealed worsening mitral regurgitation, posterior papillary muscle rupture at the apical insertion site, and stable moderate pericardial effusion.
- Transfer to a left ventricular assist device capable center was pursued due to the complex nature of this case in the background of pregnancy.
- She was medically managed to prevent further deterioration prior to transfer for surgical intervention.

Echocardiogram Images



- A. Papillary muscle rupture; Two chamber view
- B. MR with color doppler; Pericardial effusion
- C. Tear of mitral apparatus; Short axis view
- D. PISA demonstrating extent of MR

Conclusion

- Papillary muscle rupture is associated with a high operative mortality (~50%) and requires prompt recognition for appropriate management.
- Medical therapy alone without surgery leads to worse outcomes with mortality exceeding 75%.
- Estimated postsurgical 30-day mortality is approximately 25% with predictors including acute MI, shock, LV dysfunction, endocarditis, and coronary disease.
- Delay in treatment or misdiagnosis after cardiac trauma can have catastrophic outcomes.

References

- Watanabe N. Acute mitral regurgitation. *Heart*. 2019;105(9):671-677. doi:10.1136/heartjnl-2018-313373
- Saric P, Ravaee BD, Patel TR, Hoit BD. Acute severe mitral regurgitation after blunt chest trauma. *Echocardiography*. 2018;35(2):272-274. doi:10.1111/echo.13775

Prostate cancer with metastasis to bone marrow leading to cytopenias: a poor prognostic indicator

Ricardo Vallejo-Calzada, MD and Samuel M. Righi, MD
Ochsner Clinic Foundation
New Orleans, Louisiana



INTRODUCTION

Prostate cancer is **the most common non-skin cancer in men** and the **5th leading cause of death worldwide**. It frequently presents with urinary hesitancy, frequency, and nocturia and **commonly metastasizes to bone**. Metastasis to bone marrow is relatively uncommon, however, when it leads to cytopenias, it is considered a poor prognostic indicator.

CASE DESCRIPTION

A 55-year-old male presents to the clinic with **3-months of lower back pain radiating to the thighs**. The pain started abruptly and was not associated with activity. He failed conservative treatment and was referred to neurosurgery, who obtained imaging that revealed **diffuse osseous lesions throughout the appendicular skeleton**. He was referred to oncology, however, presented to the ED with confusion and hallucinations prior to his appointment.

Labwork revealed bicytopenia (**Hgb 4.0 and PLT 17**), hypercalcemia (11.6), and PSA >3,500. Three years prior, his **PSA was 33** and he was scheduled to get a prostate biopsy, however, he was lost to follow up.

Imaging revealed prostatomegaly and findings consistent with bone marrow replacement at the skull. NM bone scan revealed numerous areas of tracer uptake such as the occipital calvarium, ribs, vertebral bodies, and bilateral humeri and femurs.

IMAGING

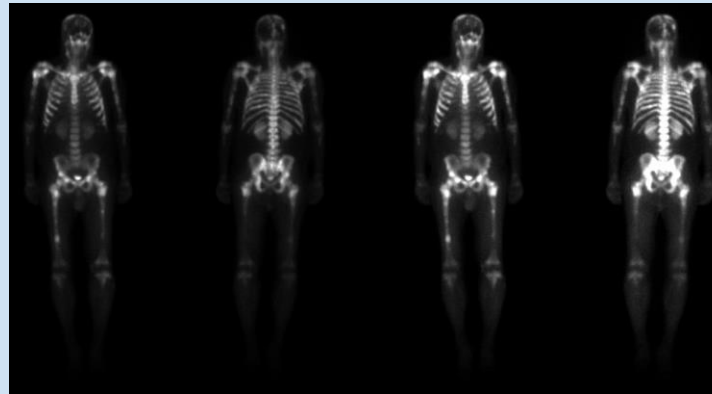


Figure 1: NM whole body scan showing diffuse tracer uptake at occipital calvarium, ribs, vertebral bodies, bilateral humeri and femurs.

CLINICAL COURSE

The patient underwent a **bone marrow biopsy that confirmed prostate carcinoma involvement, though interestingly noted normal trilineage hematopoiesis**. He was started on bicalutamide and discharged with oncology follow up; however, he presented to the ED again with severe sepsis, acute renal failure, and encephalopathy. Labs were remarkable for **pancytopenia (WBC 1.6, Hb 5.2, PLT 31)**. He was admitted to the ICU, however, given his high disease burden and concomitant conditions, hospice was recommended.

DISCUSSION

Prostate carcinoma is commonly associated with lower urinary tract symptoms and an elevated PSA. Given its high propensity to metastasize to bone, lower back pain is a common symptom. The median age of diagnosis is 67, with only 35% of patients diagnosed between the ages of 55 and 64.¹ **The 5-year survival rate for metastatic cases is 30%**, compared to 100% in patients with localized disease.²

Bone marrow infiltration leading to cytopenia is relatively uncommon and considered a poor prognostic indicator.³ Though this patient's bone marrow biopsy noted normal trilineage hematopoiesis, there are **documented cases of medullary aplasia from prostate metastases**.⁴ The presence of cytopenias limits these patients from receiving optimal doses of chemotherapy.⁵ This case highlights an unfortunate and aggressive case of prostate adenocarcinoma and **reiterates the importance of early detection and continuity of care**.

REFERENCES

1. Ahmad A, and Tan W. Atypical Presentation of Prostate Cancer and the Workup of an Adenocarcinoma of Unknown Primary. *World J Oncol*. 2012 Aug;3(4):187-190.
2. Park SH, Keller ET, and Shiozawa Y. Bone Marrow Microenvironment as a Regulator and Therapeutic Target for Prostate Cancer Bone Metastasis. *Calcif Tissue Int*. 2018 Feb;102(2):152-162.
3. Nieder, C., Haukland, E., Pawinski, A. et al. Anaemia and thrombocytopenia in patients with prostate cancer and bone metastases. *BMC Cancer* 10, 284 (2010).
4. Idriss Ziani, et al. "Medullary Aplasia Revealing a Metastatic Prostatic Adenocarcinoma", *Case Reports in Urology*, vol. 2021, Article ID 8898130, 5 pages, 2021.
5. Havva Yeşil Çinkir and Zehra Bozdağ. Prostate Cancer and Bone Marrow Involvement. *Istanbul Med J* 2020; 21(3): 196-9



Baton Rouge General
Internal Medicine Residency Program

A Case of Disseminated AIDS-Related Kaposi Sarcoma Immune Reconstitution Inflammatory Syndrome

Jeremy Polman DO, Chantal Saberian MD, Travis Pressley MD, John Godke MD, Breanna Campbell MD

Baton Rouge General Internal Medicine Residency Program



Baton Rouge General
Internal Medicine Residency Program

Introduction

- Kaposi Sarcoma (KS) is a type of cancer that develops from the cells which line blood and lymphatic vessels.
- These lesions typically appear as painless, purplish on the legs feet or face. However, these lesions can rarely be found in visceral tissues.
- With the introduction of highly active antiretroviral therapy, the prevalence of AIDS related KS has dramatically decreased, both cutaneous and visceral.

Case Description

- A 27-year-old African American male with 13 year history of AIDS, medical noncompliance, and biopsy proven cutaneous KS presented with three week history of worsening right upper quadrant (RUQ) pain.
- CD4 count and HIV viral load were 12 cells/ μ L and $>100,000$ copies/mL three months prior to presentation; he was initiated on bictegravir/emtricitabine/tenofovir alafenamide. Patient also underwent RUQ ultrasound, MRCP, and liver biopsy at an outside facility for RUQ pain, all of which were unremarkable.
- At the time of presentation to our facility, he was a frail appearing male with scleral icterus, diffusely coarse breath sounds, diffuse abdominal tenderness to palpation, and multiple skin lesions consistent with KS. Pertinent laboratory evaluation demonstrated CD4 count 75 cells/ μ L, HIV viral load 70 copies/mL, AST 394 U/L, ALT 250 U/L, ALP 1166 U/L, and total bilirubin 4.5 mg/dL.
- Repeat RUQ ultrasound and MRCP demonstrated cholelithiasis and biliary sludge without biliary ductal dilation. HIDA scan demonstrated hepatic dysfunction and retention of the radiopharmaceutical with no excretion into the bile ducts. Percutaneous cholecystostomy tube was placed. Ongoing clinical and laboratory worsening prompted ERCP, sphincterotomy, and repeat CT abdomen and pelvis.

Figures

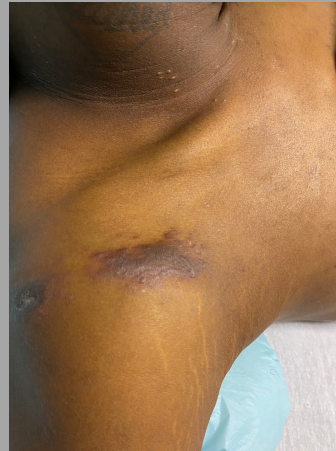

Figure 1: Cutaneous Kaposi Lesion

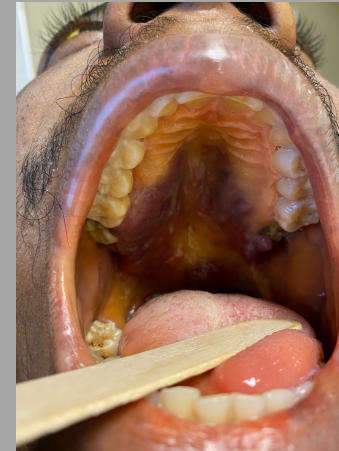

Figure 2: Oral Kaposi Lesion

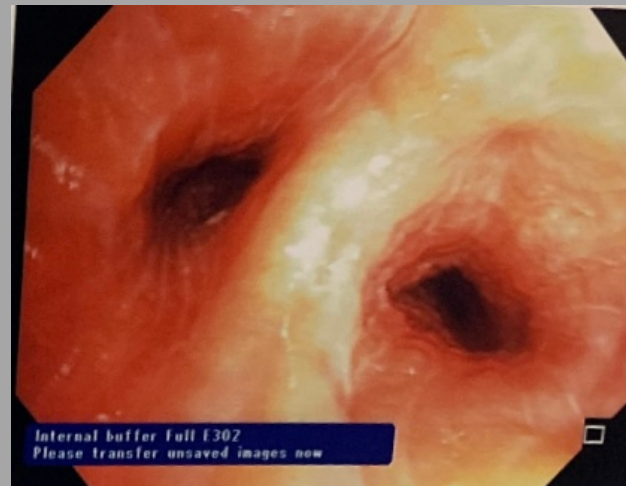

Figure 3: Bronchial Kaposi Lesions

Case Description Continued

- While abdominal pain improved, he developed new cough and dyspnea. Fortunately, the patient's lower lung fields were imaged on the CT demonstrating peribronchial thickening, right pleural effusion, and scattered areas of ground-glass nodularity.
- Bronchoscopy showed diffuse, impressive, patchy mucosal abnormalities with findings worse in the right than the left. Patches were circumferential and characterized by mucosal thickening, intense erythema, cobblestoning, and hyperemia, raising concern for pulmonary Kaposi sarcoma.
- Given patient's constellation of symptoms, patient was diagnosed with visceral Kaposi sarcoma possibly due to immune reconstitution inflammatory syndrome (IRIS).
- After diagnosis, the patient remained hospitalized for initiation of pegylated liposomal doxorubicin in addition to continuation of his ART.
- Unfortunately, the patient remained noncompliant with his therapy and ultimately left the hospital against medical advice.

Conclusion

- Immune reconstitution inflammatory syndrome is a state of hyperinflammatory response that usually occurs in the first six months of treatment of AIDS patients.
- Diagnosis requires the worsening of a recognized or unrecognized preexisting infection in the setting of improving immunologic function.
- Treatment of IRIS typically involves evaluating of the risks and benefits of continuation or discontinuation of antiretroviral therapy.

Introduction

It is quite rare to have Waterhouse-Friderichsen syndrome, but it is especially rare when it is acquired in the absence of bacterial sepsis, i.e fulminant meningococcemia.

However, other causes can include anticoagulants, antiphospholipid syndrome, physiologic stress, tumor metastasis, and postoperative hemorrhage.

This is a case of spontaneous bilateral Waterhouse-Friderichsen syndrome in a post-knee replacement patient on Eliquis.

Case Description

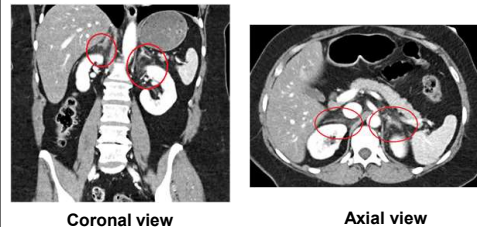
A 59 y/o Caucasian female presented with fevers, hypoglycemia, and hypotension complaining of shortness of breath, nausea, abdominal pain, headache, myalgia, fatigue, and dizziness. Per chart review, the patient recently had left knee replacement approximately 1 week prior to presentation and was placed on Eliquis for DVT prophylaxis.

Two days prior to presentation, she was seen in the ED for RUQ abdominal pain and hyperglycemia. CT abdomen at that time showed minimal non-specific stranding surrounding her adrenal glands.

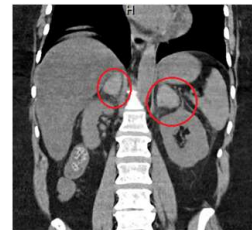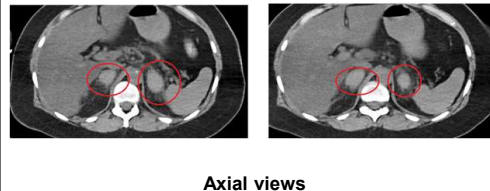
She refused treatment in the ED and was discharged with instructions to return if symptoms worsened.

Imaging

Non-specific stranding (Two days prior)



Left and right adrenal hematomas (current admission)



CT abdomen and pelvis with new bilateral adrenal hematomas. The patient's family denied recent trauma or falls. No abdominal or retroperitoneal bruising was noted on physical exam.

Case Description cont.

Lab	Result (Two days prior)	Results (Current admit)
WBC	19.98	18.12
Lactic Acid	N/A	2.6mmol/L
Platelets	365	91
Creatinine	0.76 mg/dL	1.54mg/dL

****Patient also hyponatremic, hyperkalemic, and hypochloremic consistent with adrenal insufficiency.**

Conclusion

Patient was initiated on IV fluids, vasopressors, and antibiotics for possible septic shock secondary to UTI.

Anticoagulation was held and patient was started on IV hydrocortisone 100mg every eight hours out of concern for adrenal insufficiency secondary to spontaneous adrenal hemorrhages.

Eventually the patient did become more alert and oriented. Antibiotics were discontinued as final blood and urine cultures were negative.

She remained hemodynamically stable and was able to be downgraded from the ICU. She was discharged home on oral hydrocortisone 25mg daily.

In this patient, it was highly suspected that her Eliquis was the culprit of her bilateral adrenal hemorrhages in the absence of trauma or infection.

It is important to be able to recognize that symptoms in these patients are relatively non-specific and can often mimic septic shock. However, with appropriate and timely management, patients often recover – possibly without even requiring long term glucocorticoid and mineralocorticoid replacement.

References

1. Karki, Bhesh R. "Waterhouse-Friderichsen Syndrome." *StatPearls [Internet]*. U.S. National Library of Medicine, 30 July 2021, <https://www.ncbi.nlm.nih.gov/books/NBK551510/>.
2. Pereira, Fatima D. Alves, et al. "Case 268: Bilateral Adrenal Hemorrhage in the Context of Sepsis." *Radiology*, 18 July 2019, <https://pubs.rsna.org/doi/10.1148/radiol.2019170489>.

Quite shocking: dual simultaneous defibrillation in refractory ventricular tachycardia

James Kuo, M.D., Renni Panicker M.D., Julio Rodriguez-Quinones, M.D.
Louisiana State University Health Sciences Center at Ochsner University Hospital & Clinics
Department of Internal Medicine- Lafayette, LA

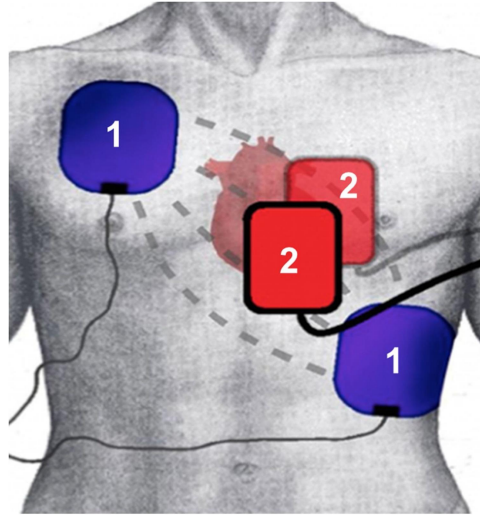
Introduction

- A principle component of cardiopulmonary resuscitation and advanced cardiac life support (ACLS) is early defibrillation
- Standard defibrillation methods in adults use one set of pads in anterolateral positioning ("1" in diagram to the right)
- Dual simultaneous/sequential defibrillation is a technique used where a second set of defibrillator pads are placed in an anteroposterior orientation to give a simultaneous shock ("2" in diagram)
- DSD has been reported to be successful in obtaining return of spontaneous circulation (ROSC) in patients with refractory ventricular fibrillation or tachycardia (RVF/RVT)
- RVF/RVT is defined as ventricular fibrillation or tachycardia (VF/VT) not responsive to defibrillation

Case Description

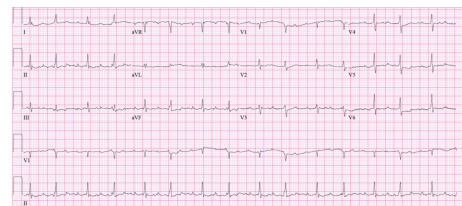
- 81 year old male presented as a direct transfer to the ICU from an outside hospital
- Cardiac comorbidities included paroxysmal atrial fibrillation and sick sinus syndrome with dual-chamber pacemaker
- Intubated prior to arrival for acute hypoxic respiratory failure secondary to severe pulmonary edema
- Upon arrival to the ICU, patient became bradycardic and quickly went into asystole
- CODE BLUE immediately called
- Compressions were started, and patient was given 1 mg of epinephrine, 50 mEq of bicarbonate, and 1 mg of atropine before patient's rhythm converted to polymorphic VT
- One shock was given via standard defibrillation at 200J; patient remained in VT
- Rhythm converted to torsades de pointes necessitating magnesium sulfate administration
- ACLS was continued, with the patient receiving an additional 3 mg of epinephrine, 450 mg of amiodarone, 100 mg of lidocaine, with 2 more standard defibrillations at 200J
- Patient still remained in RVT
- DSD was attempted at 200J, restoring ROSC with a rhythm of sinus tachycardia (ST)

Defibrillator Pad Orientation in DSD



(Cheskes et al.)

Pre-Code Data



Sodium	138
Potassium	4.2
Chloride	104
Bicarbonate	19
BUN	39.7
Creatinine	2.78
Glucose	87
Calcium	9.6
Magnesium	2.6
Phosphorus	5.0

WBC	5.8
Hemoglobin	16.8
Hematocrit	49.5
Platelets	147
PT	48.3
PTT	49.9
INR	5.4
Lactic Acid	5.1

Case Description (cont.)

- Thirty minutes after initial ROSC, CODE BLUE was called again and compressions were initiated
- 50 mEq of bicarbonate, 1 mg of epinephrine, and 1 mg of atropine were given, restoring ROSC with ST. No shocks were required
- Patient was subsequently made DNR by family, and expired that night

Conclusion

- DSD likely played a role in the restoration of spontaneous circulation in our patient
- We cannot say for certain that ROSC was definitively caused by DSD
- Several pre-hospital retroactive studies have been performed comparing DSD with conventional defibrillation with contradictory findings
- One pre-hospital randomized controlled trial conducted in Canada (DOSE-VF Trial, 2020) compared the efficacy of standard defibrillation to vector change defibrillation and DSD in RVF in terminating VF and achieving ROSC
- DOSE-VF found that DSD had increased rate of VF termination and ROSC than standard defibrillation in patients with RVF
- Further investigation must be performed in hospital settings to compare standard defibrillation to DSD in patients with RVF/RVT
- Analysis should also include neurologically intact survival and survival to hospital discharge to compare additional patient-important outcomes following resuscitation with these defibrillation methods

References

- Bunch, T. J., White, R. D., Gerah, B. J., Mevenden, R. A., Hodge, D. O., Ballman, K. V., ... & Packer, D. L. (2003). "Long-term outcomes of out-of-hospital cardiac arrest after successful early defibrillation." *New England Journal of Medicine*, 348(26), 2629-2633.
- Capucco, A., Aschieri, D., Piepoli, M. F., Bardy, G. H., Iconomi, E., & Arvedi, M. (2002). "Tripling survival from sudden cardiac arrest via early defibrillation without traditional education in cardiopulmonary resuscitation." *Circulation*, 106(9), 1065-1070.
- Sheikh, H., Xie, E., & Austin, E. (2018). "Double sequential cardioversion for refractory ventricular tachycardia: A case report." *Canadian Journal of Emergency Medicine*, 20(52), S56-S60.
- El Tawil, C., Mirad, S., & Khashle, B. F. (2017). "Double sequential defibrillation for refractory ventricular fibrillation." *The American journal of emergency medicine*, 35(12), 1985-43.
- Merlin, M. A., Tagore, A., Bauler, R., & Arshad, F. H. (2016). "A case series of double sequence defibrillation." *Prehospital Emergency Care*, 20(4), 550-553.
- Cheskes, S., Wadswold, A., Turner, L., McLeod, S., Summers, J., Morrison, L. J., & Verbeek, P. R. (2019). "The impact of double sequential external defibrillation on termination of refractory ventricular fibrillation during out-of-hospital cardiac arrest." *Resuscitation*, 139, 275-281.
- Ross, E. M., Redman, T. T., Harper, S. A., Mapp, J. G., Wampler, D. A., & Miramontes, D. A. (2016). "Dual defibrillation in out-of-hospital cardiac arrest: a retrospective cohort analysis." *Resuscitation*, 106, 14-17.
- Mapp, J. G., Hans, A. J., Darrington, A. M., Ross, E. M., Ho, C. C., Miramontes, D. A., ... & Prehospital Research and Innovation in Military and Expeditionary Environments (PRIME) Research Group. (2019). "Prehospital double sequential defibrillation: a matched case-control study." *Academic Emergency Medicine*, 26(9), 994-1001.
- Cheskes, S., Doran, P., Feldman, M., McLeod, S., Scalea, D. C., Pinto, R., ... & Verbeek, P. R. (2020). "Double sequential external defibrillation for refractory ventricular fibrillation: the DOSE VF pilot randomized controlled trial." *Resuscitation*, 150, 178-184.

A-DRESS-ing Rash in T-Cell Lymphoma Patient with Recent Chemotherapy

Besim Ademi, MD, Erica Mascarenhas, MD and J. Luke Taggart, MD

Introduction

Drug reaction induced with eosinophilia and systemic symptoms (DRESS) can be a life-threatening condition requiring prompt recognition and treatment. It is precipitated by an offending agent, often sulfonamide-containing antibiotics, specific anticonvulsants as well as anti-epileptics. After exposure to the drug, a T-cell mediated hypersensitivity reaction causes the presenting symptoms. The exact pathogenesis is not well understood. However, certain genetic factors, such as HLA and cytochrome metabolizing enzyme subtypes, are thought to predispose patients to developing DRESS.

Though the precise incidence is unknown, it is estimated that DRESS occurs in 1 of every 10,000 drug interactions and accounts for up to 20% of all cutaneous drug reactions.

Here we report a case of a widespread rash in the setting of antibiotic use and T cell lymphoma. There were further concerning systemic features in the case making a correct diagnosis and treatment paramount in the care of the patient

Images

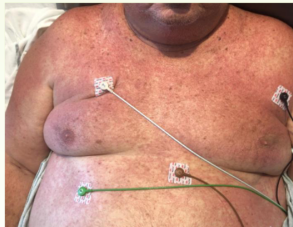

Figure 1. Early stages of cutaneous, pruritic rash. Initially began on extremities, progressing to trunk and back. Following this stage, rash became deeply reddened before starting to resolve

Case Presentation

A 64-year-old gentleman with T-cell lymphoma was admitted to the hospital for recurrent fever, rigors and generalized fatigue. He has had multiple previous presentations over the preceding 3 weeks for the same complaints and had been treated with extended courses of empiric broad spectrum antibiotics. No infection was identified or associated with these episodes.

During the current hospital course, a CT scan of the neck was significant for an abscess at an excisional lymph node biopsy site at the right neck, which was subsequently drained. Blood cultures, cytomegalovirus testing, giardia, cryptococcal and Clostridium difficile testing all returned negative. An infection was suspected to be the culprit of the patient's uncontrolled rigors, generalized pain and fever. He was placed on broad spectrum antibiotics of vancomycin and piperacillin/tazobactam.

The patient then developed diffuse pruritic erythematous macules that began at his upper extremities then progressed to the rest of his body. These physical exam changes were accompanied with an elevated white blood cell count of 27,400 u/L, absolute neutrophil count of 18.63 and absolute eosinophil count of 4.66. Absolute lymphocyte count remained within normal limits.

After initial recognition of the rash, the antibiotic regimen changed to monotherapy with ciprofloxacin. In the immediate days following the switch, the white blood cell count rose to 32,300. The absolute eosinophil count peaked at 14.54. Absolute neutrophil count decreased to 13.89 at that time. Equally as important, the rash further progressed in its covered area of the body and deepened discoloration of the skin. In spite of these objective findings, the patient had clinical improvement of pruritic symptoms and discomfort. At no point did he develop mucosal physical changes, other system symptoms or evidence of unstable vitals.

A punch skin biopsy was performed and revealed perivascular infiltrate of lymphocytes, eosinophils, neutrophils and histiocytes accompanied by vascular dilation and dermal edema. A diagnosis of drug eruption was confirmed through biopsy with piperacillin/tazobactam being the suspected underlying offending agent. The rash slowly cleared over five to seven days and resolved by the time of the next round of chemotherapy.

Discussion

The abrupt onset of diffuse erythematous rash in the setting of acute eosinophilia should raise concern for DRESS, a life-threatening drug induced hypersensitivity reaction. DRESS is characterized as a cutaneous eruption with eosinophilia, fever, lymphadenopathy and other visceral organ involvement. Complications include severe organ dysfunction such as liver injury, interstitial nephritis and interstitial pneumonia. In DRESS, it is common that a reaction begins two to eight weeks after initiation of the causative drug. Treatment involves high dose oral steroids which are slowly tapered over a course of 8 to 12 weeks.

In the evaluation of this patient, significant consideration was given to initiating steroids. The rise in eosinophils and diffuse, widespread rash could not exclude DRESS from the differential. Diagnosis through punch skin biopsy was not available during the immediate days following the start of the rash. During that unknown time, objective lab values and physical exam findings worsened following the switch of antibiotics. Sezary syndrome, drug eruption and progression of lymphoma were also considered. However, given the lack of liver or kidney injury, hemodynamic stability and subjective improvement of symptoms, the decision was made to defer starting steroids treatment in this case. Potential side effects risks of administering steroids in the setting of recent chemotherapy and immunosuppression also played a large role in the decision to withhold DRESS treatment.

Lastly, on a more comprehensive chart review of the patient, he had received multiple short courses of vancomycin and piperacillin-tazobactam 3-6 weeks prior to presentation. Upon further investigation, he had a similar yet less intense drug reaction during one of these previous courses of antibiotics. This further guided and supported the clinical decision to hold steroids. The final deciding factor was the skin biopsy showing likely drug eruption. Ultimately, his symptoms resolved with the removal of potential offending agents while being closely monitored and having a low threshold to start oral glucocorticoids.



Baton Rouge General
Internal Medicine Residency Program

An Extreme Case of MRSA Necrotizing Pneumonia with Near Total Destruction of the Lung

Jeremy Polman DO, Jennifer Miatech MD, John Godke MD

Baton Rouge General Internal Medicine Residency Program



Baton Rouge General
Internal Medicine Residency Program

Introduction

- Methicillin-resistant *Staphylococcus aureus* (MRSA) is the leading cause of hospital acquired pneumonia.
- MRSA pneumonia can also be seen in patients with MRSA bacteremia or MRSA endocarditis, which are classically seen in patients with intravenous drug use disorder.
- Here, we present an interesting case of a mildly symptomatic IV drug user who has MRSA necrotizing pneumonia and his subsequent treatment course.

Case Description

- A 42 year old male with a past medical history of intravenous drug use disorder, prolonged incarceration, and hepatitis C presented with a 3 week history of productive cough, dyspnea, fever, chills, and generalized weakness.
- He originally noticed intermittent, nonspecific pleuritic chest discomfort for 3 months. Upon presentation to the emergency department, patient appeared to be dyspneic and uncomfortable, but had appropriate oxygen saturation on room air.
- Physical exam revealed absent lung sounds diffusely on the right. A portable chest xray demonstrated moderate alveolar consolidation scattered throughout the right lung, opacification of the base of the right hemithorax, and a 4.4 centimeter area of radiolucency in the midportion of the right hemithorax [Figure 1].
- CT chest was then obtained, which demonstrated minimal normal appearing pulmonary tissue in the right lung, multiple areas of alveolar consolidation, and many air/fluid collections scattered throughout the right lung and right hemithorax. There was also a right sided tension hydropneumothorax, shifting the mediastinum to the left, which was believed to be secondary to a 14.4 centimeter cavitary lesion [Figure 2].

Figures

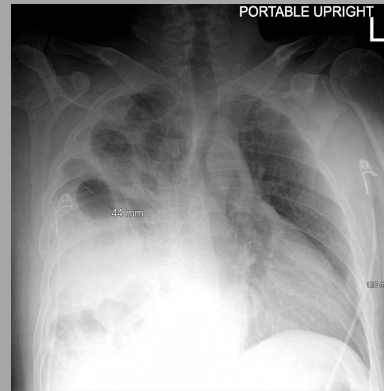


Figure 1: Admission portable chest xray

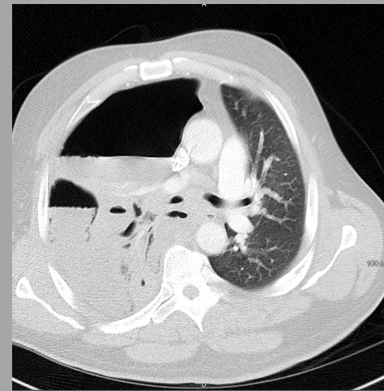


Figure 2: Admission CT chest

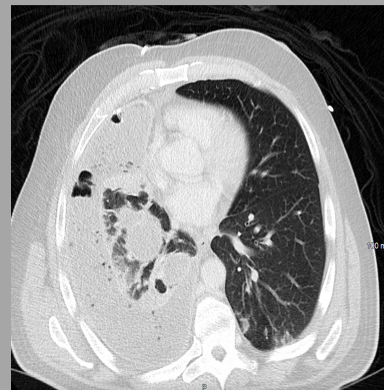

Figure 3: Hospital day 7 CT chest after receiving right sided pleural drain and IV antibiotics

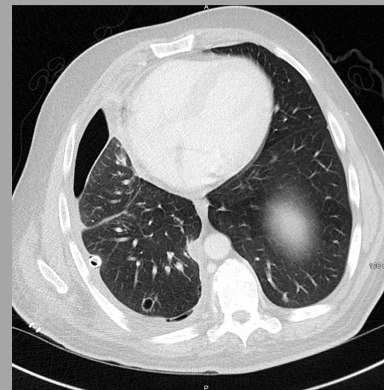


Figure 4: Hospital day 15 CT chest after right thoracotomy with complete decortication and placement of 2 large bore chest tubes

Case Description Continued

- A pneumonia panel obtained during admission demonstrated methicillin resistant *staphylococcus aureus*, *streptococcus agalactiae*, *streptococcus pneumoniae*, and *haemophilus influenzae*.
- The patient was admitted with the working diagnosis of necrotizing MRSA pneumonia with multiple abscesses, complex empyema, and tension hydropneumothorax.
- Blood cultures and acid fast bacilli staining were negative. Patient was initiated on broad spectrum antibiotic therapy with linezolid and ampicillin-sulbactam.
- A right sided pleural drain was placed to obtain sample of the effusion as well as alleviate tension hydropneumothorax while further evaluation of underlying pathology was completed. Repeat imaging after placement of pleural drain and initiation of antibiotic therapy demonstrated significant radiologic improvement [Figure 3].
- Given patient's improvement, total right pneumonectomy was avoided and patient underwent right thoracotomy with complete decortication and placement of two large bore chest tubes on hospital day 14.
- Post-operatively, patient had continued bronchopleural fistula demonstrated by continued air leak seen in patient's chest tube atrium. Patient remains hospitalized with plans to place Heimlich valve over patient's chest tube and continued antibiotic therapy.

Conclusion

Although rare, some patients with severe MRSA necrotizing pneumonia may present with relatively mild symptoms. A high index of clinical suspicion is needed in patients with a past medical history concerning for possible MRSA exposure, which includes intravenous drug use disorder.

Hypertensive Emergency in Heart Failure – Substandard Care or Outdated Guidelines?

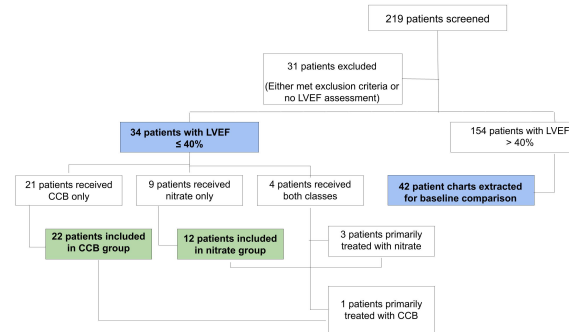
Jake Smith, MD, Madison Lanza, Barret Murphy, MD, Diana Hamer, PhD, Angela Johnson, MD
Department of Internal Medicine, Louisiana State University Health Sciences Center – Baton Rouge

Introduction

- Hypertensive emergency is marked by significantly elevated systemic blood pressures and resultant end-organ damage.
- Widely used pharmacologic classes in this syndrome are calcium channel-blockers (CCB), nitrates, and beta-blockers.
- Current guidelines offer little on optimal pharmacologic agents in patients with heart failure presenting with hypertensive emergency.
- The ACC/AHA advises avoidance of CCBs in patients with HFrEF, and recommends using nitroprusside and nitroglycerin.

Methods

- We compared adult patients with a primary diagnosis of hypertensive emergency (ICD-10: I16.1) presenting to a tertiary hospital's ED who received parenteral CCBs to those who received nitrates between March 2017 – December 2018.
- A retrospective chart review of demographic characteristics, clinical course and outcomes data was conducted.
- Patients were stratified according to left ventricular ejection fraction (LVEF) as 'reduced' (LVEF \leq 40%) or 'preserved' (EF > 40%).
- We used Chi-square test and Mann-Whitney U-test to compare patients in both groups



Results

Statistically Relevant Results			
	EF < 40% (n = 34)	EF > 40% (n = 42)	p-value
Baseline Characteristics			
Demographics			
Age – years	49.5 (38-57)	63 (49.5-71)	0.003
Male – no. (%)	24 (70.6)	16 (38.1)	0.006
African American – no. (%)	31 (91.2)	28 (66.7)	0.013
Past Medical History – no. (%)			
Heart Failure	31 (91.2)	20 (47.6)	<0.001
Presenting Symptoms – no. (%)			
Dyspnea	25 (73.5)	15 (35.7)	0.001
End Organ Damage – no. (%)			
Decompensated heart failure	24 (70.6)	12 (28.6)	<0.001
Radiographic Pulmonary Edema – no. (%)	21 (61.8)	10 (23.8)	0.001
Parenteral Antihypertensives Administered			
Calcium channel blockers only – no. (%)	21 (61.8)	36 (85.7)	<0.05
Nitrates only – no. (%)	9 (26.5)	1 (2.4)	<0.05
Other parenteral antihypertensives used – no. (%)	19 (55.9)	34 (81)	0.024

Statistically Relevant Results			
	CCB (n = 22)	Nitrate (n = 12)	p-value
Presenting Symptoms – no. (%)			
Dyspnea	13 (59.1)	12 (100)	0.013
End Organ Damage – no. (%)			
Decompensated heart failure	12 (54.4)	12 (100)	0.006
Radiographic Pulmonary Edema – no. (%)	11 (50)	10 (83.3)	0.075
Cardiology consultation	5 (22.7)	7 (58.3)	0.062

- In patients with HFrEF compared to HFpEF, there was no difference in:
 - Hospital or 30-day mortality
 - Hospital length of stay
 - ICU length of stay
 - 30-day readmission
- In patients with HFrEF, those that received CCB compared to nitrates, there was no difference in :
 - 30-day mortality
 - ICU length of stay
 - Hospital Stay
 - Readmission at 30 days

Conclusions

- This study suggests the use of parenteral CCBs in patients with hypertensive emergency and clinical heart failure, including those with reduced LVEF, results in similar outcomes when compared to the guideline-standard nitrate therapy.
- More research is needed on safety and efficacy of this class of drugs to inform updates to guideline-based care.

References

- Yancy et al. 2013 ACCF/AHA Heart Failure Guideline: Full Text. *JACC* 2013; 62(16):e147-239.
- Peacock et al. Clevidipine for Severe Hypertension in Acute Heart Failure: A VELOCITY Trial Analysis. *Congestive Heart Failure* 2010; 16(2): 55-9.
- Peacock et al. Clevidipine in acute heart failure: Results of the A Study of Blood Pressure Control in Acute Heart Failure—A Pilot Study (PRONTO). *American Heart Journal* 2014; 167:529-36.
- Wakai et al. Nitrates for Acute Heart Failure Syndromes. *The Cochrane Database of Systematic Reviews* 2013(8): 1-31. doi: 10.1002/14651858.CD005151.pub2.

Acute Pancreatitis in the setting of Newly Diagnosed Type II Diabetes Mellitus

Erica Mascarenhas MD, Jerald Taggart MD

Department of Internal Medicine, Tulane University School of Medicine, New Orleans, LA



TULANE UNIVERSITY
SCHOOL of MEDICINE

Case Presentation

- A 43-year-old man with binge alcohol use disorder and obesity presented to the ED with three days of abdominal pain, nausea, vomiting and decreased oral intake.
- The sharp epigastric and RLQ pain began acutely, worsened with movement, and was not controlled by pain medications.
- Last alcoholic beverage was 5 days prior to admission.
- Vital signs were stable and laboratory results significant for blood glucose 369 mg/dL, HCO₃ 9 mmol/L, anion gap 20, hemoglobin A1c 14.3%. WBC 31, and lipase of 217 U/L.
- CT abdomen showed significant pancreatic head and body enlargement with adjacent inflammatory changes and 7.5 cm peripancreatic fluid collection (Figure A and B).
- Abdominal ultrasound revealed hepatomegaly, hepatic steatosis, cholelithiasis and a markedly dilated common bile duct to 13 mm. No stones were seen in the common duct.

References

Berglund L, Brunzell J, Goldberg A, Goldberg I, Sacks F, Murad MH, Stallenhoef A, Endocrine society. Evaluation and treatment of hypertriglyceridemia: an Endocrine Society clinical practice guideline. *J Clin Endocrinol Metab*. 2012 Sep;97(9):2969-89. DOI: 10.1210/jc.2011-3213

Nair S, Yadav D, Pitchumoni CS. Association of diabetic ketoacidosis and acute pancreatitis: observations in 100 consecutive episodes of DKA. *Am J Gastroenterol*. 2000;95(10):2795. DOI:10.1111/j.1572-0241.2000.03188.x

Navina S, Acharya C, DeLany J, Orlichenko C, et al. Lipotoxicity causes multisystem organ failure and exacerbates acute pancreatitis in obesity. *Sci Transl Med*. 2011 Nov 2;3(107):107ra110. doi:10.1126/scitranslmed.3002573.

Scherer J, Singh V, Pitchumoni CS, Yadav D. Issues in hypertriglyceridemic pancreatitis: an update. *J Clin Gastroenterol*. 2014 Mar;48(d):195-203. DOI:10.1097/01.mcj.0000436438.60145.5a

Tamez-Perez H, Saenz-Gallegos R, Hernandez-Rodriguez K, et al. Insulin Therapy in patients with severe hypertriglyceridemia. *Rev Med Inst Mex Seguro Soc*. May-Jun 2006;44(3):235-7.

Hypertriglyceridemia Induced Pancreatitis

Why is it important?

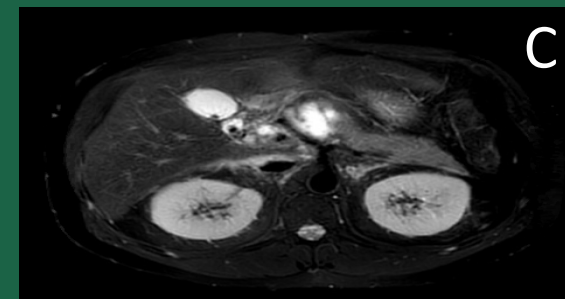
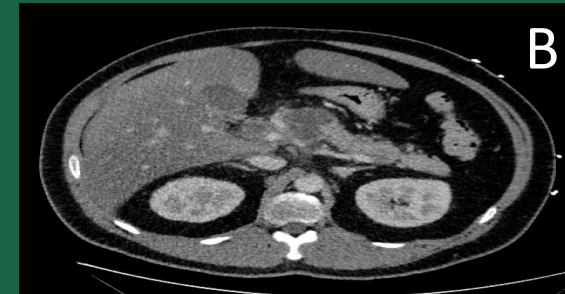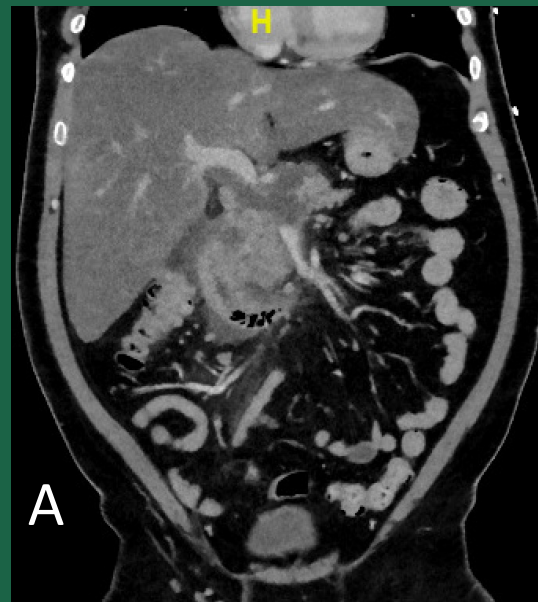- Hypertriglyceridemia as a cause of pancreatitis can be induced by many metabolic derangements including DKA and medications
- A low insulin state causes lipolysis of adipose tissue leading to the release of free fatty acids and the subsequent biosynthesis of triglycerides
- The high influx of triglycerides causes pancreatic lipases to degrade the triglycerides into toxic free fatty acids leading to inflammation of the pancreas

Diagnosis

- For triglyceridemia to cause pancreatitis, triglycerides need to be greater than 1000 g/dL.
- Higher levels correlate with a higher likelihood of developing pancreatitis and a more severe presentation

Treatment

- IV regular insulin at 0.1 to 0.3 units/kg/hour or apheresis until triglyceride levels are less than 500 mg/dL.
- Decrease dietary fat and alcohol
- Start on lipid-lowering pharmacologic agents such as fibrates



Hospital Course

- Patient was initially admitted to the ICU for his diabetic ketoacidosis in the setting of newly diagnosed diabetes mellitus.
- Insulin drip, pain control and IV fluids resulted in clinical improvement.
- MRCP had no biliary obstruction but showed a 3 cm peripancreatic fluid collection. (Figure C)
- Initial common bile duct dilation attributed to pancreatic head enlargement
- Given abdominal US and MRCP, other etiologies of pancreatitis were pursued and patient's triglycerides were found to be 1200 mg/dL.
- His insulin regimen was adjusted to glargine 30 units twice daily and pre-prandial lispro 12 units which he was discharged on.
- With insulin and atorvastatin, his triglycerides down-trended to 400 mg/dL.

Post Hospital Follow Up

- At 2-week hospital follow-up, the patient endorsed frequent hypoglycemic episodes and regimen changed to glargine 10 units nightly and lispro 3 units with meals.
- At 2-month follow-up, patient had weight loss with diet and exercise so lispro was stopped.
- Repeat MRI showed resolution of peripancreatic collection.
- At 3-month follow-up, patient's hemoglobin A1c was 5.3% so glargine was stopped and patient currently only on metformin.

COVID-19 Infection in a Patient with Sickle Cell SC Disease

Besim Ademi, MD, Joshua Dickerson, BA and J. Luke Taggart, MD

Introduction

Sickle cell disease is a genetic condition caused by a point mutation in the β -globin chain of hemoglobin. Affected red blood cells are prone to distortion in hypoxic conditions, often precipitating vaso-occlusive pain (VOC) episodes. The disease significantly lowers life expectancy as patients are chronically immunocompromised and at a higher risk for infections and complications such as acute chest syndrome [1]. Multiple variations of sickle cell disease are also possible. Although the most common genotype is sickle cell SS (HbSS) disease, separate point mutations can lead to heterozygous sickle cell SC (HbSC) disease. Generally, HbSC patients have less frequent VOC episodes, but have a higher predisposition and incidence of proliferative retinopathy, pulmonary embolism and sensorineural otological disorders [2-3]. This is thought to be secondary to HbC enhancing the formation of HbS by dehydrating red blood cells [2].

With the emergence of SARS-CoV-2 (COVID-19), limited data exist on the implications, prognosis and hospital course in patients with a sickle cell disease co-morbidity. COVID-19 creates an enhanced inflammatory state and can present with a wide consolidation of symptoms, most commonly dyspnea, cough, shortness of breath, fever and myalgias [4]. Hospitalized patients and those requiring intensive care unit admission often have significant co-morbidities such as hypertension, diabetes and obesity [5]. Given the often fatal and severe status of hypoxic respiratory failure in those infected with COVID-19, sickle cell disease could exacerbate or predispose towards a critical prognosis. Here, we report a case of successful treatment of COVID-19 in a HbSC patient complicated by hypoxic respiratory failure.

Images

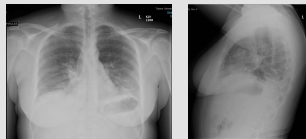


Figure 1. PA (left) and lateral (right) chest X-ray on the day of admission. Patchy mid to lower opacities observed with developing airspace disease.

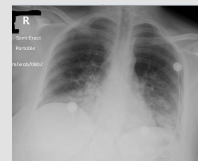

Figure 2. Portable AP chest X-ray prior to discharge on hospital day 9. Still with patchy opacities though significantly improved compared to initial CXR.

Case Presentation

A 33 year old woman with sickle cell SC disease (HbSC) was admitted to the hospital for respiratory support after testing positive for COVID-19. Four days prior to presentation, the patient developed shortness of breath, concomitant substernal non-radiating chest pain, thigh pain, back pain, subjective fever and cough. Her medical history included prior vaso-occlusive episodes, though no history of acute chest syndrome. She reported compliance with prophylactic folic acid, penicillin and as needed hydrocodone. Physical exam was significant for crackles with rhonchi. There was no tenderness to palpation over the chest wall or extremities and neurologic examination was intact without any focal findings. Her vitals were within normal limits and the patient was afebrile. Her COVID labs were as follows. LDH of 392 U/L, c-reactive protein of 2.88 mg/dL, troponin negative and less than 0.015 ng/mL, ferritin of 1167.8 ng/mL, d-dimer less than 2 mg/L and procalcitonin of 0.28 ng/mL. The initial chest X-ray demonstrated patchy mid to lower lung opacities bilaterally (Figure 1). The imaging as well as the new onset chest pain were concerning for potential acute chest syndrome and empiric azithromycin and ceftriaxone were initiated. She was also started on anticoagulation with Lovenox and opioid pain control for a potential vaso-occlusive episode though there was minimal sickling on peripheral blood smear. Likewise, her reticulocyte percentage was 1.5%, total bilirubin was 1.9 mg/dL and hemoglobin was decreased to 10 g/dL from a baseline of 12 g/dL.

At first, the patient did not require oxygen supplementation and had an SpO₂ of 95 on room air. However, she developed an isolated fever of 103.0°F on the third day of admission and subsequently required oxygen supplementation of 3L on nasal cannula on the fourth day. Repeat labs drawn at that time were significant for an elevated d-dimer of 4.06 mg/L and a persistently elevated ferritin of 971 ng/mL. Blood cultures from admission showed no growth, though sputum cultures showed moderate polymorphonuclear leukocytes and gram negative rods. Empiric antibiotics were continued and there were no changes to her medication regimen through hospital day 5. On hospital day 6, the patient was placed on dexamethasone as she still demonstrated shortness of breath, required 2L oxygen and had a fever during admission. Her repeat d-dimer and ferritin on day 7 were 2.59 mg/L and 784 ng/mL, respectively. The patient then clinically improved and on the 9th day was weaned off oxygen supplementation with improvement of back, chest and thigh pain. Her chest X-ray prior to discharge showed remarkable improvement (Figure 2). Dexamethasone was discontinued and the patient was discharged from the hospital. Overall, the course was relatively mild with minimal complications and no signs of impending critical status.

Discussion

In the early stages of the COVID-19 pandemic, sickle cell patients were placed in a high risk category for developing complications from the virus. In sickle cell patients, an abnormally high, chronic background inflammatory state of IL-6 already exists and VOC episodes further exacerbate inflammation. The concern is that a systemic imbalance could contribute to worse outcomes.

A second potential issue that led to increased concern for the sickle cell population is that these patients are in a chronic immunocompromised state. Even with prophylactic antibiotics administered throughout their lives, many are prone to a multitude of infections and can develop functional asplenia or other severe complications like acute chest syndrome.

However, as in our patient's case, the majority of sickle cell cases paradoxically have consistently better outcomes. In the general population, severe symptoms from COVID were reported in 14 percent of the population with an overall case fatality rate of 2.3%. a report from the Chinese Center for Disease Control and Prevention, roughly 81 percent of patients had mild symptoms. Severe symptoms were reported in 14 percent with an overall case fatality rate of 2.3%. In another study following 2741 strictly hospitalized patients in New York City, 24% of the patients died or were discharged to hospice. Between 20 and 40% of hospitalized patients with severe disease developed acute respiratory distress syndrome. For those with sickle cell, a limited review of current case reports and case series of COVID infections showed only 5 of 146 (3.4%) deaths with limited numbers of patients requiring intense respiratory intervention. The majority of cases were mild and successfully treated. This is in alignment with our patient's case, who had a relatively uncomplicated hospital course with eventual discharge. Though a limited sample size, these data serve as an early indication that sickle cell disease patients may have an overall decreased mortality rate compared to the general population.

A confounding variable in this analysis could be the average presenting age of sickle cell patients is much younger than other hospitalized ones. In further evaluation of other chronic immunosuppression diseases, better outcomes are not limited to sickle cell. Patients on chronic immunosuppression therapy, whether for multiple sclerosis, Crohn's disease or ulcerative colitis, while also younger in age, have also shown to have a more favorable prognosis. More research and data must be performed to explore the role of immunosuppression and inflammation in the prognosis and course of infections.

A Curious Case of the “Pox” Stroke

Renni R. Panicker, MD; Hirrah Sajjad, MD; Anjali Ajit, MD;
Jasmeet Kaur Khara, DO; Saifullah Shahid, MD; Nicholas Sells, MD
Louisiana State University Health Sciences Center at Ochsner University Hospital & Clinics
Department of Internal Medicine- Lafayette, LA

Introduction

- Varicella zoster virus (VZV) infects more than 95% of the U.S. population.
- Typically, varicella (chickenpox) results from a primary infection. The virus then remains latent in the cranial nerve, dorsal root, and autonomic ganglionic neurons.
- There has been an increasing incidence of strokes caused by reactivation of VZV in both immunocompetent and immunocompromised hosts.
- Recent studies have emerged which reveal that VZV infection of the cerebral arteries directly causes pathological vascular remodeling and stroke (VZV vasculopathy).
- There is a growing consensus of treating VZV stroke as small/large vessel vasculitis.

Case Description cont.

- He was treated with intravenous (IV) acyclovir 800 mg, three times a day (TID) for fourteen days and afterwards discharged from the outlying facility.
- MRI Brain with and without contrast on this admission revealed remote left pontine infarct and new acute infarct at the same distribution of the left pontine region.
- Infectious Disease and Neurology services were consulted. Neurology recommended treating as a primary small vessel vasculitis with Methylprednisolone 1000 mg for five days without a taper.
- Infectious Disease recommended acyclovir 800 mg TID as inpatient with an additional 14 days on discharge.
- He had significant improvement in his right sided weakness following treatment and was discharged to inpatient rehab for further physical therapy and outpatient follow up with ophthalmology for his HZO.

Conclusion

- VZV vasculopathy is a potentially treatable cause of vascular disease and should be suspected in patients with acute VZV infection and symptoms of stroke and TIA.
- Confirmatory testing is made by demonstrating anti-VZV IgG antibodies and VZV DNA in CSF. Testing for anti-VZV IgG antibody in CSF generally has a higher yield than VZV DNA.
- Several meta-analysis showed stroke risk is significantly increased shortly after acute zoster infection and remains elevated for up to one year.
- Herpes zoster ophthalmicus and zoster with trigeminal involvement were associated with a greater than two fold increase in stroke risk.
- There is a growing consensus that VZV stroke can present as a small/large vessel vasculitis which necessitates treatment with pulse dose steroids and that treatment with antivirals alone may not be enough.

Case Description

- A 60-year-old man with history of uncontrolled diabetes, hypertension, and Herpes Zoster Ophthalmicus (HZO) presented with right sided weakness.
- He was initially diagnosed with HZO six months prior and was treated with oral acyclovir- 800mg, five times a day for seven days.
- During his current admission, his main deficits included right sided upper and lower extremity weakness along with right sided facial drooping.
- Vital signs on admission were significant only for a blood pressure of 147/87 mmHg. Labs were unremarkable for any acute pathology.
- Contrast tomography (CT) of the head and CT angiography of the head and neck did not reveal any acute intracranial abnormality or large vessel occlusion.
- Of note, he was hospitalized two weeks prior to his current presentation at an outlying facility with similar symptoms.
- Magnetic resonance imaging (MRI) of brain at the outlying facility demonstrated a left pontine ischemic stroke, and a lumbar puncture was positive for VZV IgG in the cerebrospinal fluid (CSF).

Imaging

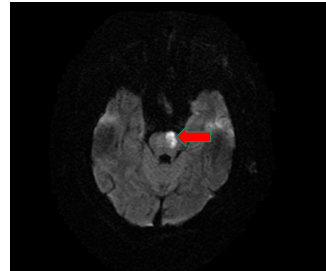


Image 1. MRI Brain – (Diffusion weighted imaging) showing left pontine acute/subacute infarct

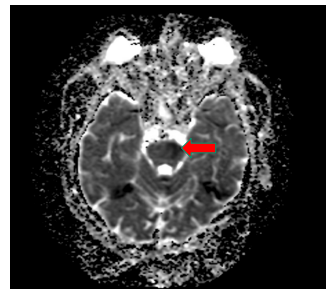


Image 2. MRI Brain –(ADC) showing left pontine acute/subacute infarct

References

- Nagel, Maria, Don Gilden. The Relationship Between Herpes Zoster and Stroke. Current Neurology and Neuroscience Reports. February 25, 2015. <https://link.springer.com/article/10.1007%2Fs11910-015-0534-4>
- Marra, Fawziah, Jeremy Ruckenstein & Kathryn Richardson. A meta-analysis of stroke risk following herpes zoster infection. BMC Infectious Diseases. March 2017. <https://bmcinfectdis.biomedcentral.com/articles/10.1186/s12879-017-2278-z#auth-Fawziah-Marra>
- Yang, Sheng-Ye, Hong-Xing Li, Xin Hao Yi, et al. “Risk of Stroke in Patients with Herpes Zoster: A Systematic Review and Meta-Analysis. .” Journal of Stroke and Cerebrovascular Diseases, 31 Oct. 2016, [https://www.strokejournal.org/article/S1052-3057\(16\)30350-0/fulltext](https://www.strokejournal.org/article/S1052-3057(16)30350-0/fulltext).
- Nagel, Maria, Andrew N Bubak. Varicella Zoster Virus Vasculopathy. The Journal of Infectious Diseases, Volume 218, Issue 1 November 2018. <https://doi.org/10.1093/infdis/jiy425>
- Powell, David, Shiddhi Patel, Carlos Franco-Paredes. Varicella-Zoster Virus Vasculopathy: The Growing Association Between Herpes Zoster and Strokes. The American Journal of the Medical Sciences. September 2014. https://www.researchgate.net/publication/265559750_Varicella-Zoster_Virus_Vasculopathy_The_Growing_Association_Between_Herpes_Zoster_and_Strokes

To “Band” or not to “Band”, That is the Question!

Renni Panicker, MD; Anjali Ajit, MD; Jasmeet Kaur Khara, DO; James Kuo, MD; Melanie Bienvenu, MD
Louisiana State University Health Sciences Center at Ochsner University Hospital & Clinics
Department of Internal Medicine- Lafayette, LA

Introduction

- Laparoscopic adjustable gastric banding (LAGB) is a bariatric procedure for management of severe obesity whereby a tight, adjustable prosthetic band is placed around the entrance to the stomach.
- There is a decreasing incidence of AGB given its relatively modest weight reduction coupled with high rates of revision ^{1,2}.

Case Description

- A 55-year-old male with history of diabetes, hypertension, and hypothyroidism presented with complaints of generalized fatigue, muscle aches, and fever for one week. Fevers ranged around 101 F-102 F alongside jaundiced skin, scleral icterus, and diarrhea.
- Recently, he incurred a tick bite while hiking in Arkansas one month prior. Of note, he had received a LAGB twelve years prior with recent inflation a year ago.
- Labs demonstrated a direct hyperbilirubinemia, transaminitis, and acute kidney injury.
- CT abdomen and pelvis (CTAP) without contrast showed a distended esophagus, small hiatal hernia and hepatosplenomegaly.
- He was initiated on vancomycin, piperacillin-tazobactam, and doxycycline to cover possible tick-borne disease. Blood cultures grew *Streptococcus intermedius*.
- CTAP with intravenous contrast showed occlusive thrombus in the right portal vein and non-occlusive thrombus in the splenic vein, for which he was started on anticoagulation with heparin infusion.

Images

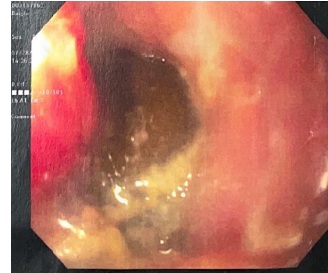


Figure 1: Foreign body visualized in the gastric body region during EGD.

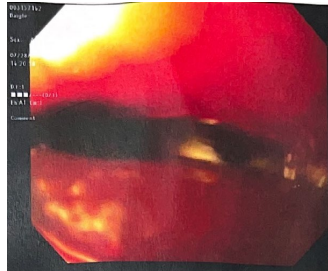

Figure 2: Foreign body visualized in the gastric body region during EGD.

Case Description cont.

- Due to concern for intra-abdominal malignancy he received an EGD which revealed dilation in the entire esophagus with eroded lap band in the stomach and extrinsic compression in the gastric body.
- He underwent upper endoscopy with endoscopic transection, removal of the partially eroded gastric band, laparoscopy, and removal of gastric band tubing and port.
- His post-operative course was further complicated by a peptic ulcer bleed. He underwent exploratory laparotomy with Roux-en-y reconstruction with esophagojejunostomy and later discharged home in stable condition.

Conclusion

- This case highlights the complication of LAGB. The constellation of findings from admission including bacteremia and thrombus are clearly a result of gastric band erosion.
- Band erosion through the wall of the stomach has been reported in approximately seven percent of patients, and is thought to occur as a result of either gastric wall ischemia from an excessively tight band, mechanical trauma from the band buckle, or thermal trauma from electrosurgical energy sources used during band placement ^{3, 4, 5}.
- This case also demonstrates the importance of prompt AGB erosion detection in symptomatic patients. Another area that could benefit from further studies is the utilization of LAGB follow up surveillance EGD to detect band erosions or complications at earlier stages.

References

- Long-term outcomes after bariatric surgery: fifteen-year follow-up of adjustable gastric banding and a systematic review of the bariatric surgical literature. O'Brien PE, MacDonald L, Anderson M, Brennan L, Brown WA. *Ann Surg.* 2013;257(1):87
- Metabolic/bariatric surgery worldwide 2011. Buchwald H, Oien DM. *Obes Surg.* 2013 Apr;23(4):427-36.
- Band erosion after laparoscopic gastric banding: occurrence and results after conversion to Roux-en-Y gastric bypass. Suter M, Giusti V, Héraief E, Calmes JM. *Obes Surg.* 2004;14(3):381.
- The clinical spectrum of band erosion following laparoscopic adjustable silicone gastric banding for morbid obesity. Abu-Abeid S, Keidar A, Gavert N, Blanc A, Szold A. *Surg Endosc.* 2003;17(6):861.
- Erosions after laparoscopic adjustable gastric banding: diagnosis and management. Brown WA, Egberts KJ, Franke-Richard D, Thodiyil P, Anderson ML, O'Brien PE. *Ann Surg.* 2013 Jun;257(6):1047-52.

Introduction

- Osteoporosis is a condition that is likely under diagnosed in high-risk patients that do not meet current screening guidelines.
- Utilization of Dual Energy X-ray Absorptiometry (DEXA) scan for osteoporosis screening in high-risk clinic patients can lead to early diagnosis and treatment of osteoporosis.
- It can ultimately reduce patient morbidity and healthcare expenditure secondary to dangerous fractures needing hospitalizations.

Methods

- Data collection period will include DEXA scans from December 1st, 2021, to March 30th, 2022.
- We will aim for a 25% increase in the diagnosis of osteoporosis in patients with high risk factors for osteoporosis over 4 months with DEXA scan screening.
- The QI project is in progress and results will be collected and extrapolated at the end of the study period.

Conclusion

- Non-modifiable factors are the most common cause of low bone mass, but there are many other causes.
- Low bone mass may be the presentation for conditions such as idiopathic hypercalciuria or celiac disease. All patients should have a thorough history and physical examination and additional testing based on findings.
- Although bone mineral density may not be required in all patients to make the diagnosis of osteoporosis, it may be helpful to determine if additional testing is needed and to guide treatment.

Methods

- We aim to screen patients with high risk factors for osteoporosis over 4 months using DEXA scan to eventually diagnose 25% more cases of osteoporosis in patients that would otherwise not be screened.
- High risk patients in our Clinic Patient Panel with Vitamin D Deficiency, Chronic Kidney Disease, Chronic Liver Disease, Multiple Myeloma, High risk medication use, Rheumatoid Arthritis, Malabsorption issues, hyperthyroidism, Cushing Syndrome, HIV on HAART therapy and hyperparathyroidism will be screened using DEXA scan. We hope to find occult osteoporosis in these high-risk groups that otherwise would not be screened until the age of 65.

References

- Osteoporosis Prevention, Screening, and Treatment: A Review
Juliana M. Kling, Bart L. Clarke, and Nicole P. Sandhu
Published Online: 10 Jul 2014
<https://doi.org/10.1089/jwh.2013.4611>
- Glucocorticoid-induced osteoporosis
Karine Briot, Christian Roux
RMD Open. 2015; 1(1): e000014. Published online 2015 Apr 8. doi: 10.1136/rmdopen-2014-000014
- Diagnosis and Treatment of Osteoporosis in High-Risk Patients Prior to Hip Fracture
Lauren J. Gleason, MD, Lauren J. Gleason, Isaura B. Menzies, MD, MPH, Daniel A. Mendelson, MS, MD, AGSF, Stephen L. Kates, MD, Susan M. Friedman, MD, MPH, AGSF
Department of Medicine, Division of Geriatrics, University of Rochester School of Medicine and Dentistry, Rochester, NY, USA

Acute Encephalopathy in a Previously Catatonic Patient

Erica Mascarenhas MD, Jerald Taggart MD

Department of Internal Medicine, Tulane University School of Medicine, New Orleans, LA



Introduction

- Altered mental status is presentation that requires a broad differential diagnosis, especially when a patient is being treated for mood disturbances.
- AMS in a previously dysphoric patient causes:
 - Medication failure leading to a recurrence of psychiatric symptoms
 - Medication adjustments leading to metabolic derangements
- Other possible causes for an acute mental status change are hypoxia, trauma, seizure, infection, intoxication or stroke.

Initial Presentation

- A 58-year-old woman with bipolar disorder and hypothyroidism presented involuntarily to an inpatient psychiatric unit for bizarre behavior, depressive mood, malnourishment and dysphoric affect.
- She was restarted on home valproic acid 500 mg twice daily and risperidone 2 mg twice daily without improvement.
- Risperidone was switched to lurasidone and valproic acid was changed to 1000 mg at bedtime.
- Patient had increased appetite, interaction and energy.

Valproate-related hyperammonemic encephalopathy (VHE)

Why is it important?

- Valproate-related hyperammonemic encephalopathy (VHE) can occur after acute or chronic use.
- Mild hyperammonemia is common with valproate use and half the cases are asymptomatic.
- A metabolite of valproic acid inhibits an enzyme needed to eliminate ammonia (see below)
- Valproate may also increase ammonia through inhibiting carnitine synthesis
- Compared to VHE, valproate overdose presents with respiratory depression, hypotension, tachycardia, hyperthermia, miosis, agitation, myoclonus and tremors.

Diagnosis

- Elevated ammonia levels
- Liver function tests can be normal

Treatment

- Stop Valproate
- Lactulose: to decrease ammonia levels
- L-Carnitine: expedites the fall of ammonia levels
- Trend ammonia levels

Rapid Response

- A few days later, the patient had an acute mental status change and reversion to a withdrawn temperament with repetitive speaking and arm movements.
- No acute stroke or hemorrhage seen on head CT.
- She was given lorazepam without improvement.
- Her vital signs were stable so she was transferred from inpatient psychiatry to the medicine service.

Hospital Course

- Her laboratory results were significant for an elevated ammonia of 127 $\mu\text{mol/L}$, anion gap metabolic acidosis, and elevated valproic acid level.
- Liver function tests were normal.
- Her valproic acid was held without changes to her mental status.
- She was given lactulose and L-carnitine with rapid improvement of her mental status as her ammonia levels decreased.
- She returned to the inpatient psychiatric unit and her mood continued to improve with lurasidone 60 mg daily and oxcarbazepine 150 mg twice daily.

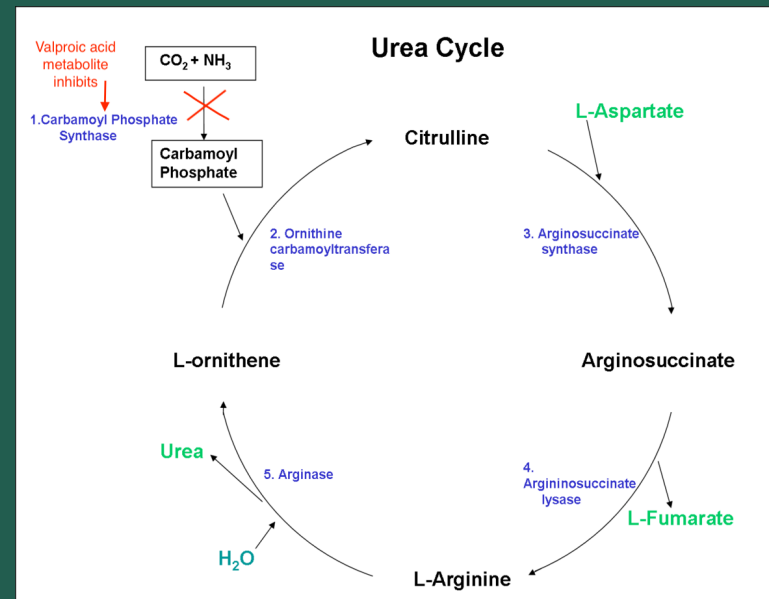
References

Segura-Bruna N, Rodriguez-Campello A, Puente V, Roquer J. Valproate-induced hyperammonemic encephalopathy. Acta Neurol Scand. 2006;114(1):1-7. doi:10.1111/j.1600-0404.2006.00655.x

Lheureux PE, Hantson P. Carnitine in the treatment of valproic acid-induced toxicity. Clin Toxicol (Phila). 2009;47(2):101. DOI: 10.1080/15563650902752376

Dealberto MJ. Valproate-induced hyperammonemic encephalopathy: review of 14 cases in the psychiatric setting. Int Clin Psychopharmacol. 2007;22(6):330. DOI:10.1097/YIC.0b013e3281c61b28

https://en.wikipedia.org/wiki/File:Urea_cycle_1.png



Mediastinal Mass Associated with Whipple's Disease

Aamer Mahmood, MD¹; Jay Patel, MD²; Tina Benoit-Clark, MD¹

1. Louisiana State University Health Sciences Center at Ochsner University Hospital & Clinics
Department of Internal Medicine- Lafayette, LA
2. Ochsner Lafayette General Medical Center, Lafayette, LA

Introduction

Whipple's Disease is a bacterial infection that can involve a wide range of organ systems such as the gastrointestinal, nervous, skeletal, cardiovascular and respiratory systems. [1] Here we present a case of Whipple's Disease with mediastinal involvement.

Case Description

A 53-year-old gentleman with a past medical history of hypertension, hyperlipidemia, hypothyroidism, and cognitive impairment presented with symptoms of fatigue, episodic dizziness/lightheadedness and weight loss of 40 pounds over the last year. A work-up for known mediastinal, retroperitoneal adenopathy was ongoing (lymphangiectasia demonstrated on retroperitoneal lymph node biopsy). The patient was taking Apixaban due to a recent pulmonary embolism.

On admission, he was tachycardic with a HR of 107 but otherwise normotensive and afebrile. His physical examination was unremarkable except for rectal exam revealing guaiac-positive stool.

Laboratory investigations showed hemoglobin/hematocrit of 8.2/27.8 (decreased from 9.3/32.0 a week ago); with MCV of 77.9; hypoalbuminemia (1.9); low iron, low transferrin, low iron binding capacity and low transferrin saturation.

Case Description cont.

CT Angiogram Chest demonstrated chronic RLL thrombus, a 2.5 cm retro-carinal fat-containing mass with a 1.6 cm mediastinal lymph node and interval increase in size of retroperitoneal adenopathy. He underwent capsule endoscopy with diffuse jejunal mucosal ulcerations seen.

ESR/CRP were noted to be 5/9.66 while HIV, T Spot, 1,3 Beta-D-Glucan, Histoplasma Galactomannan Assay, ANA, dsDNA Ab, SSA/SSB Ab, ANCA were negative.

Esophagogastroduodenoscopy showed chronic duodenitis and jejunitis; jejunal biopsy was positive for villous distension by foamy macrophages suspicious for Whipple's Disease. Tropheryma whipplei PCR was sent off and returned positive.

He was started on intravenous Ceftriaxone for 3 weeks followed by Trimethoprim-Sulfamethoxazole twice daily for a year. Once the patient's symptoms improved he was transferred to a skilled nursing facility.

Imaging

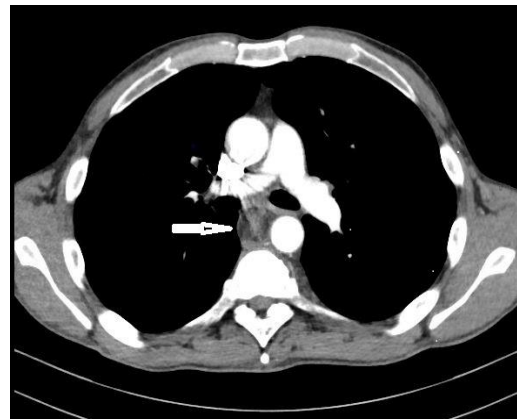

Image 1. Retrocarinal Fat Containing Mass

Discussion

Patients with Whipple's Disease commonly have symptoms of abdominal pain, diarrhea, arthralgias, and weight loss but often present without gastrointestinal manifestations like the patient being discussed. [2].

Thoracic disease; often presenting as chest pain and mild dyspnea [2], has been compared with, and on occasion misdiagnosed as sarcoidosis, with granulomata, parenchymal opacification/nodules and pleural effusions, however mediastinal lesions are uncommon. [3]

Treatment with Trimethoprim-Sulfamethoxazole for 1-2 years has been associated with lower risk of CNS relapse. [4]

References

- 1) Dutly F, Altwegg M. Whipple's disease and "Tropheryma whippelii". Clin Microbiol Rev. 2001;14(3):561-583. doi:10.1128/CMR.14.3.561-583.2001
- 2) Kubaska SM, Shepard JA, Chew FS, Keel SB. Whipple's disease involving the mediastinum. AJR Am J Roentgenol. 1998;171(2):364. doi:10.2214/ajr.171.2.9694452
- 3) Case records of the Massachusetts General Hospital. Weekly clinicopathological exercises. Case 37-1997. A 59-year-old man with anorexia, weight loss, and a mediastinal mass. N Engl J Med. 1997;337(22):1612-1619. doi:10.1056/NEJM199711273372208
- 4) Ramzan NN, Loftus EV Jr, Burgart L, et al. Molecular diagnosis and monitoring of Whipple's disease. Am J Gastroenterol 1996;91:1961-1961 abstract

Introduction

Diagnosis and treatment of hyponatremia is among the most challenging medical conditions physicians routinely encounter.

This case highlights the necessity of using a multifactorial, systematic approach to hyponatremia.

Case Description

66-year-old man presented with **mania and psychosis**. Two days prior, he used **THC** to self-medicate his depression and anxiety.

Past Medical History:

- Central diabetes insipidus due to traumatic brain injury (**kicked in the head by a horse**)
- Multiple hospitalizations for hyponatremia due to polydipsia and inconsistent desmopressin use

Psychiatric History: Bipolar I disorder

Medications: Lithium, desmopressin

T 97.7 HR 80 RR 20 BP 121/71 SpO2 100%

Physical Exam:

General: **animated with psychomotor agitation**
CV: RRR, no m/r/g Pulm: CTAB
Abdomen: soft, non-tender, nondistended
Neuro: no focal deficits, normal strength
Psych: **pressured speech, euphoric affect, flight of ideas with grandiose delusions**

Labs:

9.1	13.3	344	125	94	15	129	9.5	56
			3.9	19	0.9		6.9	51
							4.0	73
							0.5	

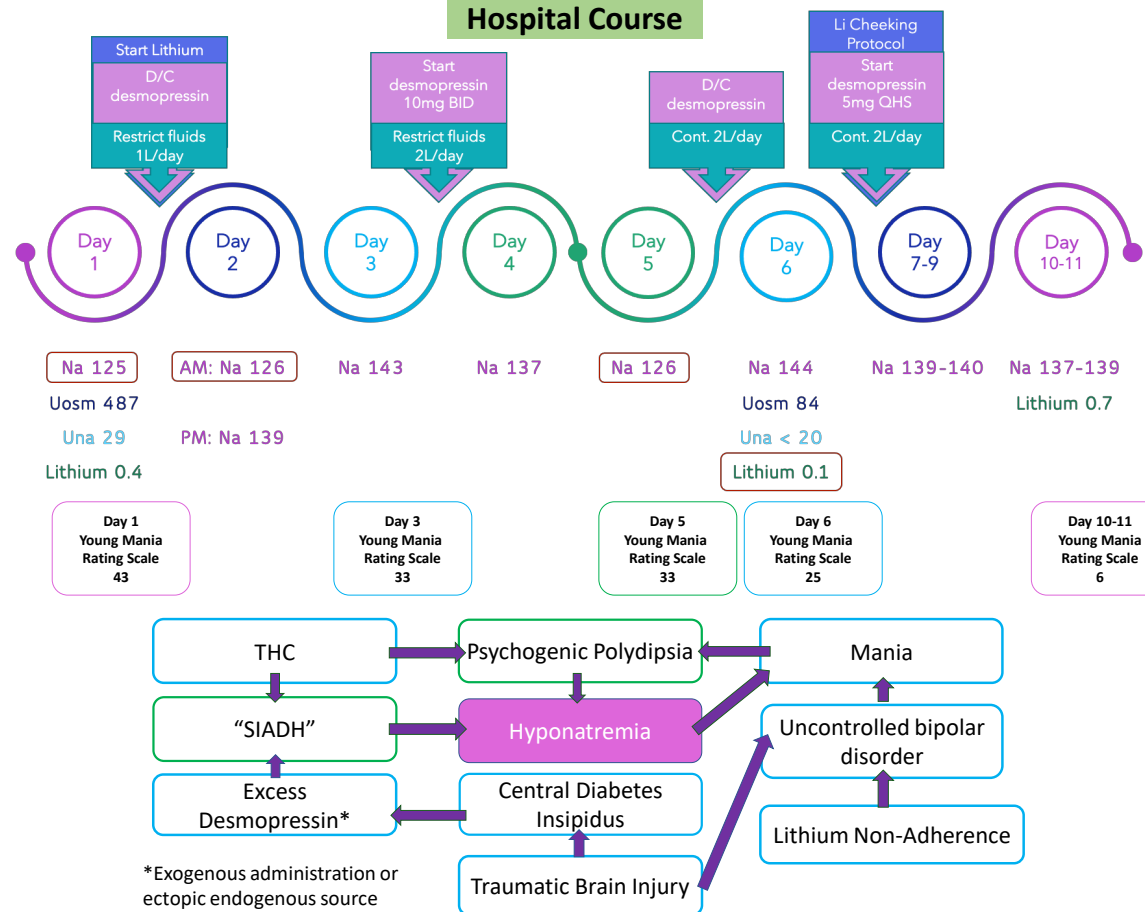
TSH normal, COVID negative, UDS + THC

Hyponatremia can be both a cause and consequence of psychiatric disease

Inappropriate desmopressin dosing for central diabetes insipidus may result in SIADH-associated hyponatremia

For multifactorial hyponatremia, urine studies can elucidate the primary cause and guide targeted therapy

Hospital Course



Discussion

As a result of TBI-induced central diabetes insipidus, our patient has an intrinsic deficiency of vasopressin complicated by bipolar I-related psychogenic polydipsia

At baseline without treatment, he typically has increased thirst and urine output with **low urine osmolality**.

This admission, he unexpectedly had hyponatremia with **high urine osmolality** and normal urine sodium, concerning for SIADH. The etiology of this seems in part to be due to inappropriate dosing of desmopressin.

Psychiatric stabilization required both appropriate lithium administration as well as correction of sodium levels with desmopressin dose adjustments.

Rather than abrupt discontinuation, a dose reduction of desmopressin may have been a safer approach to reduce risk of osmotic demyelination syndrome.

Work up for possible endogenous desmopressin source was recommended for outpatient setting with Med-Psych provider.

References

- Robinson AG. DDAVP in the treatment of central diabetes insipidus. N Engl J Med. 1976 Mar 4;294(10):507-11. doi: 10.1056/NEJM197603042941001. PMID: 1250255.
- Sterns RH, Riggs JE, Schochet SS Jr. Osmotic demyelination syndrome following correction of hyponatremia. N Engl J Med. 1986 Jun 12;314(24):1535-42. doi: 10.1056/NEJM198606123142402. PMID: 3713747.
- Goldman MB, Robertson GL, Luchins DJ, Hedeker D, Pandey GN. Psychotic Exacerbations and Enhanced Vasopressin Secretion in Schizophrenic Patients With Hyponatremia and Polydipsia. Arch Gen Psychiatry. 1997;54(5):443-449. doi:10.1001/archpsyc.1997.01830170069010
- Kamath C, Govindan J, Premawardhana AD, Wood SJ, Adlan MA, Premawardhana LD. Nephrogenic diabetes insipidus partially responsive to oral desmopressin in a subject with lithium-induced multiple endocrinopathy. Clin Med (Lond). 2013;13(4):407-410. doi:10.7861/clinmedicine.13-4-407

Drooling, Stiff, and Mute: adding the toxidrome of kratom to our differential

Sherry Liang, MD ; Kshama Bhyravabhotla, MD ; Rachel Hammer, MD



Case of a 36-year-old gentleman

Girlfriend called 911 after finding him drooling, stiff, and mute at home (Figure 1). He reportedly has "panic attacks and ADHD" but no other medical/surgical history.

Medications: Xanax 2mg BID, Adderall 30mg daily

Objective

T 100.8 F, HR 106, RR 36, BP 155/90, 98% room air

Mute, shivering with mouth clenched and hypersalivating. Normal pupils and reflexes. Extremities with mild rigidity, gooseflesh skin

CBC with WBC 12.1, Hgb 18.1, Plt 469, normal diff BMP with mild hyperchloremic non-gap acidosis CK, thyroid, LFTs, troponin, BNP, HCV, HIV, RPR, COVID, urinalysis, blood cultures normal

Chest X-ray and CT head normal.
UDS + opiates and benzodiazepines
TCA, APAP, EtOH undetectable

Outcome

Admitted to Internal Medicine service with CL psychiatry and poison control consulted.

Treated with scheduled diazepam
Mental status improved in less than 24 hours
Transitioned to oral diazepam on day 2
Eloped on day 3.

Discussion

Our patient's pattern of use and cessation from heroin, kratom, and alprazolam resulted in autonomic instability, psychosis, hypertonia, and sialorrhea, making his initial differential very broad (Figure 2).

Concern for serotonin syndrome, NMS, catatonia, and cholinergic syndrome warranted admission to the internal medicine service.

Due to its complex pharmacology, kratom may contribute to atypical phenotypes of substance toxidromes, as demonstrated here with an atypical presentation of opioid and benzodiazepine withdrawal.

Kratom has a complex pharmacology and may contribute to different phenotypes of substance intoxication & withdrawal

Undetectable on urine drug screens, you won't know unless you ask.

Kratom remains legal, unregulated, and readily available in many states.

Figure 1. Timeline of Presentation

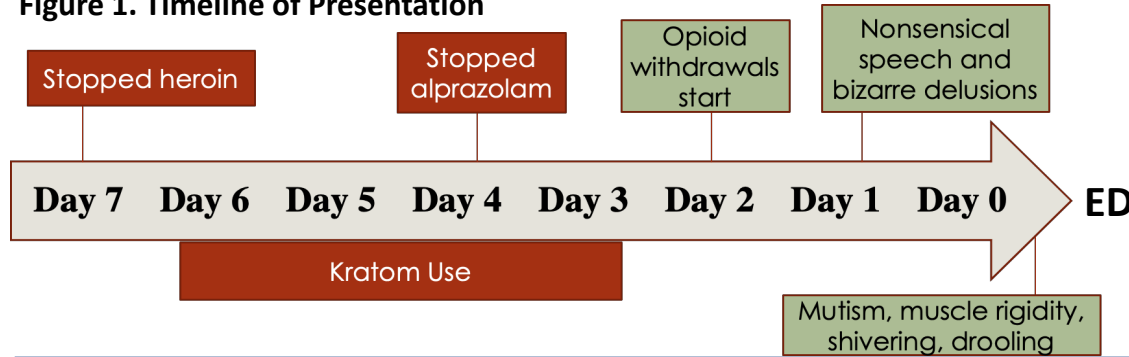
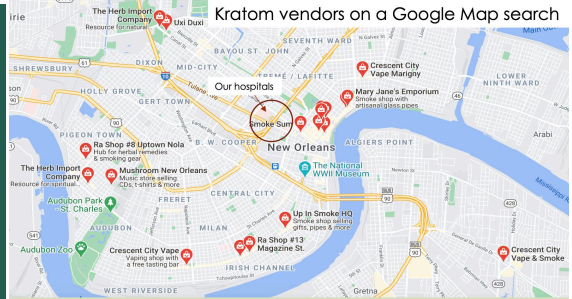

Figure 2. Differential Diagnosis based on Chronology of Symptoms

Differential	TWO DAYS PRIOR TO PRESENTATION	ONE DAY PRIOR TO PRESENTATION	PRESENTATION AT EMERGENCY DEPARTMENT
Opioid withdrawal	Sweating, GI upset, restlessness, irritability, gooseflesh skin, tachycardia	Sweating, GI upset, restlessness, irritability, gooseflesh skin, tachycardia	Sweating, GI upset, restlessness, irritability, gooseflesh skin, tachycardia
Alprazolam withdrawal	Autonomic hyperactivity, insomnia, N/V, agitation, psychosis	Autonomic hyperactivity, insomnia, N/V, agitation, psychosis	Autonomic hyperactivity, insomnia, N/V, agitation, psychosis
Kratom intoxication	Seizures, N/V, psychosis, paralysis	Seizures, N/V, psychosis, paralysis	Seizures, N/V, psychosis, paralysis
Kratom withdrawal	Opioid withdrawal-like symptoms, autonomic hyperactivity, psychosis	Opioid withdrawal-like symptoms, autonomic hyperactivity, psychosis	Opioid withdrawal-like symptoms, autonomic hyperactivity, psychosis
Serotonin syndrome	Clonus, shivering, fever, restlessness, sweating	Clonus, shivering, fever, restlessness, sweating	Clonus, shivering, fever, restlessness, sweating
Neuroleptic malignant syndrome (NMS)	Rigidity, hyperthermia, sweating, altered mentation, mutism, tachycardia, hypertension	Rigidity, hyperthermia, sweating, altered mentation, mutism, tachycardia, hypertension	Rigidity, hyperthermia, sweating, altered mentation, mutism, tachycardia, hypertension
Catatonia	Excitement, mutism, echolalia, stereotypy, rigidity, negativism, waxy flexibility	Excitement, mutism, echolalia, stereotypy, rigidity, negativism, waxy flexibility	Excitement, mutism, posturing, echolalia, stereotypy, rigidity, negativism, waxy flexibility
Cholinergic syndrome	Diarrhea, bradycardia/tachycardia, emesis, salivation	Diarrhea, bradycardia/tachycardia, emesis, salivation	Diarrhea, bradycardia/tachycardia, emesis, salivation



What is Kratom?

Kratom, derived from the plant, *Mitragyna*, acts as an opioid agonist as well as an antagonist at the serotonergic, adrenergic, dopaminergic receptors. It can exhibit opioid, stimulant and/or psychotic effects.

Commonly used to mitigate opioid withdrawal and soothe pain

Toxicities: hepatotoxicity, rhabdomyolysis, cardiomyopathies, arrhythmias, seizures, paralysis, intractable vomiting, psychosis, and spontaneous intracerebral hemorrhage.

Withdrawal: opioid-like withdrawal, psychosis, intrusive obsessive thoughts. No treatment guidelines exist.

Formulations of Kratom



References

1. Ahmad A, Neumayer A. The Addictive Potential and Challenges with Use of the "Herbal Supplement" Kratom: A Case Report and Literature Review. *Pain Medicine*. 2021; :pnab126. <https://doi.org/10.1093/pm/pnab126>
2. Gullotti R, et al. A Case Report of Kratom Addiction and Withdrawal. *Wing*. 2016;15(1):49-52. <https://doi.org/10.1002/wing.1201>
3. Kulkarni M, Gupta A, Anand K, et al. (2014). Alprazolam withdrawal delirium and brief reversible psychosis: a case report. *The primary care companion for CNS disorders*. 16(2). <https://doi.org/10.4088/PCC.1401048>
4. Leong Bin Shiah J, Singh D, Saenger MT, Rahim AA, Vidyanarayanan S. The prevalence of psychotic symptoms in kratom (*Mitragyna speciosa* Korth.) users in Malaysia. *Asian J Psychiatry*. 2015;43:397-401.
5. Matarazzo, R. R., Jr., Minkoff, R., & Sharma, T. R. (2014). Alprazolam withdrawal delirium and brief reversible psychosis: a case report. *The primary care companion for CNS disorders*. 16(2). <https://doi.org/10.4088/PCC.1401048>
6. Mao M, Wang A. (2020). Kratom and Phenibut: A Critical Review for Psychiatric Trainees. *American Journal of Psychiatry Residents' Journal*. 16(2), 6-8. <https://doi.org/10.1177/apps.ajpr.1.2020.160203>
7. Solishkin M, Glickman M. The diagnosis of severe obsessions in the setting of kratom withdrawal and treatment with venlafaxine. *Case report. J Affect Dis*. 2022;301(3):138-9.
8. Wainwright C, Greeningman SA, Ahmed S, Penders T. Kratom Withdrawal: A Systematic Review with Case Series. *J Psychoactive Drugs*. 2018;51(1):12-8.
9. Weiss ST, Douglas HE. Treatment of Kratom Withdrawal and Dependence With Buprenorphine/Naloxone: A Case Series and Systematic Literature Review. *J Addict Med*. 2021;15(2):167-72.

Adult Intussusception: Finding a lead on a rare case

Paula A. Cacioppo M.D.¹, Hooman H. Hajebian B.S.²

¹Department of Internal Medicine, Ochsner Medical Center, New Orleans, LA. ²University of Queensland – Ochsner Clinical School, New Orleans, LA.



INTRODUCTION

Bowel intussusception is defined as a telescoping proximal loop within the distal loop of bowel, obliterating the bowel lumen.¹

95% of cases occur in the pediatric population; intussusception in adults is strongly associated with tumors serving as lead points (>90%), with malignancy accounting for approximately half of all adult cases.²

CASE DESCRIPTION

- History:** A 37-year-old female with no past medical history presents to the ED complaining of suddenly worsening non-localized abdominal pain and distension. She reports a 5-day history of intermittent generalized crampy abdominal pain, which causes her to wake up several times throughout the night. Associated symptoms include anorexia, non-bloody emesis, and constipation, followed by small volume loose stools.
- Exam:** Generalized abdominal tenderness
- Laboratory work-up:** Initial laboratory work-up with CBC, CMP, lipase and CRP were unrevealing except for a low serum bicarbonate (19).
- Imaging:** CT Abdomen with contrast demonstrated a large colonic intussusception from the ascending colon to the splenic flexure, with suggestion of a large polyp or mass in the splenic flexure as a possible lead point (see fig. 1 and fig. 2).

IMAGING

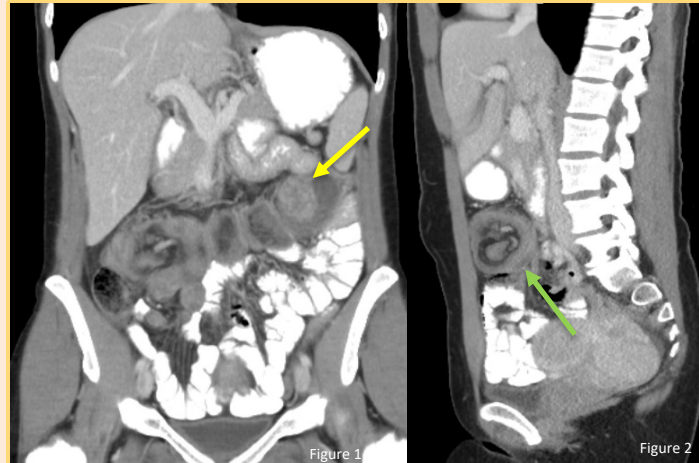


Figure 1. Coronal CT revealing large colonic intussusception with lead point (yellow arrow).

Figure 2. Sagittal CT demonstrating target sign (green arrow).

TREATMENT COURSE

The patient underwent an exploratory laparotomy with right hemicolectomy and lymphadenectomy.

Pathology: Plasmablastic neoplasm involving the ileocecal valve. All surgical margins and 27 resected lymph nodes were negative.

DISCUSSION

Adult intussusception is a rare cause of bowel obstruction (<1% of adult causes) that carries a high risk of complications, if not emergently identified and treated.³

Nonspecific abdominal pain is the most common clinical presentation of Adult Intussusception.⁴

The triad of red currant jelly stool, colicky abdominal pain, and a palpable sausage-shaped mass; classically seen with children, is rarely present in the adult presentation.²

Due to high rates of malignancy, adult cases are traditionally treated with large en-bloc resection.

In conclusion, early diagnosis of intussusception in adults requires a high level of clinical suspicion; failing may lead to complications such as bowel ischemia and perforation.⁵

Treatment in adults requires urgent operative management with oncologic resection and further investigation.

REFERENCES

1. Marinis A, et al. Intussusception of the bowel in adults: a review. *World J Gastroenterol*. 2009 Jan;15(4):407–11
2. Su T, et al. Most Adult Intussusceptions are Caused by Tumors: A Single-Centre Analysis. *Cancer Manag Res*. 2020;12:10011-10015
3. Jain, S., & Haydel, M. J. (2021). Child Intussusception. In *StatPearls*. StatPearls Publishing.
4. Brill A, Lopez RA. Intussusception In Adults. [Updated 2021 Aug 11]. In: *StatPearls [Internet]*. Treasure Island (FL): StatPearls Publishing; 2021 Jan-.
5. Sunkara T, et al. A Rare Case of Adult Colonic Intussusception from Benign Etiology. *Cureus*. 2018;10(1):e2023. Published 2018 Jan 4.

Nephrotic Syndrome with a Solitary Kidney

Michael Stephanides MD, Miranda Mitchell MD

Department of Internal Medicine, Louisiana State University Health Sciences Center, Baton Rouge, LA

Introduction

- ❖ Anti-phospholipase A2 receptor (PLA2R) antibody is a useful serologic marker for stratifying risk and assessing need for immunosuppressive therapy in patients with idiopathic membranous nephropathy.
- ❖ The presence of elevated anti-PLA2R antibody confirms the diagnosis of primary membranous nephropathy and is associated with increased likelihood for developing nephrotic proteinuria, loss of kidney function, and lower chance of spontaneous resolution.
- ❖ Serologic testing is particularly useful when contraindications to kidney biopsy are present in the setting of high clinical suspicion for membranous nephropathy

Case Presentation

- ❖ 43 year old female with a history of distant R nephrectomy for unknown reason presented to the hospital with abrupt onset of headache, blurred vision, left arm numbness, and acute encephalopathy.
- ❖ On arrival, the patient was unable to perform physical exam maneuvers due to confusion. She opened her eyes spontaneously, moved to localized pain, and did not respond to questions.
- ❖ Alopecia areata was present and conjunctivae were pale. On initial labs, patient had a fever with leukocytosis, was profoundly anemic without active evidence of hemorrhage, thrombocytosis, elevated ferritin and LDH, Cr 2.1, urine Pr/Cr 15.3 g, normal PT/PTT, negative toxicology, and unremarkable CSF analysis. Chest x-ray was negative. MRI of the head showed bilateral posterior diffusion restriction concerning for PRES.
- ❖ A presumptive diagnosis of autoimmune hemolytic anemia was made and the patient was transfused 3 units pRBCs. She was started on 60 mg prednisone.

Hospital Course

- ❖ Overnight patient had significant improvement of encephalopathy and was able to respond appropriately to questions with slowed responses.
- ❖ 24 hour urine collection showed a 20.3 g protein. Further workup showed negative ANA, negative HIV Ab, normal complement levels, normocytic anemia on SPEP.
- ❖ Patient was monitored in hospital as her cognition continued to improve and renal function remained stable.
- ❖ On hospital day 4, the patient complained of upper extremity pain. Ultrasound showed multiple bilateral upper extremity and lower extremity DVTs. Patient was initiated on 1 mg/kg lovenox and transitioned to apixaban 5 mg.
- ❖ Renal biopsy was not obtained due to the patient's solitary kidney, recent severe anemia, and anticoagulation.
- ❖ Patient continued to improve over the subsequent week without further complications during her hospital stay. Further lab workup returned with Anti-PLA2R positive at 123.9. She was discharged from the hospital on 60 mg prednisone with plans to taper and further follow up with nephrology and hematology/oncology outpatient.

Discussion

- ❖ This case illustrates a patient with encephalopathy of ultimately unknown origin that resolved with administration of steroids.
- ❖ Her hospital course was complicated by autoimmune hemolytic anemia, nephrotic range proteinuria, and multiple DVTs. Due to her recent severity of anemia and solitary kidney, the risk for complications with kidney biopsy was too high to pursue.
- ❖ Anti-PLA2R antibody testing indicated a primary membranous nephropathy. This consequently allowed a guidance measure for her immunomodulatory therapy without the need for high risk renal biopsy.

References

- ❖ Hofstra JM, Beck LH Jr, Beck DM, Wetzels JF, Salant DJ. Anti-phospholipase A₂ receptor antibodies correlate with clinical status in idiopathic membranous nephropathy. Clin J Am Soc Nephrol. 2011 Jun;6(6):1286-91. doi: 10.2215/CJN.07210810. Epub 2011 Apr 7. PMID: 21474589; PMCID: PMC3109923.
- ❖ Debiec H, Ronco P. PLA2R autoantibodies and PLA2R glomerular deposits in membranous nephropathy. N Engl J Med. 2011 Feb 17;364(7):689-90. doi: 10.1056/NEJMco101678. PMID: 21323563.
- ❖ Burbelo PD, Joshi M, Chaturvedi A, Little DJ, Thurlow JS, Waldman M, Olson SW. Detection of PLA2R Autoantibodies before the Diagnosis of Membranous Nephropathy. J Am Soc Nephrol. 2020 Jan;31(1):208-217. doi: 10.1681/ASN.2019050538. Epub 2019 Dec 16. PMID: 31843984; PMCID: PMC6934991.



Baton Rouge General

Internal Medicine Residency Program

Spontaneous Bacterial Peritonitis

Gift Echefu MD, Rameela Mahat MD, Silpita Katragadda MD, Karthik Reddy MD

Baton Rouge General Internal Medicine Residency Program, affiliate of Tulane University School of Medicine



Baton Rouge General

Internal Medicine Residency Program

Introduction

- ❖ Spontaneous bacterial peritonitis (SBP) is one of the common complications of end stage liver disease (ESLD) with a high morbidity and mortality.
- ❖ Enteric gram-negative rods, such as Escherichia coli and Klebsiella are the usual isolates in 90% of cases.
- ❖ Sphingobacterium Spiritivorum (SS) is a glucose-nonfermenting, gram-negative bacillus that can be found in nature, rarely implicated in human infections.

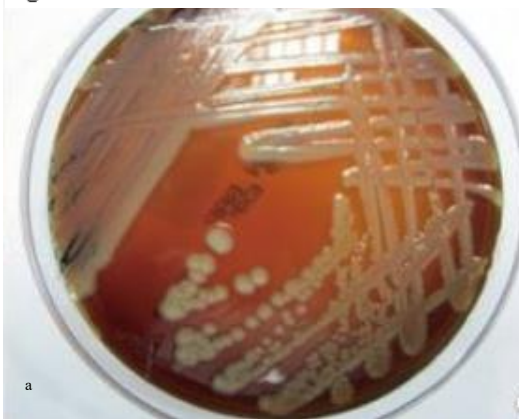
Case presentation

- ❖ A 68-year-old male with past medical history of alcoholic liver disease, hypothyroidism and hypertension who was admitted for management of decompensated liver cirrhosis with tense ascites and methicillin resistant staphylococcus aureus (MRSA) bacteremia noted on blood culture drawn during his ER visit the previous week.
- ❖ On physical exam, he was hypotensive, lethargic, with non-tender distended abdomen, bipedal pitting edema, scleral icterus, flapping tremors, diffuse coarse breath sounds, irregularly irregular heart rhythm and impetigo over the nasal bridge.
- ❖ Abdominal CT revealed nodular liver with moderate ascites and transesophageal echocardiogram was unremarkable for endocarditis.
- ❖ He was promptly initiated on Vancomycin for MRSA.
- ❖ He underwent paracentesis with ascitic fluid analysis consistent with portal hypertension (SAAG >1.1) and leucocyte count of 49 not initially indicating SBP.
- ❖ He continued to decline clinically despite being on vancomycin with therapeutic trough levels..
- ❖ His hospital course was complicated by severe sepsis, hepatic encephalopathy, hepatorenal syndrome to which he succumbed prior to ascitic fluid culture yield..
- ❖ He did not receive gram negative coverage for SBP as his initial ascitic fluid analysis was not indicative of spontaneous bacterial peritonitis based on the PMN >250 cells criteria..

Figures and Labs

Laboratory	Value (reference)
White blood count	19.06 (4.5 to 11.0 × 10 ⁹ /L)
Platelet count	56 (150-450 × 10 ⁹ /L)
INR	1.8 IU
Creatinine	2.01 mg/dl
Sodium	125 (136-145mEq/l)
Aspartate aminotransferase	81 U/l (<34)
Alanine transaminase	95 U/l (<48)
Total bilirubin	10.1 (<1.2 mg/dL)
Lactate dehydrogenase	806 U/l (208-378)
Serum albumin	2.0 g/dl (3.2-4.8)
Serum protein	5 g/dL
Ascitic fluid albumin	0.4 g/dL
Ascitic fluid protein	0.6 g/dL
Ascitic fluid neutrophils	49

Figure 1



Discussion

- ❖ SS is a very rare gram-negative rod of clinical significance and even a rarer cause of SBP.
- ❖ This unusual organism is known to have innate resistance to multiple antibiotics and can cause life threatening sepsis if diagnosis is unrecognized or delayed.
- ❖ Immune compromise is an important risk indicator and the presence of bacteremia further predicts poor prognosis.
- ❖ SBP is classically diagnosed by presence of an increased ascitic fluid absolute polymorphonuclear neutrophil (PMN) count >250/mm³
- ❖ Other important variants of SBP include culture negative neutrocytic ascites, polymicrobial bacterascites and monomicrobial non-neutrocytic bacterascites (MNB).
- ❖ Bacteremia may coexist with SBP, which may be caused by different organisms therefore management should target potential organisms pending culture speciation and sensitivities

Conclusion

- ❖ This rare, uncommon gram-negative organism is a potential cause of SBP in cirrhotic patients with ascites, further contributing to the number of uncommon but clinically significant bacteria causing SBP.
- ❖ This case reaffirms the need to maintain high index of suspicion for other variants of SBP in patients with gram positive bacteremia and ascites, if initial ascitic fluid analysis do not fulfil the classic diagnostic criteria based on neutrophilic count, and to broaden antibiotic coverage especially if there is progressive clinical decline despite appropriate antibiotic coverage.

References

- Koh YR, Kim SY, Chang CL, Shin HI, Kim KH, Yi J. The first Korean case of Sphingobacterium spiritivorum bacteremia in a patient with acute myeloid leukemia. Ann Lab Med. 2013;33(4):283-287. a
- Dever JB, Sheikh MY. Review article: spontaneous bacterial peritonitis—bacteriology, diagnosis, treatment, risk factors and prevention. Aliment Pharmacol Ther. Jun 2015;41(11):1116-31.
- Rimola A, Garcia-Tsao G, Navasa M, et al. Diagnosis, treatment and prophylaxis of spontaneous bacterial peritonitis: a consensus document. International Ascites Club. J Hepatol. Jan 2000;32(1):142-53.
- Hibi A, Kumano Y. Sphingobacterium spiritivorum bacteremia due to cellulitis in an elderly man with chronic obstructive pulmonary disease and congestive heart failure: a case report. J Med Case Rep. Sep 30 2017;11(1):277.



Learning Objectives:

1. Develop an approach to acute purpuric rash in the inpatient setting
2. Manage underlying pathology associated with leukocytoclastic vasculitis

Case Presentation:

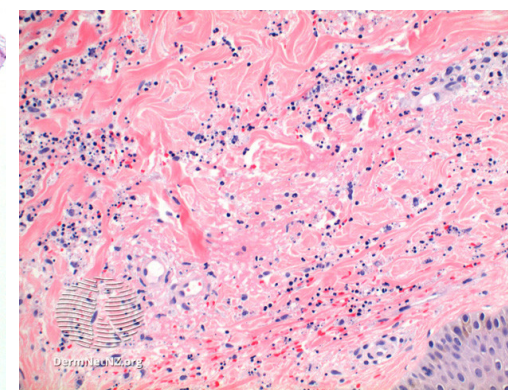
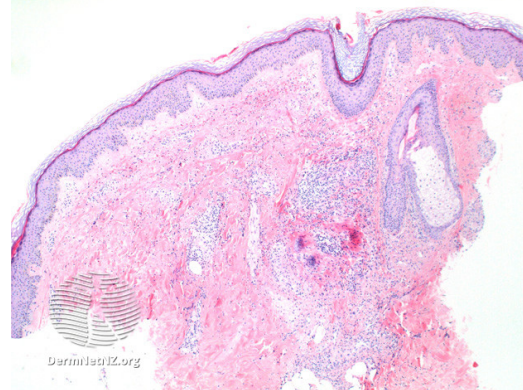
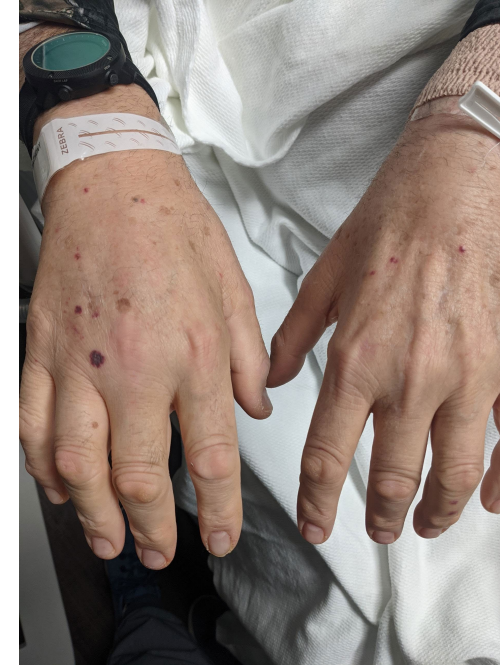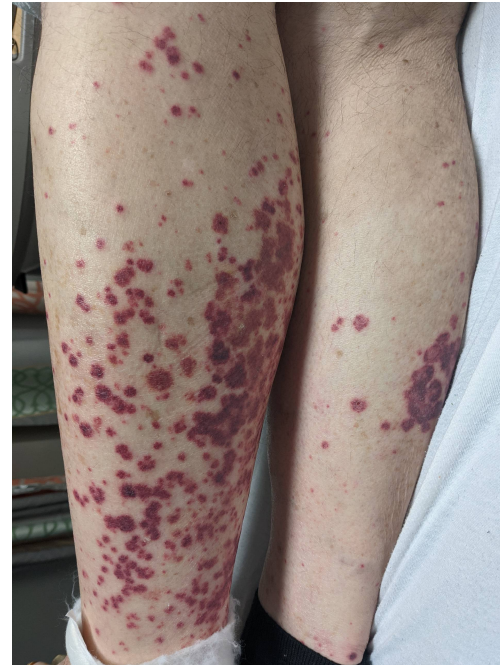A 61-year-old man with type 2 diabetes mellitus underwent surgical resection of left fifth metatarsal due to osteomyelitis refractory to prolonged antibiotic use. Postoperatively, vancomycin and cefepime were initiated.

On postoperative day 4, he developed a painful, palpable maculo-papular purpuric rash primarily on the posterior of his calves, with fewer lesions on the dorsum of the hands, and sparing the palms and soles. No acute changes in his vital signs, CBC or serum chemistries were noted. HIV and HCV studies returned negative. Vancomycin and cefepime were held.

Dermatology consultants performed bedside exam and biopsy. The rash improved with topical clobetasol 0.05%. Antibiotic regimen was changed to doxycycline monotherapy.

Vital signs

Temp 98.2 F	
BP 131/63 mmHg	11.5 10.0 217
HR 80 bpm	
RR 16	139 97 20
SpO2 96% on RA	4.5 29 0.7 106



Superficial and deep perivascular neutrophilic infiltrate with focal fibrinoid degeneration, extravasated erythrocytes, and occasional eosinophils, all consistent with leukocytoclastic vasculitis (LCV).

Discussion:

Purpuric rashes, or lesions that do not blanch with pressure or with diascopy, typically are indicative of vascular damage or vessel wall inflammation.

The internist should consider two common mechanisms for vascular infiltration: direct invasion by **infectious pathogen** and **immune-mediated inflammation**.

LCV or cutaneous small-vessel vasculitis, refers to infiltration of neutrophils, many undergoing apoptosis, into blood vessel walls in response to drug exposure (antibiotics, HCTZ), hepatitis C virus, or autoimmune connective tissue disease, however most cases are idiopathic. Findings will be circular lesions, primarily in dependent areas, and biopsy will show abundant neutrophils with little or no immunoglobulin. Treatment is based in first detecting or ruling out underlying causes and correcting them, with topical steroids for symptom relief only.

Differential diagnoses for palpable purpura include **Meningococcemia**, **ITP**, **Septic vasculitis**, **Sweet syndrome**, **Rocky Mountain spotted fever**, **Autoimmune**, or **Henoch-Schonlein purpura**. (**MISS this RASH**)

Take Home Points:

- LCV presents as an acute palpable, painful purpuric rash, typically in dependent regions.
- Triggers may be antibiotics, infection, autoimmune or idiopathic
- Management consists of eliminating potential underlying causes and topical steroids for symptom relief.

References:
1. Tallon B. Leukocytoclastic vasculitis pathology. Leukocytoclastic vasculitis pathology | DermNet NZ.
<https://dermnetnz.org/topics/leukocytoclastic-vasculitis-pathology>. Published 2011. Accessed October 15, 2021.



Blame it on the (POOP): An Atypical presentation of acute mesenteric ischemia

Paula A. Cacioppo M.D.¹, Hooman H. Hajebian B.S.²

¹Department of Internal Medicine, Ochsner Medical Center, New Orleans, LA. ²University of Queensland – Ochsner Clinical School, New Orleans, LA.

OchsnerHealth

INTRODUCTION

Mesenteric ischemia can be defined as a reduction in intestinal blood flow from an arterial or venous occlusion, affecting either the small or large bowel.

It classically presents with sudden onset severe abdominal pain out of proportion to exam; affecting less than 1 of every 1000 hospital admissions, more frequently occurring in females and often diagnosed after irreversible ischemic insult, requiring surgical resection.¹

CASE DESCRIPTION

- **History:** A 66-year-old male with a past medical history significant for liver transplant in 2017 secondary to NASH Cirrhosis complicated by biliary strictures, diverticulitis, HTN and CAD presenting with a two-month duration of non-radiating crampy left-sided abdominal pain.
- **Exam:** Vitals notable for tachycardia and hypertension. Left-sided abdominal tenderness.
- **Laboratory work-up:** Notable for elevated ALP (140).
- **Imaging:** CT Abdomen with contrast showed evidence of chronic portal vein and SMV thrombosis with small bowel wall thickening and mild mesenteric stranding (see fig. 1)
- **Initial management:** IV fluids, empiric antibiotics and therapeutic anticoagulation. Surgical intervention deferred given normal lactic acid and no leukocytosis.

Hospital day 1:

Patient woke up in the morning reporting worsening abdominal pain, tachycardia, and an episode of BRBPR.

- **Repeat laboratory work-up:** Notable for leukocytosis (24.45) and lactic acidosis (6.0)
- **Repeat imaging:** CTA demonstrated several wall thickened and inflamed loops of mid to distal bowel concerning for developing bowel ischemia.

IMAGING

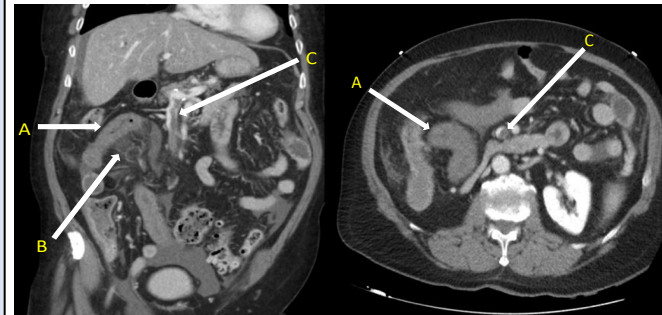


Figure 1. CTA revealing SMV thrombus (C), hypoenhanced and thickened bowel wall (A), and mesenteric stranding (B) in Coronal (Left) and Axial views (Right).

TREATMENT COURSE

Hospital Day 1:

Exploratory laparotomy revealed 1 L of hemorrhagic ascites and an 18-inch segment of devitalized bowel and mesentery. The affected area did not have the appearance of mesenteric venous or arterial thrombosis as a cause. The bowel was left in discontinuity. He was then extubated and admitted to SICU.

Hospital Day 3:

Patient was taken back the OR for a second look, the bowel was anastomosed, and abdomen was closed.

Hospital Day 8:

Interim post-operative course remained uncomplicated; he was discharged home.

DISCUSSION

Mesenteric Venous Thrombosis (MVT) is a rare cause of Acute Mesenteric Ischemia, with a poorly understood natural history, and inconsistency in clinical presentation.

Yet, over the past 2 decades, with the increased use of abdominal imaging, there has been a commensurate rise in prevalence of reported cases.²

Irrespective of etiology, prognosis depends on prompt diagnosis, and rapid management to prevent, or at best minimize, infarction of the bowel or colon.³

Interestingly, BRBPR is often seen very late in presentation and is a poor prognostic indicator.

Anti-coagulation for all patients with acute or subacute MVT is recommended to limit thrombus progression and allow for recanalization.⁴

REFERENCES

1. Bala, M., et al. (2017). Acute mesenteric ischemia: guidelines of the World Society of Emergency Surgery. *World journal of emergency surgery* : *WJES*, 12, 38.
2. Blumberg, S. N., & Maldonado, T. S. (2016). Mesenteric venous thrombosis. *Journal of vascular surgery. Venous and lymphatic disorders*, 4(4), 501–507.
3. Bradbury, et al.(1995). Mesenteric ischaemia: A multidisciplinary approach. *British Journal of Surgery*, 82(11), 1446–1459.
4. Brandt, L. J., & Boley, S. J. (2000). AGA technical review on intestinal ischemia. *Gastroenterology*, 118(5), 954–968.

Introduction

Hemophagocytic lymphohistiocytosis (HLH) is rare syndrome caused by excessive immune system activation. It is a life-threatening disease resulting in high mortality if not recognized and treated early. Here we present a case of HLH following a recent COVID-19 infection.

Case Description

A 20-year-old Middle Eastern male, without significant past medical history other than an uncomplicated COVID-19 course 8 weeks prior to presentation, was admitted to our hospital with complaints of fever greater than 101.5° F, generalized weakness, exertional dyspnea, lightheadedness, and palpitations. Pertinent physical exam findings included tachycardia, mild tachypnea, pale skin with conjunctival pallor, and mild hepatosplenomegaly. Otherwise, exam findings were benign. Laboratory investigations revealed significant derangements with severe anemia, thrombocytopenia, elevated transaminases with normal alkaline phosphatase, hyperferritinemia, and elevated LDH as noted in Table 1. Soluble CD25 levels were also obtained and elevated two times the upper limit of normal. Abdominal ultrasound obtained and confirmed hepatosplenomegaly. With these notable abnormalities, a hemophagocytic syndrome was of great concern; as our patient met 5 out of 8 diagnostic criteria for HLH. With concerns of increasingly poor outcome from treatment delay, bone marrow biopsy was deferred. Our patient was initiated on Etoposide 150mg/m² twice weekly for two weeks in combination with Decadron as per HLH treatment guidelines.

Labs

Table 1 showing lab work-up on admission and over the course of hospitalization:

On admission		Over the hospitalization			
Laboratory test	Day1	Day3	Day5	Day7	
Hemoglobin g/dl	1.8	6.4	9.1	9.2	
WBC K/uL	6.12	1.99	1.92	2.12	
Platelet count	56,000	41,000	39,000	38,000	
Ferritin ng/mL	21059.8	5415.4	2057.6	1510.0	
ALT IU/L	2058	1094	681	441	
AST IU/L	2000	346	73	29	
CRP mg/dl	6.54	2.82	0.89	0.44	
LDH U/L	1913	362	209	178	

Discussion


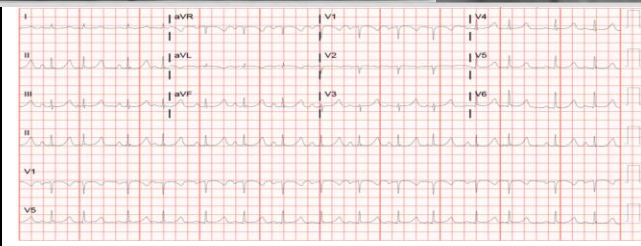

HLH is characterized by multi organ dysfunction due to excessive immune system activation [1]. There are two types of HLH, primary and secondary. Primary, or familial type, is predominantly seen in children and is caused by genetic defects involving the cytotoxic pathway of perforins. Secondary, or acquired type of HLH, can be seen in any age group and is caused by many predisposing factors like viral infections. Since the advent of the novel Coronavirus, COVID-19 has been identified as another virus inciting secondary HLH. The pathogenesis is suspected to be subclinical inflammation causing immune dysregulation. Very few post COVID HLH cases have been described. Without appropriate management, the survival of HLH patients is only a few months therefore prompt initiation of therapy is vital. Treatment of HLH is based on the HLH 94 protocol which includes 8 weeks of induction therapy with Etoposide and Dexamethasone with or without intrathecal methotrexate..

Conclusion

Prompt suspicion for HLH in our patient and the abrupt commencement of induction therapy lead to improvement in biochemical markers, and a successful hospital discharge.

References

1. Alexandra H Filipovich 1, Hemophagocytic lymphohistiocytosis (HLH) and related disorders, PMID: 20008190, DOI: 10.1182/asheducation-2009.1.127

Introduction	Figures	Discussion
<ul style="list-style-type: none"> Takotsubo cardiomyopathy (TTC) is characterized by acute, reversible left ventricular dysfunction with apical ballooning/hypokinesis with basal hyperkinesis in the absence of significant coronary artery stenosis detected by angiography Reverse takotsubo cardiomyopathy (rTTC) is a variant of takotsubo cardiomyopathy in which the base is hypokinetic with apical hyperkinesis. The widespread use of early coronary angiography in the setting of acute coronary syndromes has increased awareness of this condition. Phlegmasia cerulea dolens (PCD) is a rare but potentially fatal form of a acute massive DVT characterized by severe pain and swelling of the extremities with cyanosis. 		<ul style="list-style-type: none"> rTTC presents as acute coronary syndrome, with chest pain, dyspnea, EKG findings, confusing and delaying its diagnosis. Diagnosis is based on Mayo criteria; a history of emotional or physical trigger, new EKG changes, troponin elevation and absence of significant coronary involvement, or acute rupture of plaque or thrombosis. Proposed pathophysiology of reverse Takotsubo include intense physiological, iatrogenic stress resulting in a catecholamine surge, myocardial stunning, multivessel coronary artery spasm and indirect myocardial damage. Several clinicopathologic features distinguish rTTC from other variants according to literature. Patients are relatively younger, due to the higher density of adrenoreceptors in the base in this group. It is linked to higher mental and physical stress than emotional stress. Troponin is higher due to more muscle mass in the base and natriuretic peptide level is often lower, explaining less severe heart failure symptoms. Phlegmasia cerulea dolens is a rare but potentially life-threatening complication of acute proximal deep venous thrombosis which carries the risk of arterial ischemia, gangrene requiring amputation, circulatory collapse and shock leading to death. Mortality rate is reported at 40%, with malignancy conferring the highest risk (55%). Venous thromboembolism, specifically PE has been associated with cardiomyopathy with vascular dysfunction and hemodynamic compromise proposed as potential predisposing factors.
Case presentation		
<ul style="list-style-type: none"> 56-year-old male who presented with pain, swelling and cyanosis of left lower extremity to the thigh that began the previous week. He also reported shortness of breath on exertion. He had no chest pain, palpitations, fever, change in bowel habits or urinary symptoms. Past medical history of COPD not dependent on oxygen, 50 pack year tobacco use, cavitary lung lesion for which he was undergoing outpatient evaluation prior to admission. On exam, he was tachycardic, hypotensive, stable on room air, cachectic, heart sounds with regular rate and rhythm, no JVD, decreased breath sounds on the right, erythematous, tender, left lower extremity cyanosis, cool to touch with no palpable distal pulses. Lower extremity venous duplex showed completely occluded unilateral left proximal superficial and deep venous thrombi. CTA of the chest ruled out pulmonary embolism but revealed multiple cavitary masses in the right lower lobe and upper lobes with the largest measuring 9.7 x 9.1 x 11.8 cm. He underwent catheter directed thrombolysis and heparin drip under close supervision in the intensive care unit. On day 3, he reported chest pain and atrial fibrillation with rapid ventricular response was noted on cardiac monitor. EKG revealed anterior ST-elevation myocardial infarction, absent on prior EKG at presentation. TTE revealed left ventricular ejection fraction of 20% with apical hyperkinesis. Cardiac catheterization revealed basal hypokinesis with hyperdynamic left ventricular apex, LVEF 35%, and no obstructive coronary artery lesion, indicating reverse Takotsubo cardiomyopathy. On day 4, he went into cardiogenic shock requiring pressor support and hypoxic requiring oxygen supplementation via mechanical ventilation. This was discussed with patient and family who decided against these intervention, opting for comfort care and expired the next day. 	<div>  <div>Initial EKG</div> </div> <div>  <div>EKG, Hospital day 3</div> </div>	<ul style="list-style-type: none"> In our patient, the increased catecholamine levels from severe pain and vascular dysfunction associated with PCD, critical illness and the emotional distress from the news of suspected malignancy, all of which are well documented predisposing risk factors, may have contributed to the development of rTTC culminating in fatal cardiogenic shock. Khera et al reviewed trends in hospitalized patients with TTC and observed higher mortality in men which they attributed to higher prevalence of cardiogenic shock, cardiac arrest, and respiratory failure requiring mechanical ventilation in this population. Management is supportive and individualized, usually with beta blocker and angiotensin converting enzyme inhibitors or angiotensin receptor blocker depending on the patient's hemodynamics. Anticoagulation is indicated in patients with LV thrombi. Catecholamine are safe in symptomatic hypotension if outflow obstruction is absent. <div> <div>References</div> <ul style="list-style-type: none"> •Khera R, Light-McGroary K, Zaher F, Horwitz PA, Girotra S. Trends in hospitalization for takotsubo cardiomyopathy in the United States. <i>Am Heart J.</i> Feb 2016;172:53-63. doi:10.1016/j.ahj.2015.10.022 •Kawai S, Kitabatake A, Tomoike H, Group TC. Guidelines for diagnosis of takotsubo (apella) cardiomyopathy. <i>Circ J.</i> Jun 2007;71(6):990-2 •Awad HH, McNeal AR, Goyal H. Reverse Takotsubo cardiomyopathy: a comprehensive review. <i>Ann Transl Med.</i> Dec 2018;6(23):460. doi:10.21037/atm.2018.11.08 </div>

Introduction

Adenovirus usually causes pneumonia in immunocompromised adult patients. We present an immunocompetent patient with severe Adenovirus pneumonia leading to ARDS. [1]

Case Description

A 62-year old female smoker presented with a cough that produced white sputum, chills, dyspnea and diarrhea. She denied having any chest pain, abdominal pain, palpitations, hemoptysis or orthopnea. On admission she was febrile at 38.4 C; BP- 112/79 mmHg; HR- 95/min; RR- 20/min; and had saturations of 91% on room air. Laboratory investigations showed Hg/Hct of 13.8/38.6 and WBCs of 10.7 with lymphopenia and neutrophilia.

Chest x-ray demonstrated bilateral interstitial infiltrates without effusions or consolidates. CT-chest showed bilateral reticular upper lobe infiltrates, ground glass opacification and right lower lobe nodules with hilar lymphadenopathy.

She was started on Levofloxacin, Piperacillin-Tazobactam and Methylprednisolone without improvement. Antibiotics were escalated to Meropenem, Linezolid, and Doxycycline.

A repeat CT-chest demonstrated worsening bilateral interstitial infiltrates and new pleural effusions.

Case Description cont.

Urine Legionella Antigen, 1,3 Beta D-Glucan, Yersinia serology, urine histoplasma antigen, ANA, ANCA, RF, and SSA/SSB were negative. Respiratory PCR panel returned positive for Adenovirus. Her oxygen requirements increased eventually requiring intubation for mechanical ventilation. She also developed mild transaminitis, thrombocytopenia, and anemia over her hospital stay. Bronchoalveolar lavage showed WBCs of 674 with 20% lymphocytes. She was also found to be lymphopenic (213) with decreased CD4 (115) & CD8 (20) cells.

Antibiotics and steroids were discontinued once she started improving and no antivirals were initiated. Over the course of the following week the patient was weaned off of the ventilator and extubated after which she did well.

Imaging

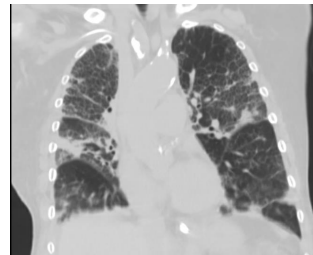


Image 1: Bilateral reticular infiltrates with ground glass opacification

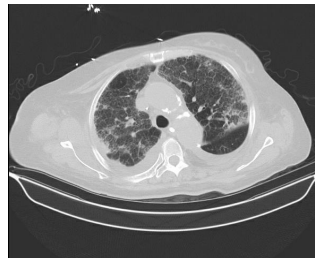


Image 2 : Bilateral patchy ground glass opacities

Discussion

This is a rare case of severe Adenovirus pneumonia in an immunocompetent patient. The patient lacked the classic symptoms of conjunctivitis, pharyngitis, or rash. [2]

She did have relative lymphopenia with normal leukocytes with eventual thrombocytopenia and AST elevation seen in severe Adenovirus pneumonia. [2] She also had typical imaging findings of interstitial infiltrates seen with Adenovirus including effusions which are associated with protracted illness. [3]

Cidofovir and Ribavirin have been used as treatment, although in our patient the infection self-resolved with improved respiratory status. [4]

References

- 1) Yoon BW, Song YG, Lee SH. Severe community-acquired adenovirus pneumonia treated with oral ribavirin: a case report. BMC Res Notes. 2017;10(1):47. Published 2017 Jan 18. doi:10.1186/s13104-016-2370-2
- 2) Clark TW, Fleet DH, Wiselka MJ. Severe community-acquired adenovirus pneumonia in an immunocompetent 44-year-old woman: a case report and review of the literature. J Med Case Rep. 2011;5:259. Published 2011 Jun 30. doi:10.1186/1752-1947-5-259
- 3) Chong S, Lee KS, Kim TS, Chung MJ, Chung MP, Han J. Adenovirus pneumonia in adults: radiographic and high-resolution CT findings in five patients. AJR Am J Roentgenol. 2006 May;186(5):1288-93. doi: 10.2214/AJR.05.0128
- 4) Kim SJ, Kim K, Park SB, Hong DJ, Jhun BW. Outcomes of early administration of cidofovir in non-immunocompromised patients with severe adenovirus pneumonia. PLoS One. 2015;10(4):e0122642. Published 2015 Apr 15. doi:10.1371/journal.pone.0122642

