

A Case of Purtscher's Retinopathy in the Setting of Acute Alcoholic Pancreatitis

Ryley McPeters MD, Tejas Joshi MD, Tyler Thorne MD, Mathoula
Bilalis MS3, Lance Turkish MD, John Amoss, MD

Introduction

- Purtscher's retinopathy is a rare condition first described in 1910 following intracranial trauma
- This occlusive microvasculopathy is characterized by sudden visual loss with multiple areas of retinal whitening in the posterior pole of the eye.
- The non-traumatic form of this retinopathy has been associated with acute pancreatitis, connective tissue disorders, renal failure, childbirth, bone marrow transplantation, and Valsalva maneuver
- The pathophysiology behind Purtscher's retinopathy secondary to complement-activating systemic diseases, like pancreatitis, is likely due to proteases released during inflammation or injury.

Presentation to ED

- 28 year old female with PMH of alcohol abuse, paroxysmal supraventricular tachycardia, gastritis, and multiple admissions for acute pancreatitis and Mallory-Weiss tear
- Chief Complaint: Emesis, Shortness of breath, and Abdominal pain for one day
 - Bilious and non bloody emesis – multiple episodes throughout the day
 - Epigastric and upper abdominal pain that radiated to back

- Past Surgical History:
 - Dilation and Curettage (D&C)
- Home Medications: Atenolol 50 mg
- Allergies: Penicillins
- Family History: Mom with fibromyalgia
- Social History:
 - Former tobacco use
 - Current alcohol use: 2-3 mixed drinks with vodka a week
 - Previously heavy drinker: 1 handle Jack Daniels nightly
 - Previous cocaine and THC use none currently

ROS

- Constitutional: Chills and Fever
- Respiratory: Shortness of breath secondary to pain
- Cardiovascular: Chest Tightness
- Gastrointestinal: Abdominal pain, nausea, vomiting
- MSK: Back pain
- Endocrine: Polydipsia
- Otherwise negative

Physical Exam

- Vitals: Temp 97.9 F BP 111/79 RR 26 HR 126 BPM SpO2 99%
- General: **Mild Distress**. Alert and cooperative
- Eyes: PERRL, conjunctiva clear, EOMi
- Lungs: **Tachypnea**, unlabored breathing, **coarse breath sounds** in bilateral lung bases
- Chest wall: No deformity or tenderness
- Heart: RRR, S1 and S2 normal; no murmurs, rubs, gallops
- Abdomen: **Diffusely tender abdomen that was worse in the epigastric region. Hypoactive bowel sounds.**
 - No rebound tenderness, guarding, or rigidity

- Hepatic Function Panel: Elevated Lipase, AST, ALT, Alkaline phosphatase, and total bilirubin
 - Lipase = 939 U/L (Reference: 16-63 U/L)
 - AST = 351 U/L (Reference: 10-40 U/L)
 - ALT = 179 U/L (Reference: 10-36 U/L)
 - Alkaline Phosphatase = 133 U/L (Reference 45-122 U/L)
 - Total Bilirubin = 1.8 mg/dL (Reference: 0.2-1.0 mg/dL)
- CBC: No leukocytosis or anemia, Normal platelet Count
- Abdominal Ultrasound: peripancreatic edema correlating with acute pancreatitis

Diagnosis

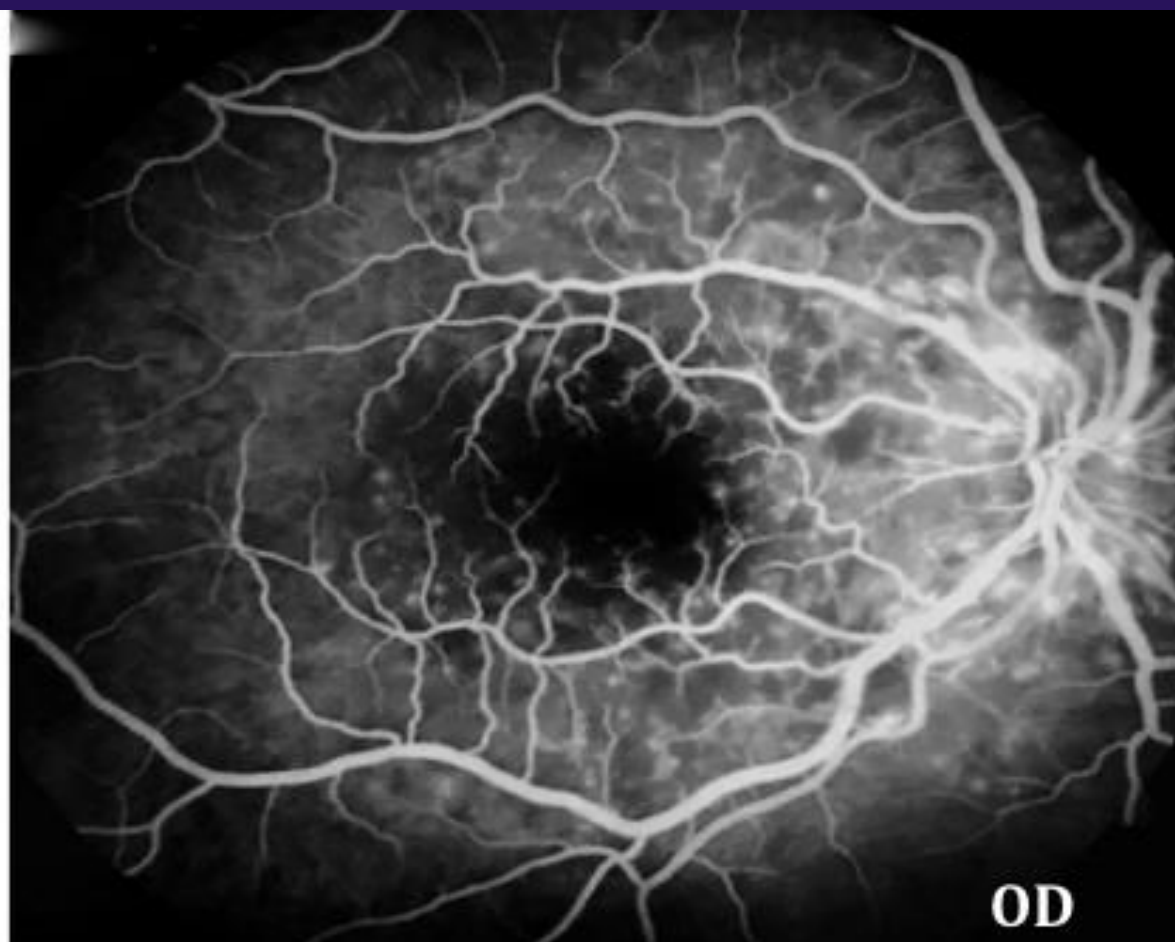
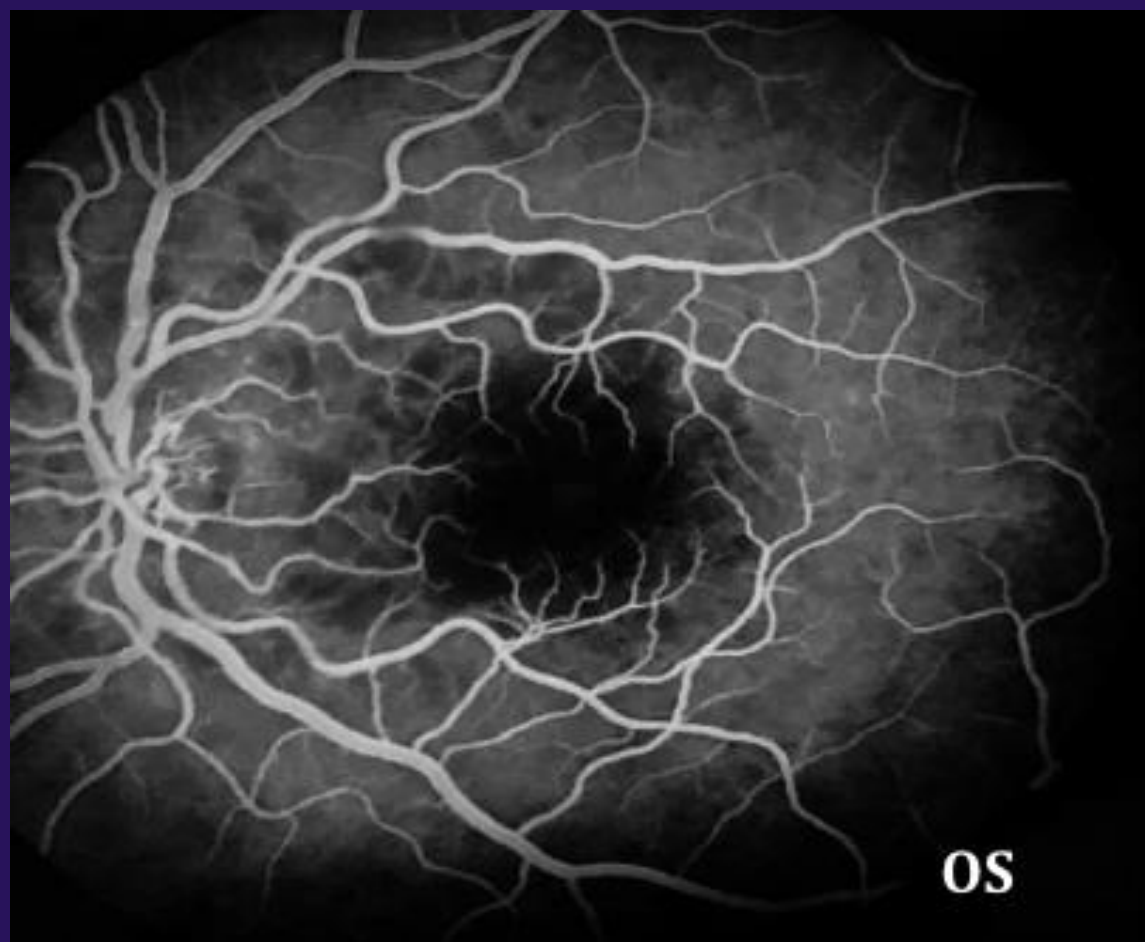- Patient admitted for acute alcoholic pancreatitis
- Treatment:
 - 2L bolus in ED
 - IVF with LR
 - Pain Control with PRN Dilaudid
 - Encouraged clear liquid diet
 - Zofran for nausea
 - Thiamine and multivitamin (EtOH Abuse)
 - Home dose of Atenolol for paroxysmal SVT

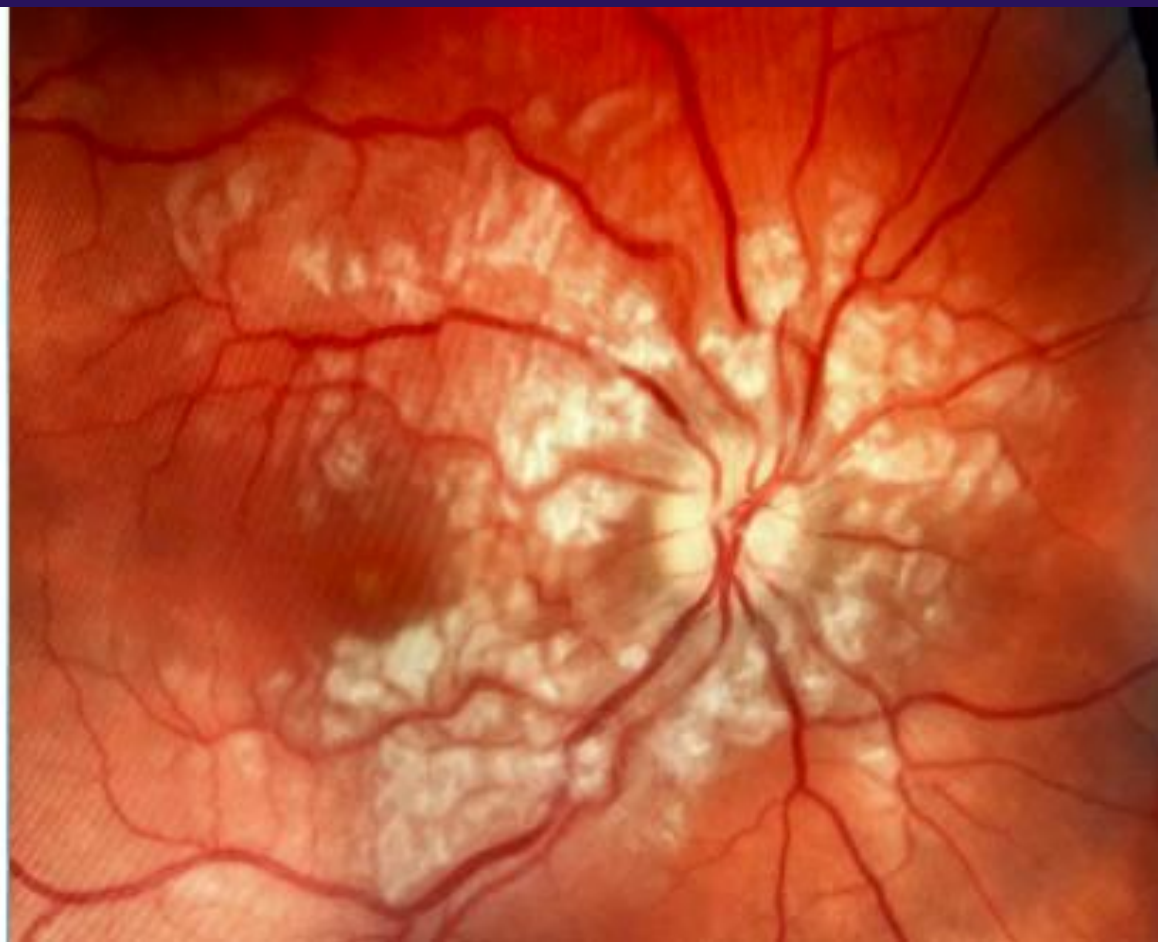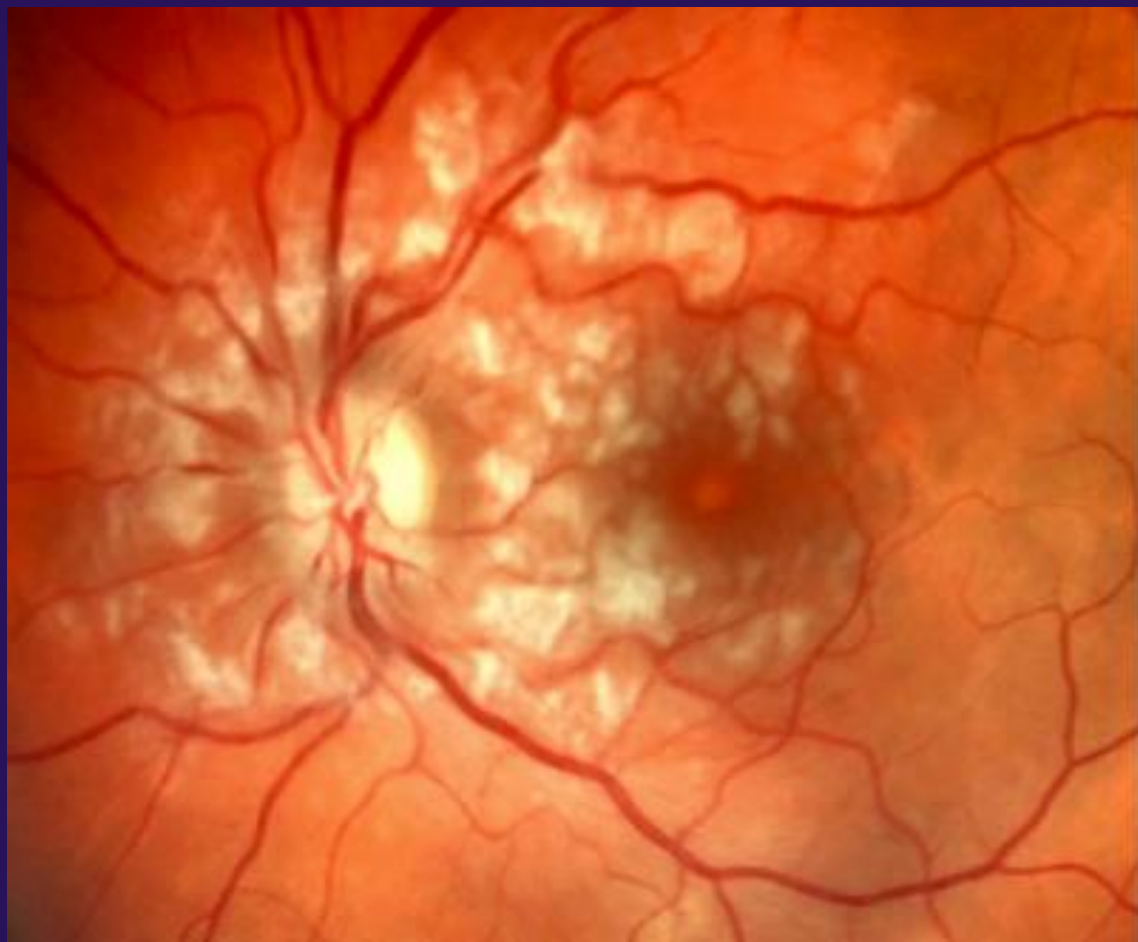Hospital Day 1

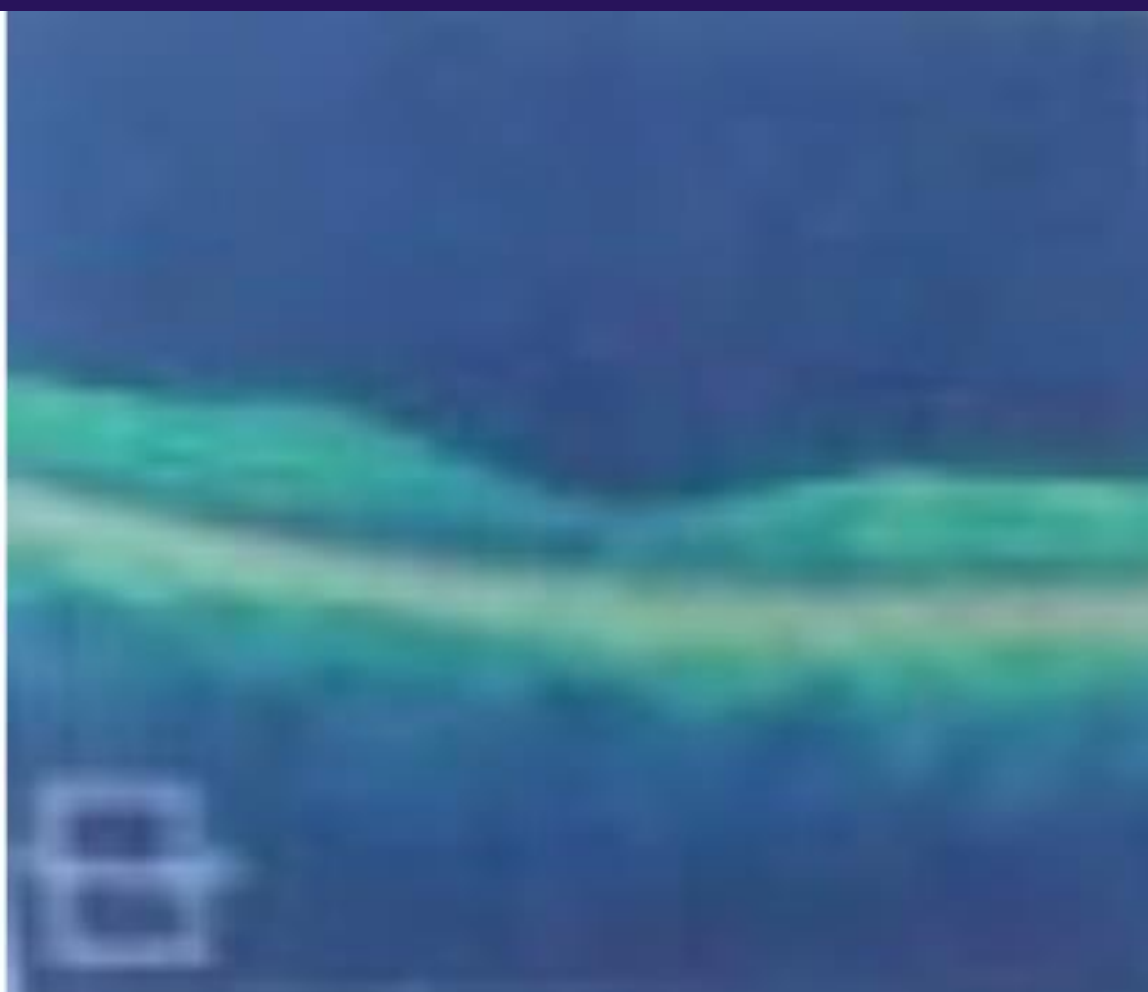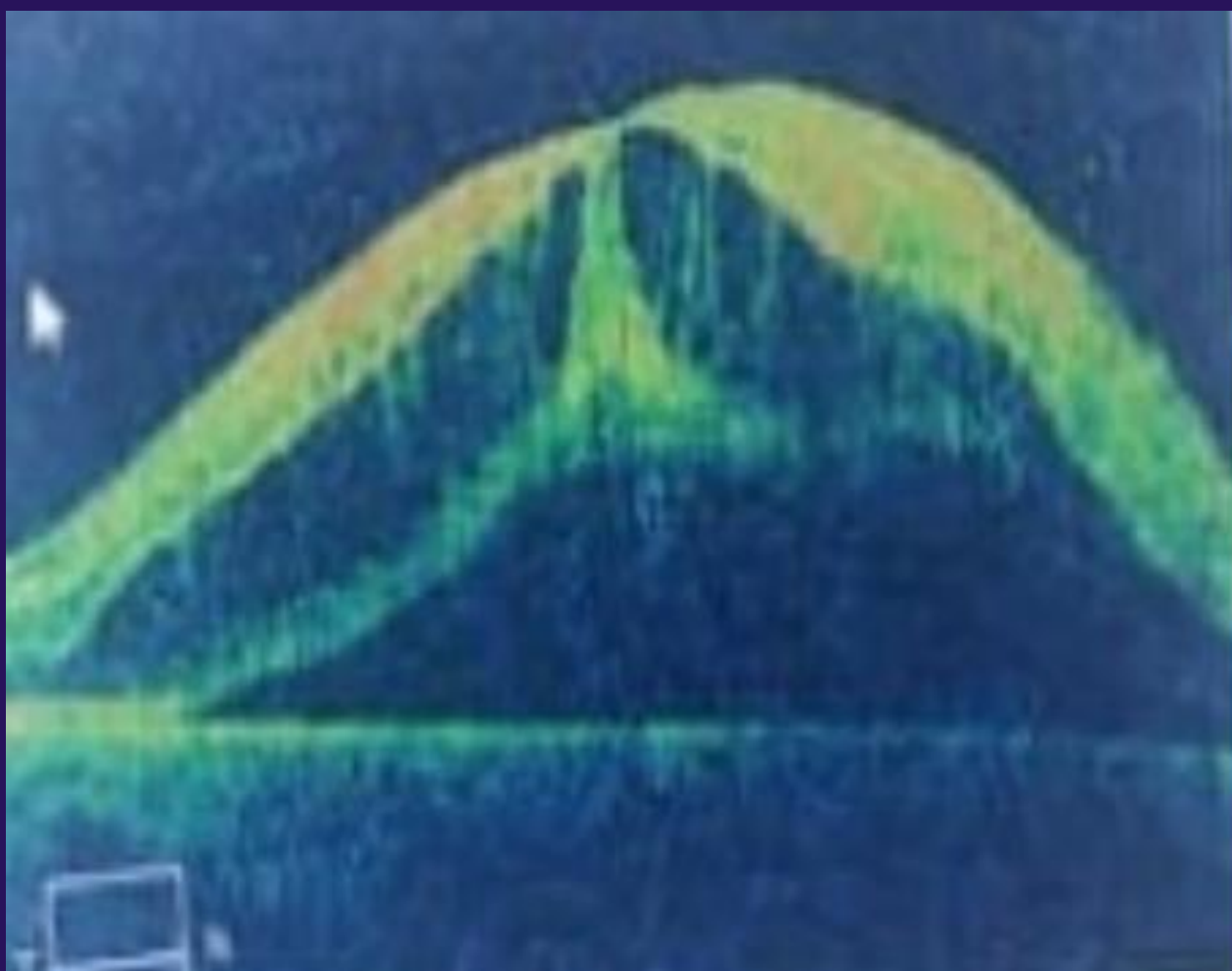
- Abdominal pain improving and tolerating clear liquids
- Visual disturbances upon awakening from a nap
- Blurry vision and floaters
- Resolved by evening

Hospital Day 2

- Woke up in the morning with worsening blurry vision and floaters again – right eye worse than left
- Unable to read pocket Snellen at bedside
- Bedside Ophthalmologic Exam: Multiple cotton wool spots bilaterally
- Ophthalmology Evaluation:
 - Macular Edema
 - Neurosensory detachment of macula bilaterally
 - Loss central field vision bilaterally – preserved peripheral vision
 - Visual acuity 20/200 bilaterally with no improvement on pinhole







Diagnosis and Treatment

- Purtscher's Retinopathy secondary to pancreatitis
 - Macular edema and neurosensory detachment secondary to Purtscher's
- Intraocular steroid injections with weekly follow up
- Exam at 8 weeks – improvement to visual acuity 20/40 bilaterally
 - Patient was initially legally blind and now she is able to see with glasses
 - Denies any worsening symptoms of retinopathy

Discussion

- Purtscher's retinopathy has a unique clinical presentation that was previously described following trauma.
- This retinopathy can present secondary to non-traumatic systemic diseases like acute pancreatitis and was first described this way in 1975.
- The development of these visual changes is independent to the severity of pancreatitis and presents with a wide range of manifestations.
- The diagnosis can be made clinically with sudden loss of visual acuity with typical fundus appearance in the context of systemic disease.
- Purtscher Flecken are pathognomonic for this disease. They are variable, polyglonal regions of retinal whitening with a clear zone between the affected retina and the adjacent arteriole.

- The treatment for the ocular complications of Purtscher's secondary to systemic disease have not been proven and prognosis depends on the areas of the retina that are affected.
- Isolated case reports have shown rapid improvement in vision with high dose IV steroids. Steroids may help preserve the neuronal membrane and suppress granulocyte aggregation caused by complement activation.

Take Home Message

- Patient's complaining of changes in vision following an episode of acute pancreatitis should undergo eye examination in order to rule-out Purtscher-like retinopathy.
- Meticulous follow-up is a must and should be performed in order to avoid severe complications.

References

- Purtscher O. Noch unbekannte befunde nach schadeltrauma. Ber Dtsch Ophthalmol Ges 1910;36:294-310.
- Nema N, Ishrat S, Verma A, Kela M. Purtscher-like retinopathy in acute alcoholic pancreatitis. Oman J Ophthalmol 2016;9:110-2.
- D. Bonacin, D. Fabijanic, K. Karaman, L. Znaor. Purtscher's retinopathy associated with acute pancreatitis. Internal Medicine Journal. 2012. 42(3):339.
- D. M. Inkeles and J. B. Walsh, "Retinal fat emboli as a sequela to acute pancreatitis," *American Journal of Ophthalmology*, vol. 80, no. 5, pp. 935–938, 1975.
- Rita Massa, Carolina Vale, Mafalda Macedo, et al., "Purtscher-Like Retinopathy," *Case Reports in Ophthalmological Medicine*, vol. 2015, Article ID 421329, 5 pages, 2015
- Agrawal, A., & Mckibbin, M. A. (2006). Purtschers and Purtscher-like Retinopathies: A Review. *Survey of Ophthalmology*, 51(2), 129-136.
doi:10.1016/j.survophthal.2005.12.003