



**2023 Hawai'i Chapter
Scientific Meeting**

**"Re-emergence" –
'Puka Hou Ana'**


**Saturday, February 25, 2023
In-person/Virtual**

❖ *This activity has been designated for 6.5 CME credits and 6.5 MOC points*

Chapter Excellence Award – Gold Winner



(September 2022) I am pleased to announce that our chapter is in receipt of the Gold Level of the 2022 Chapter Excellence Award! The award recognizes truly extraordinary chapters that surpass excellence in chapter management. We are in the company of 47 other outstanding chapters. In order to achieve the Gold Level of the Chapter Excellence Award, chapters must meet twenty Bronze criteria, seventeen Silver criteria and multiple Gold level activities. Criteria include such activities as having a legislative action plan or agenda, holding a volunteerism/community service activity, holding multiple stand-alone meetings, having revenue sources outside of dues and meeting registration fees, implementing a strategic plan, implementing a formal recruitment and retention plan and measuring outcomes, conducting various activities for Medical Students, Residents and Early Career Physicians. I would like to extend a special thanks to those chapter members who assisted us in all of these endeavors! For their hard work and dedication, we received this award.



Congratulations Alvin N. Furuike, MD, MACP on being awarded Mastership

(October 2022) We are excited to share that the [Mastership/Awards] Committee and the Board of Regents have approved Alvin N. Furuike, MD, MACP to receive Mastership during the 2023 Internal Medicine Meeting in San Diego, California.

ACP Bylaws state that MACPs shall be Fellows who have been selected because of “integrity, positions of honor, impact in practice or in medical research, or other attainments in science or in the art of medicine.” MACPs must be highly accomplished persons demonstrating impact in practice, leadership, or in medical research. Evidence of their achievements can come from many types of endeavors, such as renown within their field and/or ACP chapter, research, education, health care initiatives, volunteerism, administrative positions, care of patients, and service to their community.

One of the goals of the American College of Physicians is to “recognize excellence and distinguished contributions to internal medicine.” As a way of achieving this goal, the College offers 21 awards and a number of Masterships each year. Annually, awardees and MACPs are honored at the Convocation ceremony held during the Internal Medicine meeting.

Learning Objectives

At the conclusion of this activity, the participant will be able to know about:

- Heart Failure/SGLT2
- Addiction Medicine Updates
- Updates in Internal Medicine - Best Articles of the Year
- Updates on Health Inequities among Asian Americans, Native Hawaiians and Pacific Islanders for (Busy) Internal Medicine Physicians (and how we can make a difference!)
- Hawaii Long COVID

CME Accreditation and MOC Points

The American College of Physicians is accredited by the Accreditation Council for Continuing Medical Education (ACCME) to provide continuing medical education for physicians.

The American College of Physicians designates this live activity for a maximum of **6.5 AMA PRA Category 1 Credit(s)TM**. Physicians should claim only the credit commensurate with the extent of their participation in the activity.

Successful completion of this CME activity, which includes participation in the evaluation component, enables the participant to earn up to **6.5** medical knowledge MOC points in the American Board of Internal Medicine's (ABIM) Maintenance of Certification (MOC) program. Participants will earn MOC points equivalent to the amount of CME credit claimed for the activity. It is the CME activity provider's responsibility to submit participant completion information to ACCME for the purpose of granting ABIM MOC credit.

Your Opinion Counts

At the conclusion of the meeting, please take a moment to complete the meeting survey form and verification of attendance form in your packet and return it to the registration desk. We value your opinion and use the surveys in planning future meetings.

Chapter Excellence Award

We are pleased to announce that our chapter is in receipt of the 2021 Chapter Excellence Award. The Chapter Excellence Award recognizes those chapters that excel in reaching the standards for managing a chapter, such as communicating to members, instituting Medical Students' and Resident/Fellow Members' activities and advancing and recruiting members.

Resident/Fellows' and Medical Students' Activities

Clinical vignettes, posters, and research papers prepared by Resident/Fellow Members and Medical Students will be presented at the meeting. Winners will receive a cash prize and be eligible for entrance into the national competition held during the ACP Internal Medicine National Meeting 2021.

Pathways to Fellowships

Attendance at chapter meetings can help all ACP members meet the qualifications for advancement to Fellowship. It is especially important for those applying under the pathway that calls for five years of activity as a member.

Governor

Samuel Evans, MD, FACP - Assistant Clinical Professor, Department of Medicine, University of Hawai'i and Hawai'i Pacific Health, Honolulu, HI
ACP Governor, Hawai'i Chapter
Email: samevansmd@gmail.com

Program Committee

Program Chair:

Kuo-Chiang Lian, MD, Assistant Professor, Department of Medicine, University of Hawai'i and Queen's Medical Center, Honolulu, HI

Committee:

Mary Ann Antonelli, MD, FACP - Clinical Professor, Department of Medicine, University of Hawai'i and Veterans Affairs, Honolulu, HI

Surhbi Bansil, MS4 – 4th year Medical Student, John A. Burns School of Medicine, University of Hawai'i, Honolulu, HI

S. Kalani Brady, MD, MACP - Associate Clinical Professor, Department of Native Hawaiian Health, University of Hawai'i, Honolulu, HI

Joel Brown, MD, FACP - Clinical Professor, Department of Medicine, University of Hawai'i, Honolulu, HI

Lisa Camara, MD, FACP - Assistant Clinical Professor, Department of Medicine, University of Hawai'i and Physician at Kaiser Permanente, Honolulu, HI

Shirley Cheng, MS3 – 3rd year Medical Student, John A. Burns School of Medicine, University of Hawai'i, Honolulu, HI

Elizabeth Doman, MD - Chief Medical Resident, Tripler Army Medical Center, Honolulu, HI

Nathainal Enriquez, MD – Chief Medical Resident, University of Hawai'i Internal Medicine Residency Program, Honolulu, HI

James Epure, MD, FACP - Associate Clinical Professor, Department of Geriatrics, University of Hawai'i and Kuakini Medical Center, Honolulu, HI

Alvin Furuike, MD, MACP - Clinical Professor, Department of Medicine, University of Hawai'i and Queen's Medical Center, Honolulu, HI

Robert Gluckman, MD, MACP - Chief Medical Officer for Providence Health Plans, Portland, OR, Emeritus Treasurer, American College of Physicians; Former Board of Regents member for American College of Physicians (ACP), Philadelphia, PA

Donald Helman, MD, FACP - Associate Clinical Professor, Department of Medicine, University of Hawai'i and Kaiser Permanente, Honolulu, HI

Florence Kan, MD - Chief Medical Resident, UH Internal Medicine Residency Program, Honolulu, HI

Jennifer Katada, MD - Assistant Clinical Professor, Department of Medicine, University of Hawai'i and Kaiser Permanente, Honolulu, HI

Stephen Kemble, MD - Assistant Clinical Professor, Department of Medicine, University of Hawai'i and Retired, Honolulu, HI

Diana Kim, MD - Assistant Clinical Professor, Kaiser Permanente, Honolulu, HI

Andrew Kinimaka, MD – Chief Medical Resident, Kaiser Permanente, Honolulu, HI
Kuo Lian, MD, FACP - Assistant Professor, Department of Medicine, University of Hawai‘i and Queen’s Medical Center, Honolulu, HI
Evan Lum, MS4 – 4th Year Medical Student John A. Burns School of Medicine, University of Hawai‘i, Honolulu, HI
Ashley Morisako, MD – Chief Medical Resident, Kaiser Permanente, Honolulu, HI
Ryon Nakasone, MD, FACP – Assistant Professor, Department of Medicine and the Queen’s Medical Center, Honolulu, HI
Yoshito Nishimura, MD – 2nd Yr Resident UH Internal Medicine Residency Program, Honolulu, HI
Uzoagu Okonkwo, MD, PhD - Chief Medical Resident, Tripler Army Medical Center, Honolulu, HI
Janet Onopa, MD, FACP – Assistant Clinical Professor, Department of Medicine, University of Hawai‘i and Retired, Honolulu, HI
Abby Pandula, MD, - Assistant Clinical Professor, Department of Medicine, University of Hawai‘i and Kaiser Permanente, Honolulu, HI
Florian Sattlemachier, MD, FACP – Assistant Clinical Professor, Department of Medicine, University of Hawai‘i, Honolulu, HI
Kasey Tamamoto, MS4 – 4th year Medical Student, John A. Burns School of Medicine, University of Hawai‘i, Honolulu, HI
Philip Verhoef, MD, FACP – Assistant Clinical Professor, University of Hawai‘i and Kaiser Permanente, Honolulu, HI
William Wadzinski, MD, FACP - Tripler Army Medical Center, Honolulu, HI
James Yess, MD, FACP – Assistant Professor, Department of Medicine, University of Hawai‘i, Honolulu, HI
Gene Yoshikawa, MD – Chief Medical Resident, UH Internal Medicine Residency Program, Honolulu, HI

Faculty

Debleena Dutt, MD – Debleena Dutt is an advanced heart failure and transplant cardiologist from Kaiser Permanente in Hawaii. She did her advanced heart failure training at Stanford University and then subsequently helped to build the Left Ventricular Assist Device (LVAD) program at Swedish Hospital in Seattle. She joined Kaiser 3 years ago and is passionate about improving heart failure outcomes.

Robert Gluckman, MD, MACP - Dr. Robert Gluckman has served in a variety of leadership positions with Providence. Prior to becoming chief medical officer for Providence Health Plans in December 2010, Dr. Gluckman served as chief medical officer for the teaching clinics at Providence Medical Group. He served on the faculty for Providence St. Vincent Internal Medicine Residency for 18 years, where he maintained an active internal medicine practice. Throughout his academic career he has focused on applying medical evidence to clinical practice, with an emphasis on increasing the value of care delivered to patients.

Dr. Gluckman graduated summa cum laude in 1978 from the University of Illinois and earned his medical degree in 1982 from the University of Chicago. He completed his residency at Michael Reese Hospital in Chicago and is board certified in internal medicine.

Dr. Gluckman is Treasurer Emeritus of the American College of Physicians and served on the Board of Regents for the American College of Physicians (ACP), the nation’s largest physician specialty society. He brings a strong background in advocacy and public policy to his current role. He is past chair of the ACP’s Medical Practice and Quality and ACP Services Political Action Committees. He received the ACP Oregon Chapter’s Laureate Award in 2013 for his contributions to the internal medicine community. He is

currently the American Health Insurance Plan's Liaison to the Center of Disease Control's Advisory Committee on Immunization Practices (ACIP), a member of the Board of the Oregon Medical Association and serves on the board for Stand for Children.

Sarah Kemble, MD – Dr. Kemble received her MD at UCSF, completed her residency in Internal Medicine and Pediatrics at UCLA, and an infectious disease fellowship at Rush University Medical Center. She also is an alumna of the Epidemic Intelligence Service at the Centers for Disease Control and Prevention. After serving as Medical Director for the Communicable Disease Program at the Chicago Department of Public Health for four years, she returned to her home state of Hawai'i in March 2019 and joined the Hawai'i State Department of Health. Since September, 2020, she has served as the Acting State Epidemiologist and Chief of the Disease Outbreak Control Division.

Marjorie Mau, MD, MACP – Dr. Mau is a graduate of Kalani High School and Creighton University, where she earned her undergraduate and medical degrees. She also holds a Master's degree from the Harvard School of Public Health. She is Principal Investigator and Director of the Center for Native and Pacific Health Disparities Research, and holds the Myron P. Thompson Endowed Chair for Native Hawaiian Health at the University of Hawai'i medical school. She was the first Native Hawaiian female endocrinologist, and founding Chair of the Department of Native Hawaiian Health at JABSOM.

Dr. Mau's is one of a handful of elite members of a very exclusive community of faculty physicians to receive the rank of Mastership. She joins John A. Burns School of Medicine: S. Kalani Brady, MD, Jeffrey Berenberg, MD, Alvin Furuike, Robert Gluckman, MD; and the late JABSOM physician faculty member Irwin Schatz, MD, to achieve the rank of Mastership.

Daniel Moreno, MD - Dr. Daniel Moreno currently serves as an addiction medicine specialist for Kaiser Permanente Hawaii, caring for patients both in the outpatient setting and consulting on hospitalized patient with a wide range of substance use issues. He has been helping establish the new department of addiction medicine, which will soon expand into resident education.

Dr. Moreno earned his undergraduate degree and master's in business administration from Embry-Riddle Aeronautical University, where he received a private pilot's license and specialized in airline management. He earned his medical degree from the Universidad Autonoma de Gualadajara in Mexico, after which he returned home to Hawaii and completed residency at Kaiser Permanente's internal medicine residency program and fellowship at the University of Hawaii. He is board certified in internal medicine and addiction medicine. Dr. Moreno is a fellow of the American society of addiction medicine, which represents over 6,000 physicians, clinicians and associated professional in the field of addiction medicine.

Doctor's Dilemma -

Elizabeth Doman, MD - Chief Medical Resident, Tripler Army Medical Center, Honolulu, HI

Nathanial Enriquez, MD – Chief Medical Resident, UHIMRP, Honolulu, HI

Florence Kan, MD, MD - Chief Medical Resident, UHIMRP, Honolulu, HI

Andrew Kinimaka, MD – Chief Medical Resident, Kaiser Permanente, Honolulu, HI

Ashley Morisako, MD - Chief Medical Resident, Kaiser Permanente, Honolulu, HI

Uzoagu Okonkwo, MD, PhD – Chief Medical Resident, Tripler Army Medical Center, Honolulu, HI

Gene Yoshikawa, MD – Chief Medical Resident, UHIMRP, Honolulu, HI

New Fellows/Master -

Alvin N. Furuike, MD, MACP – **one of five*

Shiuh-Feng Cheng, MD, FACP
Jennifer M. Katada, MD, FACP
Sian Yik Lim, MD, FACP
Travis Watai, MD, FACP

2023 ACP Hawai‘i Awards

Advocacy Award

Phil Verhoef, MD, FACP

Community Based Teaching Award

Robin Seto, MD, FACP

Community Support Award

Jim Ireland, MD

Distinguished Teacher/Mentor Award

Dominic Chow, MD

Fostering Diversity Award

Irina R. Crook, MD, FACP
Marcus Kawika Iwane, MD
Craig Nakatsuka, MD, FACP

Early Career Physician

Maj. Danny Harris, MD
Abhinetri Pandula, MD

Educator Award

Masayuki Nogi, MD, FACP

Woman Physician of the Year

Sarah Kemble, MD


In Memoriam

James E. Hastings, MD, FACP
July 4, 2022



William “Bill” Thomas, MD
September 4, 2022

Clayton Chong, MD
November 23, 2022



Noa Emmett Aluli, MD
December 2, 2022

2023 ACP Meeting Schedule

7:50 a.m. (10 minutes)

Governor's Welcome

Samuel J. Evans, MD, FACP

Program Chair

Kuo-Chiang Lian, MD, FACP

8:00 a.m. (60 minutes)

Session #1 – “Heart Failure/SGLT2” -

Debleena Dutt, MD

9:00 a.m. (30 minutes)

Podium Presentations (2)

Moderator: #1 Mary Ann Antonelli, MD, FACP

9:00 a.m. – “Platelet Receptor Blockade After Clopidogrel Differs in Hawaii Patients with CYP2C19 Polymorphisms” – Joo Won Choi, BA

9:15 a.m. – “Phenobarbital for Alcohol Withdrawal: Systematic Review” – Horyun Choi, MD

9:30 am - 10:30 a.m. (60 minutes)

Session #2 – “Addiction Medicine Updates”

Daniel A. Moreno, MD

10:30 a.m. – 10:45 a.m. (15 minutes)

Break/Poster Viewing

10:45 a.m.

Podium Presentation (2)

Moderator: #2 James Epure, MD, FACP

10:45 a.m. – “Profound hypomagnesemia in a patient treated with long-term proton pump inhibitor” – Chinnawat Arayngkool, MD

11:00 a.m. – “The Taming of the Shrewd Helminth: Diagnosing Severe Colonic Trichuriasis” – Brendon Martino, DO

11:15 a.m. (60 minutes)

Session #3 - “Updates in Internal medicine – Best Articles of the Year” –

Robert Gluckman, MD, MACP

12:15 pm (60 minutes)

Session #4 - Dr. Irwin J. Schatz, MD, MACP

Lecture/ship –

“Updates on Health Inequities Among Asian Americans, Native Hawaiians and Pacific Islanders for (Busy) Internal Medicine Physicians (and How We Can Make a Difference!)

Marjorie Mau, MD, MACP

1:15 p.m. (30 minutes)

Business Meeting/Lunch/Poster Viewing

1:45 p.m. (30 minutes)

Podium Presentation (2)

Moderator: #3 Janet Onopa, MD, FACP

1:45 p.m. - “Validation of the Edmonton Frail Scale-Acute Care in patients ≥ 65 years undergoing surgery” – Eduardo Biala, BS

2:00 p.m. – “Improving Communication Skills Amongst Clinicians Through Formal Evidence Based Training” – Gull Mahvish, MD

2:15 p.m. (60 minutes)

Session #6 – “Hawai’i Long COVID” -

Sarah Kemble, MD

3:15 p.m. – 3:30 p.m. (15 minutes)

Break/Poster Viewing

3:30 p.m. (30 minutes)

Podium Presentation (2)

Moderator: #4 Lisa Camara, MD, FACP

3:30 p.m. – “Long COVID – A cross-sectional study exploring the prevalence of post SARS-CoV-2 infection symptoms and functional limitations I” – Helena Holmgren, MD

3:45 p.m. – “The Role of Biomarkers in Predicting High Flow Nasal Cannula (HFNC) Success in COVID-19 ARDS” - Andrew Pham, MD

4:00 p.m. – (30 minutes)

Break/Poster Viewing

4:30 p.m. (30 minutes)

Abstract Winners/Awards Presentation/Networking

5:00 p.m. – Doctor’s Dilemma

Chief Medical Residents

PODIUM PRESENTATIONS

9:00 am Podium

PLATELET RECEPTOR BLOCKADE AFTER CLOPIDOGREL DIFFERS IN HAWAII PATIENTS WITH CYP2C19 POLYMORPHISMS

Jan Aurelio, BA¹, Susan Asai, MSN¹, Joo Won Choi, BA², Stacy C. Brown, MD^{1,2}

¹The Queen's Medical Center, Neuroscience Institute, Honolulu, HI

²University of Hawaii, John A Burns School of Medicine, Dept of Medicine, Honolulu, HI

Background: Patients with minor ischemic stroke (IS) or high-risk transient ischemic attack (TIA) are often treated with dual antiplatelet therapy consisting of clopidogrel and aspirin to reduce the risk of recurrent stroke. Polymorphisms in the CYP2C19 gene contribute to significant inter-individual variability in drug response and are of higher frequencies in Asian populations. However, collecting information on CYP2C19 allele status or other markers of medication response to ensure efficacy of treatment has not been widely adopted as standard of care. To inform quality improvement initiatives at our institution, which serves a population of largely Asian descent, we reviewed records of a sample of patients treated with clopidogrel to explore the relationship between VerifyNow P2Y12 reaction units (PRU) and CYP2C19 loss-of-function mutations.

Methods: We performed a single-center, retrospective cross-sectional study of adult patients treated with dual antiplatelet therapy for IS or TIA in 2019 and 2020. Patients who underwent VerifyNow P2Y12 assay testing 4-24 hours after clopidogrel loading as well as CYP2C19 genotyping were identified. Data was collected on basic demographic and medical variables in addition to the laboratory results of interest. Descriptive statistics were used to compare patient characteristics between those with and without CYP2C19 loss-of-function alleles. PRU were categorized as either demonstrating platelet inhibition or not, according to three different thresholds. For each defined threshold, sensitivity and specificity of the P2Y12 assay as a proxy for CYP2C19 loss-of-function were calculated.

Results: 43 patients who underwent both P2Y12 receptor blockade testing and CYP2C19 genotyping were identified (mean age 68 [SD 10.9], female n=17 [40%]). When stratified by CYP2C19 allele status, no significant differences were found between groups except for platelet receptor blockade ($p=0.046$), as defined by a threshold of 180 PRU. The calculated sensitivity of PRU >180 for CYP2C19 loss-of-function alleles was 65% and specificity was 70%. Lowering the receptor blockade threshold to PRU of 170 yielded an increase in sensitivity to 74% with no changes to specificity. Inadequate platelet receptor blockade defined as PRU > 150 provided a sensitivity of 78% while specificity remained unchanged.

Conclusion: In a sample of limited size, inadequate platelet receptor blockade after clopidogrel loading as measured by the VerifyNow P2Y12 assay was significantly associated with CYP2C19 loss of function. The sensitivity of the P2Y12 assay as a proxy for genotyping was limited but improved with lower PRU definitions for receptor blockade, and may be affected by sample size and/or unmeasured confounders. These results support larger studies based on protocolized PRU and genotype testing in our population, to inform cost-effective practices to ensure treatment efficacy.

9:15 am Podium

PHENOBARBITAL FOR ALCOHOL WITHDRAWAL: SYSTEMATIC REVIEW

Horyun Choi, MD¹, Yoshito Nishimura, MD¹, Bridget Colgan, MD²,
Harrison Kistler, MD², and Francisco Mercado, MD^{1,2}

¹University of Hawaii Internal Medicine Residency Program, Honolulu, HI

²Department of Medicine, Tripler Army Medical Center, Honolulu, HI

Background:

In recent years, phenobarbital (PB) has been more recognized as a potential alternative to benzodiazepine (BDZ), which may be beneficial for reduced hospital length of stay and lower complications related to alcohol withdrawal syndrome. However, the level of evidence has been unclear. We aim to explore the evidence of use of PB in alcohol withdrawal syndrome (AWS) via systematic review and provide insights into future research directions.

Methods:

We searched MEDLINE, EMBASE, ClinicalTrials.gov, and WHO ICTRP for observational or interventional studies that compared use of PB monotherapy or adjunct PB along with BDZ to BDZ monotherapy in AWS from inception to September 18, 2022. We followed the PRISMA guidelines for study selection.

Results:

We included 20 studies which consist of two double-blind, randomized trials and 18 retrospective studies. Among the studies, 9 studies including the two clinical trials were performed in the ED and 11 studies were performed in either general floors or ICU. 5 studies and 8 studies compared use of PB monotherapy to BDZ monotherapy in the ED and either general floors or ICU, respectively. Outcomes used in these studies vary, including intubation rates, need of mechanical ventilatory support, admission rates, and length of stay. Of note, three studies in the ED demonstrated better outcomes in admission rates showing less admission in PB monotherapy groups compared with BDZ monotherapy groups. In addition, PB monotherapy groups have lower mortality rates compared to BDZ monotherapy groups in three general floors or ICU cohorts. However, the studies included in this review were not qualified for meta-analysis due to significant heterogeneity regarding PB dosing, measured outcomes, and AWS severity measurement scales.

Conclusion:

Use of PB in AWS has been focused as a promising alternative to BDZ. Evidence has been emerging that PB may be related to better clinical outcomes compared to BDZ. Future prospective studies would be beneficial for standardization of PB use in AWS.

10:45 am Podium

PROFOUND HYPOMAGNESEMIA IN A PATIENT TREATED WITH LONG-TERM PROTON PUMP INHIBITOR

Chinnawat Arayangkool, MD¹, Joseph Lee, MD¹, Kuo-Chiang Lian, MD, FACP²

¹University of Hawai'i Internal Medicine Residency Program, Honolulu, HI

²The Queen's Medical Center, Honolulu, HI

Learning Objectives: Review clinical signs and symptoms of profound hypomagnesemia
Recognize proton pump inhibitors as a rare contributor to clinically consequential hypomagnesemia

Case Presentation: A 83-year-old man with gastritis treated with omeprazole and recent acute lacunar stroke presented to the hospital with intractable nausea and vomiting. One week prior to admission, he was admitted with intractable nausea, vomiting, and aphasia. MRI brain revealed an acute to subacute lacunar infarction in the left corona radiata. During hospitalization, his nausea and vomiting was refractory to antiemetic treatment but resolved by the time of discharge. Additionally, he had no residual neurological deficits on discharge. Shortly after discharge, he had recurrence of intractable nausea and vomiting which did not improve with oral antiemetic medication. He had no fever, chills, abdominal pain, changes in stool pattern, or neurologic symptoms.

On presentation, his vitals were normal. Physical exam was unremarkable including a normal abdominal exam and neurological exam. Laboratory testing showed profound hypomagnesemia with serum magnesium less than 0.2 mg/dL. Other electrolytes were unremarkable except for hypokalemia and hypocalcemia. CT abdomen/pelvis with contrast showed gastric wall thickening and cholelithiasis without evidence of cholecystitis. Subsequent esophagogastroduodenoscopy failed to identify a gastrointestinal cause for vomiting. Repeat MRI brain did not reveal a central cause of vomiting.

The patient was treated with multiple doses of IV magnesium sulfate and oral magnesium oxide with prompt improvement of symptoms. However, his serum magnesium level remained persistently low. Urine magnesium indicated increased renal excretion, however this was tested in the setting of ongoing magnesium replacement. After reviewing his medications further, omeprazole was discontinued and replaced with famotidine with subsequent stabilization of magnesium level.

Discussion: The presentation of hypomagnesemia can vary widely but may include nausea, vomiting, arrhythmias, muscle cramping, and paresthesias. Hypomagnesemia is a rare side effect of chronic proton pump inhibitor (PPI) usage. The risk of hypomagnesemia increases with the duration of treatment. It is thought that increased pH within the small bowel leads to decreased affinity of magnesium binding to active magnesium transport channels, such as transient receptor potential melastatin (TRPM) cation channels. Variant alleles of the TRPM6/TRPM7 genes are associated with malabsorption which might be further aggravated by the use of a PPI. Thus only those with genetic predisposition are severely affected, which contributes to the rarity of this adverse effect. This case highlights the importance of careful medication review in patients presenting with symptomatic hypomagnesemia, with consideration of long-term PPI therapy as a rare potential cause.

Conclusion: Nausea and vomiting can be the early signs of hypomagnesemia
Long-term proton pump inhibitors can increase the risk of hypomagnesemia

11:00 am Podium

**THE TAMING OF THE SHREWD HELMINTH: DIAGNOSING
SEVERE COLONIC TRICHURIASIS**

Brendan Martino, DO¹ and Pedro Manibusan, MD²

¹Department of Medicine Training Program, TAMC, Honolulu, HI

²Department of Medicine, TAMC, Honolulu, HI

Introduction:

Helminthic infections are very common worldwide. Common nematode infections include Enterobiasis vermicularis (pinworm) and Trichuris trichiura (whipworm). These are very common especially amount children and travelers to tropical climates. Infection is usually acquired via fecal-oral transmission of parasite eggs which then hatch and mature in the GI tract before being excreted in the feces to infect a new host. Patients can be asymptomatic or present with abdominal cramping, diarrhea, dysentery, and pica depending on disease burden.

Case Presentation:

22-year-old female without significant past medical history presenting with four days of abdominal pain and cramping with associated dark diarrhea. She just returned from a three-week trip to Indonesia. She was initially seen by her PCM and treated for traveler's diarrhea with azithromycin. Her diarrhea continued to worsen, and she went to the ED and diagnosed with gastroenteritis and discharged with Imodium. CT abdomen/pelvis was unremarkable. Lab work revealed leukocytosis with significant eosinophilia, and she was sent for stool culture as well as ova and parasite testing which were subsequently negative. However, she was found to have blood in her stool and was referred to GI for endoscopy. Ova and parasite testing was repeated by GI and was negative. She was also found to have worsening leukocytosis and eosinophilia. Upper endoscopy was performed which did not reveal signs of upper GI bleed. She then underwent colonoscopy which revealed copious parasitic worms throughout the colon most concentrated in the cecum and ascending colon with mucosal inflammation. Biopsies were obtained and sent for parasite identification. Given the location and endoscopic appearance of the parasite, Trichuriasis (whipworm) was suspected, and she was treated with three days of albendazole. She responded well to treatment with improvement in her symptoms, resolution of her leukocytosis and eosinophilia.

Discussion:

There are many types of parasitic infections that can present with varying degrees of symptom severity making diagnosis difficult. Symptom onset is often delayed from time of infection by several weeks to months as well. This can further be complicated by the fact that laboratory testing such as ova and parasite as well as advanced imaging studies can often be negative such as this in case. Travel history in the setting of new eosinophilia is key for raising suspicion of helminthic infections and prompting further diagnostic evaluation with PCR and endoscopy for definitive diagnosis. Treatment is tailored to the particular parasitic infection. Common therapies include albendazole, mebendazole and ivermectin which can treat a wide variety of parasitic infections. Good hygiene and proper food preparation practices are also very important in interrupting the cycle of transmission with these parasites and should be stressed to patients, particularly those infected or traveling to endemic areas.

**VALIDATION OF THE EDMONTON FRAIL SCALE-ACUTE CARE
IN PATIENTS ≥ 65 UNDERGOING SURGERY**

Eduardo B. Biala, Jr., BS¹, April L. Ehrlich, MD, Oluwafemi Owodunni, MD,

Dianne Bettick, MSN, CNS RN, and Susan L. Gearhart, MD, FACS

¹University of Hawai'i, John A. Burns School of Medicine, Honolulu, HI

²Johns Hopkins University School of Medicine, Division of Geriatrics, Baltimore, MD

³Johns Hopkins Bayview Medical Center, Baltimore, MD

⁴Johns Hopkins University School of Medicine Department of Surgery, Baltimore, MD

Background:

Frailty is common in geriatric surgical populations (37%), and associated with poor postoperative outcomes. The Edmonton Frail Scale (EFS) is a frailty assessment that has been previously validated in geriatric surgical populations. The Edmonton Frail Scale-Acute Care (EFS-AC) is a newly developed version where the Clock Draw and Timed Get Up and Go Test were replaced with self-reported questions. The EFS-AC has not been validated in the surgical population. Our aim was to validate the EFS-AC for use in geriatric surgical patients.

Methods: This is a single-institution prospective cohort study of patients ≥ 65 years undergoing preoperative assessment with the EFS and EFS-AC prior to elective surgery from 10/2021 to 10/2022. EFS and EFS-AC ≥ 6 was considered frail. Procedural variability was controlled for using the operative stress score. Patients undergoing procedures not assigned an OSS were excluded. Outcomes of interest were loss of independence (LOI), length of stay (LOS), ICU stay, and ICU LOS. Univariable and multivariable analyses were performed. Receiver operating characteristic (ROC) curves were generated to estimate discriminatory thresholds for all outcomes of interest.

Results:

688 patients were included. 122 (18%) were frail by EFS and 112 (16%) were frail by EFS-AC. The EFS-AC was associated with increased odds for all outcomes of interest: increased risk for LOI (OR 4.34 [4.05, 4.65]), longer LOS (OR 1.23 [1.09, 1.39]), ICU admission (OR 1.48 [1.26, 1.73]), and longer LOS in the ICU (1.57 [1.23, 2.02]). EFS was similarly significantly associated with increased odds for all outcomes of interest. ROC analysis showed that the EFS-AC performed similarly to the EFS in predicting all outcomes of interest with the greatest sensitivity and specificity for predicting LOI.

Conclusion:

The EFS-AC is a valid frailty assessment for predicting poor postoperative outcomes in geriatric surgical patients and performs similarly to the previously validated EFS. This tool requires no physical assessments and can be performed quickly in an emergent setting, making this a valid option for expanding preoperative frailty assessments into emergency surgery.

2:00 pm Podium

IMPROVING COMMUNICATION SKILLS AMONGST CLINICIANS THROUGH FORMAL EVIDENCE BASED TRAINING

Gull Mahvish, MD¹; Gerri Sylvester, MD; Mohammed Ali, MD¹; Monica Orcine, MD; Susan Christensen, MD; Kellie Kurasaki, MD; Angela Lo, MD; Miquela Ibrao, MPH, MSW; Aida Wen, MD^{1,2}; Cody Takenaka, MD^{1,2}; Brita Aramaki, MD^{1,2}; Kamal Masaki, MD^{1,2}

¹University of Hawai'i, John A. Burns School of Medicine, Dept of Geriatric Medicine, Honolulu, HI

²Queen's University Medical Group, Honolulu, HI

Objective: To conduct a quality improvement project assessing whether training using VitalTalk will improve knowledge, skills, and attitudes on communicating with patients and families about serious illness.

Background: Empathic, honest communication between physicians and patients/families is the foundation of shared decision making and patient centered care. Only 14% of physicians report advance care planning discussions with patients and over 60% report they have never received formal training. Multiple models of training exist. VitalTalk provides evidence-based training using simulated patients to train clinicians how to communicate effectively with seriously ill patients and their families.

Methods: All geriatricians (N=22) at the Queen's University Medical Group and University of Hawaii received 4-hour VitalTalk training (July to September 2022) via Zoom or web-based training. After training, geriatricians evaluated the workshop, and completed a retrospective pre-post survey related to skills and comfort level with different communication skills. Additional resources from VitalTalk were provided. Efficacy and incorporation of learned skills into practice will continue to be evaluated at 1 and 3-month follow-up. Data from baseline and 1-month follow-up were analyzed using descriptive statistics and paired t-tests, comparing differences between pre and post scores.

Results: All participants (100% response rate) completed evaluations. Evaluation scores were rated on a 5-point Likert Scale: 1=poor, 5=excellent. Baseline mean scores on quality of training were high (range 4.45 to 4.95). Aretrospective pre-post questionnaire showed significant improvements in skills in discussing clinical status (3.68 to 4.14, $p=0.004$), goals of care (3.73 to 4.18, $p=0.0018$) and advance care planning (3.82 to 4.23, $p=0.0038$). Results were similar in comfort levels in discussing these subjects. There were also significant improvements in self-assessment of communication skills across eight domains: assessment of patient knowledge ($p=0.0004$), giving a headline ($p<0.0001$), responding to patient's emotions ($p=0.0002$), aligning with patient's hopes and sharing concerns ($p=0.0002$), managing uncertainty and conflict ($p<0.0001$), promoting prognostic awareness ($p=0.0018$), eliciting patient's goals and values ($p=0.0038$), and recommending treatment to support values ($p=0.0106$). At 1-month follow-up, 18/22 (82%) had used skills gained from training and continued to rate the training highly.

Conclusion: Communication skills are crucial for clinicians to provide patient centered care. Early results suggest that formal evidence-based training improves skills and comfort levels in communicating about serious illness with patients and families. We plan additional PDSA cycles to increase long-term use of these skills.

3:30 pm Podium

LONG COVID – A CROSS-SECTIONAL STUDY EXPLORING THE PREVALENCE OF POST SARS-COV-2 INFECTION SYMPTOMS AND FUNCTIONAL LIMITATIONS I

Helena Holmgren, MD¹; Kathryn Choo Loy, MD¹;
Abhinetri Pandula, MD¹; Elaine Doi, MD¹; Robin Seto, MD, FACP¹
¹Kaiser Permanente Hawaii Internal Medicine Residency Program

Background:

While most people with COVID-19 infection recover after an acute illness, some people have lingering or new symptoms that can last weeks to months. It is estimated that at least one in five Americans who have had COVID-19 infection will develop these long COVID symptoms. The post-acute sequelae of the SARS-CoV-2 condition defined by the CDC is characterized by a wide range of new, ongoing, or returning symptoms due to COVID-19 infection that last 4 weeks or longer.

Methods:

We conducted a cross sectional study to collect data on Native Hawaiian, Pacific Islander and other minority populations on Oahu to understand more about the prevalence of certain symptoms, the severity of these symptoms, and its impact on functional status. From 10/2021 through 10/2022, a convenience sample of patients with prior COVID-19 infection with engagement at one outpatient primary care clinic were recruited to complete a written survey.

Results:

Of the 100 patients that completed the survey, based on their electronic health record data, 28% self-identified race/ethnicity was Native Hawaiian/Other Pacific Islander, 24% Caucasian, 21% Filipino, 8% Japanese, 6% Chinese, 5% Hispanic/Latino, 2% Indian, 2% Korean, 2% Mixed, 1% Vietnamese, and 1% Black. Four or more weeks after initial COVID-19 infection symptom onset, 67% of patients identified one or more ongoing symptom. Of patients that reported long COVID symptoms, 74.6% reported no or negligible functional limitation, 20.9% reported slight functional limitation, and 4.5% reported moderate to severe functional limitations. The most frequently reported symptoms were fatigue (28%), brain fog (26%), insomnia (23%) and muscle/joint pain (21%). Of patients reporting long COVID symptoms and of those reporting functional limitations, the race/ethnicity distribution mirrored that of the overall study population.

Conclusions:

Among the diverse population of Hawaii, we confirm that post-acute sequela of COVID-19 infection impacts our patients. More studies are needed to describe the long-term effects of COVID-19 infections particularly among groups that suffer from poor health outcomes including Native Hawaiians and Other Pacific Islanders.

**THE ROLE OF BIOMARKERS IN PREDICTING HIGH FLOW
NASAL CANNULA (HFNC) SUCCESS IN COVID-19 ARDS**

Andrew Pham, MD¹, Koichi Keitoku, MD¹, and Reid Ikeda, MD, FACP, FCCP^{1, 2}

¹University of Hawaii Internal Medicine Residency Program, Honolulu, HI

²The Queen's University Medical Group, Pulmonary and Critical Care, Honolulu, HI

Background: COVID-19 infection can cause severe pneumonia and acute respiratory distress syndrome (ARDS), which is associated with high mortality. Treatment with HFNC can reduce the need for mechanical ventilation and ICU admission. However, factors predicting the success of HFNC at the time of initiation have not been well-characterized. Elevations in serum biomarkers such as C-reactive protein (CRP) and D-dimer have been associated with worse outcomes in COVID-19 infection, but few studies have assessed the predictive value of these biomarkers for successful management with HFNC.

Objective: To determine if CRP, D-dimer, and Ferritin are associated with successful treatment with HFNC in patients with acute hypoxemic respiratory failure due to COVID-19.

Method: We retrospectively studied 432 consecutive patients who were admitted to the Queen's Medical Center from August 2020 to October 2022 and treated with HFNC for acute hypoxemic respiratory failure due to COVID-19 pneumonia. Patients designated as "Do Not Intubate" status or on HFNC for post-extubation respiratory failure were excluded. Measurements of CRP, D-dimer, and Ferritin near the time of HFNC application were compared in patients who were intubated and those who were not intubated, using the Wilcoxon rank-sum test.

Result: A total of 329 patients were included in the final analysis. 44% (n=145) were successfully managed with HFNC, while 56% (n=184) were intubated. The median Ferritin was 1666 for the non-intubated group and 1738 for the intubated group (p=0.3). The median CRP was 68 for the non-intubated group and 88 for the intubated group (p=0.021). The incidence of DVT or PE was high (11% of patients who were not intubated and 19% of those who were intubated), and when these patients were excluded, the median D-dimer was 0.93 for the non-intubated group (n=129) and 1.18 for the intubated group (n=129) (p=0.021). In-hospital mortality was 37% (4.8% in the non-intubated group and 62.5% in the intubated group).

Conclusions: To our knowledge, this is the largest study reviewing the relationship between HFNC success and these serum biomarkers in COVID-19 patients. There are statistically significant differences in CRP and D-dimer when comparing those who were successfully managed with HFNC and those who were intubated. There is a large mortality difference between these groups, and CRP and D-dimer levels may help to identify patients who can be successfully treated with HFNC, and those at higher risk for intubation. This is important as patient self-inflicted lung injury (P-SILI) can occur with prolonged HFNC use before lung protective ventilation is initiated.

POSTER PRESENTATIONS

WUNDERLICH SYNDROME: WONDERING HOW IT HAPPENS

Noppawit Aiumtrakul, MD¹, Bryce Tanaka, MD¹ & Travis Watai, MD, FACP²

¹University of Hawaii Internal Medicine Residency Program, Honolulu, HI

²The Queen's Medical Center, Honolulu, HI

Learning Objectives: - Recognize the clinical presentation of Wunderlich Syndrome
- To consider appropriate management of Wunderlich Syndrome

A 56-year-old man with paroxysmal atrial fibrillation on rivaroxaban presented with sudden onset sharp left-sided flank pain started while driving a car. There was radiation to the abdomen and back with associated diaphoresis. His past medical history was significant for a prior left middle cerebral artery occlusion, type 2 DM, morbid obesity status post bariatric surgery, HFrEF, and hypertension. The patient denied recent history of trauma, hematuria, kidney stone, kidney tumor, urinary symptoms, weight loss or fever. He was compliant with rivaroxaban for stroke prevention.

Vital signs were hemodynamically stable. Physical exam was significant for severe tenderness over the left flank. Initial work-up showed hemoglobin of 15.0 g/dL, pyuria with WBC>100/HPF and microscopic hematuria with RBC of 6-20/HPF. CTA aortic dissection protocol illustrated a large left perinephric hematoma with several areas of active extravasation measuring approximately 12.2x12.1x16.1cm. This form of nontraumatic spontaneous perinephric hematoma is consistent with an uncommon clinical syndrome of Wunderlich syndrome.

The patient was in severe pain and required IV hydromorphone for adequate pain control. Urology was consulted and recommended conservative management given stable hemodynamics. With results of his urine culture showing a potential infectious culprit, the patient was started on ceftriaxone and switched to IV ertapenem when sensitivities showed ESBL producing E. coli. Over the next couple of days, his hemoglobin slowly downtrended but stabilized at 9.7 g/dL. Upon discharge, we recommended repeating a CT scan in 2-3 months to assess for possible underlying tumor.

Discussion: Wunderlich syndrome (WS) is a rare clinical syndrome defined by nontraumatic spontaneous renal hemorrhage. The majority of manifestations present with isolated flank pain and are often detected with a non-contrast CT scan. The classical presentation of WS is known as Lenk's triad, including acute flank pain, palpable flank mass, and hypovolemic shock. Renal neoplasms, vascular disease, cystic renal disease and anticoagulation should be considered as an underlying etiology of WS. Initial management includes fluid resuscitation with or without blood transfusion, reversal of anticoagulation, and treatment of sepsis or obstruction if present. Identification of active extravasation indicates need for intervention with embolization or surgery especially if the patient is hemodynamically compromised.

Conclusion:

- Wunderlich syndrome often presents with isolated flank pain and is often detected with a non-contrast CT scan.
- Initial management includes fluid resuscitation with or without blood transfusion, reversal of anticoagulation, and treatment of sepsis or obstruction if present.
- Active hemorrhage indicates the need for intervention.

CARDIAC AMYLOIDOSIS

Samer Al Daheen, MD¹ and Francisco Mercado, MD, FACP,²

¹Department of Medicine Training Program, TAMC, Honolulu, HI

²Department of Medicine, TAMC, Honolulu, HI

Background: Cardiac amyloidosis is previously thought to be a rare disorder characterized by the accumulation of extracellular misfolded protein at the myocardium (1). Cardiac manifestations include thrombogenesis, arrhythmias, conduction disorders, and restrictive cardiomyopathy (2). Involvement of the myocardium in a patient with systemic amyloidosis is a major factor in determining the patient's survival and has the worst prognosis (3-5).

Case Summary: Our patient is a 58-year-old Chamorro male with a past medical history of coronary artery disease status post-coronary artery bypass graft surgery in 2016. He presented for evaluation of exertional chest pain. In the ED, the patient had elevated troponin without STEMI on EKG. Coronary and graft angiography revealed patent grafts and unchanged native disease. The echocardiogram showed a maximum LV thickness of 31mm with eccentric septal wall thickening (1.6 cm at the base and 3.1cm apical septal wall) and grade III (restrictive) diastolic function. Compared to the 2012 echocardiogram, wall thickness is significantly increased. The patient was diagnosed with hypertrophic cardiomyopathy without outflow tract obstruction. Non-Genetic etiology was considered due to age and lack of family history. Serological assessment for infiltrative cardiomyopathy resulted in abnormal Kappa: Lambda ratio of 4.58 with an M spike.

Technetium pyrophosphate myocardial scan resulted in indeterminate for amyloidosis. A non-contrast cardiac MRI, limited by renal function, confirmed left ventricular asymmetric septal and apical wall thickening. Hematology recommended a combined approach of bone marrow and fat pad biopsy. The bone marrow biopsy yielded low-level kappa-restricted plasma cell neoplasm in a polyclonal plasma cell background and Congo red stain is focally positive within cartilage. Smoldering Multiple Myeloma is being considered. The fat pad biopsy was inconclusive with a negative Congo red stain due to a small tissue sample. Genotyping for hypertrophic cardiomyopathy variants was negative. Endocardial biopsy was recommended, and the patient was referred to a center of excellence for Cardiac Amyloidosis.

Discussion: The differentiation between HCM and cardiac amyloidosis is crucial since the prognosis varies. Despite better knowledge and advanced technology many cases with systemic amyloid who has cardiac involvement were diagnosed in advanced stages. Therefore, clinicians should be aware of and recognize this rare disease. A high clinical index of suspicion combined with a good knowledge of the diagnostic protocols will lead to a proper management

An increased left ventricular wall thickness of ≥ 1.5 cm should raise suspicion of hypertrophic cardiomyopathy vs infiltrative cardiomyopathies. Recent pharmacologic and technological advancements have changed the incidence rate of cardiac amyloidosis previously thought to be rare. A clinician should be aware of the expanded differential and diagnostic assessment to ensure proper management.

Keywords: Hypertrophic cardiomyopathy; cardiac amyloidosis; cardiac magnetic resonance imaging; cardiac nuclear imaging; junctophilin 2 associated cardiomyopathy; Restrictive cardiomyopathy; Acute coronary syndrome; Chronic chest pain.

References:

1. <https://pubmed.ncbi.nlm.nih.gov/35474404/>
2. <https://pubmed.ncbi.nlm.nih.gov/31986086/>
3. <https://doi.org/10.1186/1471-2458-12-974>
4. JACC 2022. 79 (13).
5. JACC CardioOnc. 2021. 3 (4) 488-505)

GRANULOMATOSIS WITH POLYANGIITIS: A CASE REPORT OF A GERIATRIC ASIAN/PACIFIC ISLANDER WITH INVOLVEMENT OF ONE ORGAN SYSTEM

Javier Barranco-Trabi, MD¹; Eun Ah Cho, BA²; Victoria Mank, MD¹;

Jefferson Roberts, MD³; William Wadzinski, MD, FACP⁴

¹Department of Internal Medicine, Tripler Army Medical Center, Honolulu, HI

²School of Osteopathic Medicine in Arizona, A.T. Still University, Mesa, AZ

³Dept of Medicine, Division of Rheumatology, TAMC, Honolulu, HI

⁴Dept of Medicine, Division of Pulmonology and Critical Care, TAMC, Honolulu, HI

Introduction:

Granulomatosis with polyangiitis (GPA), is a small-medium vessel ANCA-associated vasculitis. GPA is a rare pathology, prevalence being 30.5 cases per million person-years and the incidence being 12.8 cases per million person-years. Caucasians are predominantly affected. Per the 2022 American College of Rheumatology (ACR) and European Alliance of Associations for Rheumatology (EULAR) guidelines, a patient with a diagnosis of small-medium vessel vasculitis is classified as GPA if the cumulative score is ≥ 5 points yielding a sensitivity of 93% and a specificity of 94%. GPA has a classic triad of upper and lower respiratory tract symptoms, systemic vasculitis, and kidney involvement. We report a case of GPA, with a cumulative score of 7 points (ANCA + and pulmonary nodules/fibrosis) based on the ACR/EULAR criteria of diagnosis of GPA, presenting with solely pulmonary manifestations.

Case presentation:

A 91-year-old Pacific Islander male presented to the Emergency Room with progressive dyspnea, generalized weakness, cough, and hemoptysis. Laboratory findings were significant for BNP 176 pg/ml (< 100 pg/ml), hemoglobin 8.8 g/l (13.5-17.5g/l), PT 16.4, TIBC (200 mcg/dL), transferrin (190 mcg/dL), and iron (40 mcg/dL). CT angiography showed diffuse ground-glass opacities with fibrotic changes. Flexible bronchoscopy with subsequent bronchoalveolar lavage in the right middle lobe was positive for alveolar hemorrhage. Further testing revealed a positive C-ANCA, and a positive PR-3 antibody was confirmed. The patient was diagnosed with GPA per ACR guidelines. Per the 2021 ACR guidelines, prompt management of severe GPA includes glucocorticoids and rituximab. We classified the patient as having severe GPA based on his presentation with diffuse alveolar hemorrhage.

Discussion:

GPA has been traditionally described with a multi-system clinical presentation such as destructive sinusitis, nephritis, and disseminated vasculitis that is pathologically characterized by necrotizing granulomatous respiratory tract lesions, vasculitis, and glomerulonephritis. It is essential to consider that GPA can present in diverse ethnic patient populations and age groups. The average age of onset in adults is 50 years, while our patient was 91 years old. GPA predominantly affects Caucasians in 97% of patients, while our patient was Asian/Pacific Islander. A multidisciplinary approach is crucial for diagnosing GPA, especially in a patient with clinical findings of one organ system involvement. When considering a patient's age and morbidity associated with tissue biopsy, prompt recognition and treatment are imperative for this rapidly progressive condition regardless of tissue biopsy confirmation.

Poster #4

TB: A BRAIN CANCER LOOK-ALIKE

Karen Chang, MD¹, Stacie Nishimoto, MD² and Philip Verhoef, MD, FACP²

¹Kaiser Permanente Hawai'i Internal Medicine Residency Program, Honolulu, HI

²Hawaii Permanente Medical Group, Honolulu, HI

Introduction:

Hawaii has one of the highest TB rates in the country. Given its often insidious disease process and propensity to be overlooked or misdiagnosed, it is important to be wary of cases of TB that stray from the typical illness script.

Case description:

A 70-year-old woman with history of retroperitoneal pleomorphic liposarcoma with metastases to kidney, colon, adrenal gland, diaphragm, and lung, status post chemotherapy, radiation, and multiple surgical resections, initially presented with 2 weeks of right leg weakness and numbness. Physical exam showed mild weakness of the right hip and quadriceps, and decreased sensation to light touch at the right L2-3 dermatome. MRI of the lumbar spine showed chronic compression fractures at L2-3, multilevel degeneration, and no evidence of metastases. Brain MRI demonstrated abnormal pial enhancement along the left parietal lobe concerning for metastatic disease. Oncology agreed this was concerning for metastasis, however noted this was an unusual location. Confirmation via 3 serial lumbar punctures was ordered, and results were negative for malignant cells. Patient was then referred to neurosurgery for possible biopsy. Repeat MRI showed persistent findings with a few new foci of abnormal enhancement. Neurosurgery felt that the imaging was atypical for metastases to the brain and thus presented this case at tumor board. The consensus favored an inflammatory or infectious etiology over a tumor. Per shared decision making, patient elected for surveillance imaging over biopsy. Two months later, repeat brain MRI showed mildly progressed enhancement along the cortex and pia of the left parietal lobe. Patient was still hesitant about biopsy, and elected for PET-CT first, which showed no new FDG avid lesions. She then proceeded with open brain biopsy. At this time, the patient's symptoms had mildly progressed. Biopsy showed benign dura/leptomeninges, and necrotizing granulomatous inflammation. Infectious disease was consulted. While AFB brain culture was pending, interferon gamma release assay turned out positive. However, the patient did not have any respiratory symptoms, and PET-CT did not show new FDG avid lung lesions. AFB sputum culture was positive and AFB brain culture ultimately revealed positive MTB, and the patient was started on appropriate therapy. She reported symptom improvement on therapy, and repeat brain MRI showed improved meningeal thickening along the left posterior falx cerebri and less vasogenic edema.

Discussion:

This case illustrates the potential for TB to masquerade as metastatic brain cancer in an immunocompromised patient without classic respiratory symptoms. Although TB is generally uncommon, the TB burden in Hawaii is high and poses a serious risk in the immunocompromised population. Recognition is critical to appropriate therapy and prevention of further community spread.

Poster #5

MOBILITY DEVICE USE AND FRAILTY PROGRESSION IN COMMUNITY-DWELLING OLDER ADULTS WITH MOBILITY IMPAIRMENT

A. Chau, BS¹, D. Kim, MD², and S. Shi, MD²

¹University of Hawaii John A. Burns School of Medicine, Honolulu, HI

²Hinda and Arthur Marcus Institute for Aging Research, Boston, MA.

Background:

Frailty is associated with increased risk of disability and adverse health outcomes. While mobility devices are often prescribed for older adults with mobility limitations, the relationship between mobility device use on frailty progression over time remains unknown.

Methods: Participants were community-dwelling adults with mobility impairment (gait speed <0.8m/s or Short Physical Performance Battery (SPPB) <10) who participated in two consecutive years (2015 and 2016) of the National Health and Aging Trends Study, a nationally representative survey of Medicare beneficiaries 65 years and older. Mobility device users were defined as those who reported using a cane or walker in the month before the 2015 interview. Frailty status was defined based on a validated 40-item deficit accumulation frailty index (FI) measured in 2015: robust (<0.15), pre-frail (0.15 to <0.25), mildly frail (0.25 to <0.35), and moderate-to-severely frail (≥ 0.35). Change in frailty was calculated as the difference in FI from 2015 to 2016, categorized as worsening frailty (≥ 0.03) or stable/improved frailty (<0.03). Logistic regression was used to assess the association between mobility device use and 1-year worsening in frailty adjusting for age, sex, race, income, cohabitation status, and baseline frailty status. Secondary outcomes included falls and hospitalizations.

Results:

Of 4,067 older adults included in the analysis (56.5% female, 78.2% White, 25.6%, 26.0%, 20.8%, 14.5%, 9.3%, and 3.9% were ages 65-69, 70-74, 75-79, 80-84, 85-89, and ≥ 90 respectively), 1,196 (29.4%) used a mobility device. Among device users, the proportions of robust, pre-frail, mildly frail, and moderate-to-severely frail at baseline were 5.8%, 23.3%, 32.5%, and 38.4%, respectively. Overall, 496 (38.8%) of device users and 967 (30.2%) of non-device users experienced worsening frailty. Mobility device use was not associated with worsening frailty in the entire cohort (OR: 1.26, 95% CI: 0.95-1.68). However, once stratified by baseline frailty category, device use was associated with worsening 1-year frailty in pre-frail participants (OR: 1.62, 95% CI: 1.09-2.41). After full adjustment, device use was not associated with falls (OR: 1.16, 95% CI: 0.94-1.42) or hospitalizations (OR: 1.15, 95% CI: 0.91-1.46).

Conclusion:

Among older adults with mobility impairment, mobility device use was generally low. Device use was associated with worsening frailty in those who pre-frail but was not associated with frailty progression in those with mild or worse frailty.

Poster #6

A CASE REPORT OF BOWEN'S DISEASE OF THE NIPPLE MASQUERADING AS PAGET'S DISEASE

Shirley Cheng, BS¹, Jared Su, MD², Jessica Kieu, MD²,
Amelia Wong, DO², and Ashley Marumoto, MD³

¹University of Hawai'i, John A. Burns School of Medicine, Honolulu, HI

²University of Hawai'i, Department of Surgery, Honolulu, HI

³The Queen's Medical Center, Dept of Surgery, Honolulu, HI

Background:

Bowen's disease is a precancerous intradermal lesion that commonly arises in sun-exposed areas. Risk factors include irradiation, inflammation, carcinogen exposure, and human papilloma virus exposure. Its presentation on the nipple-areolar complex is rare with only 11 cases reported in literature. Distinguishing similarly presenting intraepithelial lesions such as Bowen's disease and Paget's disease is important as they have differing management approaches.

Case Presentation:

We report a case of a post-menopausal woman with a history of radiation treated bilateral breast cancer diagnosed with Bowen's disease of the nipple. She initially presented with new onset bloody nipple discharge with a prior screening mammogram (BI-RADS 2 benign) demonstrating a nipple lesion. Work up included a bilateral diagnostic mammogram and ultrasound which were negative for any suspicious findings. A punch biopsy of the lesion was performed. Histological analyses identified epithelioid cells in the intradermal space staining CK7 (+) and p40 (+)/p63 (+), classifying the lesion as Paget's disease. Ultimately the patient opted for bilateral simple mastectomy. Final surgical pathology revealed atypical keratinocytes that focally extend throughout the full epidermal thickness that stained CK7 (-), CK5/6 (+), p40 (+), HER2 (-) and GCDFP15 (-) consistent with the diagnosis of Bowen's disease.

Conclusion:

The patient had a history of breast cancer which was treated with partial mastectomy and radiation which is a known risk factor of Bowen's disease. Histopathology analysis and immunohistochemical staining such as high and low molecular weight keratin in addition to CK7 staining are imperative to distinguish the differences between Bowen's and Paget's disease. Excision and analysis of the lesion in its entirety compared to a punch biopsy should be pursued to make an accurate diagnosis and prevent overtreatment.

Poster #7

BREAST NODULAR FASCIITIS IN A POSTMENOPAUSAL WOMAN: A CASE REPORT AND REVIEW OF RECENT LITERATURE

Shirley Cheng, BS¹, Briana Lau-Amii, MD, FACS, FSSO²

¹University of Hawaii John A. Burns School of Medicine, Honolulu, HI

²Hawaii Permanente Medical Group, Honolulu, HI

Background:

Nodular fasciitis (NF) is a benign soft tissue lesion that can occur anywhere in the body. Its occurrence in the breast is a rare phenomenon, but is clinically important to distinguish from a malignant tumor as they both present as lesions of the breast.

Case presentation:

In this report, we discuss a case of NF of the breast in an elderly woman who presented with an asymmetry of the breast on an annual screening mammogram followed by diagnostic imaging and a core biopsy. Ultimately, excision of the lesion (1.2cm) was the definitive treatment for this patient and histological evaluation confirmed the diagnosis of nodular fasciitis. Additionally, we review the most recent literature on this topic discussing the significance to better understand the characteristics and best treatment course for breast NF.

Conclusion:

The clinical features of breast NF may present similarly to that of a malignant tumor. Accurate diagnosis with immunohistochemistry staining or USP6 FISH analysis is critical to prevent misdiagnosis and overtreatment. Clinician awareness, surgical treatment, and patient education is important for best management of breast NF.

Poster #8

A CASE OF THE “-ITIS”: MULTI-SYSTEM ORGAN DYSFUNCTION DUE TO NIVOLUMAB THERAPY

Ethan Charles Chun¹, MD; Philip Verhoef, MD, FACP²

¹Kaiser Permanente Hawaii Internal Medicine Residency Program, Honolulu, HI

²Hawaii Permanente Medical Group, Honolulu, HI

Introduction:

Over the last several decades, rapid advancement in oncologic and pharmaceutical research has yielded an ever-growing array of treatment options for patients with cancer. However, not only can these agents render patients susceptible to infection due to immunocompromise, they also carry the risk of serious systemic drug-related toxicities. Such adverse effects are well-documented among checkpoint inhibitors, and this case highlights a patient who developed multi-organ injury following just one treatment cycle of nivolumab.

Case:

A 58-year-old widowed Filipino woman with recently diagnosed, locally advanced renal cell carcinoma (RCC) initiated Cycle 1 of nivolumab + cabozantinib. Of note, she was found to have no distant metastases on pre-treatment workup, which was otherwise unremarkable (including renal, liver, and thyroid function, coagulation studies, CT chest, brain MRI, and TTE). Two weeks after initiation of therapy, she presented with 1 day of new altered mental status (poorly responsive per family) accompanied by a witnessed generalized seizure in the ED. She was found to have evidence of posterior reversible encephalopathy syndrome (PRES) on head CT, but in the absence of hypertension. She soon developed cardiogenic shock requiring inotropic support with milrinone (peak troponin I 5867 ng/L, new reduced ejection fraction from 65% to 25% with severe biventricular systolic dysfunction on TTE) as well as pneumonitis with hypoxic respiratory failure requiring intubation (new patchy bilateral ground glass opacities on chest CT). Early in the course of her ICU admission and workup, she was found to have new thyrotoxicosis (TSH 0.03 mcIU/mL, free T4 4.7 ng/dL), DIC (INR 3.8, PTT 41.8 sec, d-dimer >20 mcg/mL, fibrinogen 89 mg/dL) requiring supportive transfusions, hepatitis (ALT 737 U/L, AST 2716 U/L, ALP 141 U/L, total bilirubin 2.1 mg/dL), and severe acute kidney injury requiring high-dose diuretics to maintain fluid balance (creatinine 3.49 mg/dL, BUN 105 mg/dL, HCO₃ 17 mmol/L). No source of underlying infection was identified. Oncology was consulted, and determined that the patient's multisystem organ dysfunction – PRES, myocarditis, pneumonitis, hepatitis, thyrotoxicosis, coagulopathy, and possible nephritis - was the result of nivolumab-associated systemic toxicity. Per oncology recommendations, patient was started on high-dose IV steroids and a 5-day course of IVIG. However, she did not demonstrate significant clinical improvement and on hospital day 11, after discussion with her POA, the patient was transitioned to comfort measures only.

Discussion:

We describe a case of multisystem organ dysfunction in an otherwise healthy patient following treatment with nivolumab for RCC. It highlights the broad spectrum and degree of checkpoint inhibitor-related toxicities which may occur at any point during therapy and emphasizes for clinicians the importance of both keeping a low threshold for suspicion of such complications and reviewing with prospective patients the potential risks as well as benefits of these treatment options.

Poster #9

A RARE CASE, PRESENTATION, AND OUTCOME: MARCHIAFAVA-BIGNAMI DISEASE PRESENTING AS SEROTONIN SYNDROME WITH A POSITIVE OUTCOME

Nickolaus E Crump, MD¹; Abhinetri Pandula, MD²

¹Kaiser Permanente Internal Medicine Residency Program, Honolulu, HI

²Hawaii Permanente Medical Group, Department of Internal Medicine, Honolulu, HI

Introduction: Marchiafava-Bignami Disease (MBD) is a rare but severe demyelinating disorder of the corpus callosum with high rates of long-term disability and mortality. Symptoms vary from confusion to coma and prognosis is guarded. Etiology is uncertain but thought to be linked to a deficiency of several B vitamins, including thiamine. MBD can be easily confused with other more common diseases or syndromes. Prompt diagnosis and early treatment is imperative. The data on MBD is still extremely limited and the few cases that presented as serotonin syndrome had very poor outcomes. We present here the complicated course of a case of MBD with serotonin syndrome like symptoms.

Case: A 34-year-old man with a history of anxiety, ADHD, major depressive disorder, and severe alcohol use disorder presented to the emergency department with tremor and involuntary muscle spasm for three weeks duration. He reported drinking three 750mL bottles of whiskey the weekend prior to his presentation, with his last drink the night before admission. Physical examination showed an obese gentleman with diffuse tremors, clonus, hypertonicity in all extremities, diaphoresis, hypertension, bilateral horizontal nystagmus, and tachycardia. Initial labs were within normal limits excluding an elevated alkaline phosphatase. Drug screen was negative. Differential diagnosis included alcohol withdrawal, serotonin syndrome, or other toxic ingestion. Treatment with IV benzodiazepines showed no effect. The patient was transferred to the ICU and continued treatment for alcohol withdrawal and serotonin syndrome. The patient became delirious, agitated, and combative, resulting in sedation and intubation. After four days he remained comatose with severe tremors. EEG was consistent with encephalopathy likely secondary to sedatives. MRI showed findings in the splenium of the corpus callosum typical of MBD. The patient was continued on nutritional supplement with thiamine for seven days without improvement. Methylprednisolone was added and thiamine dose was increased. Over twenty-three days, he improved and began rehabilitation. His course was complicated by acute respiratory failure, aspiration pneumonia, pulmonary embolism, DVT, AKI, and bacteremia. The patient showed significant recovery and repeat MRI one month after admission showed no residual findings significant for MBD.

Discussion: Marchiafava-Bignami Disease usually manifests in adult males 40-60 years-old with alcohol use disorder and malnutrition and is characterized by demyelination and necrosis of the corpus callosum. Two sub-types have been identified, with Type A being more severe and involving impaired consciousness. Data is limited, with roughly 250 cases reported before 2004 and fewer than 200 additional reports listed since 2004. Suspected etiology is a combined toxic and malnutrition effect with thiamine deficiency a key factor. Aggressive nutritional replacement with thiamine is suggested. Steroid use has shown non-significant improvement in outcomes. Treatment has not been standardized, but this case suggests that high dose thiamine replacement with steroid administration can prove effective.

A CASE OF DISTANT PROSTATE CANCER PRESENTING AS A SOLITARY BREAST MASS

Nickolaus E Crump, MD¹; Abhinetri Pandula, MD²

¹Kaiser Permanente Internal Medicine Residency Program, Honolulu, HI

²Hawaii Permanente Medical Group, Department of Internal Medicine, Honolulu, HI

INTRODUCTION:

Breast masses are a rare occurrence in males, as is prostate cancer presenting as distant metastases without lower urinary tract symptoms. Although rare, prostate cancer can metastasize to the breast. Incorrect diagnosis can have dire consequences. Here we discuss a rare case of an 82-year-old male with prostate cancer presenting as a solitary breast mass in the absence of other symptoms, and subsequent positive outcome due to early initiation of treatment.

CASE:

An 82-year-old man with a history of hyperlipidemia and erectile dysfunction presented with a left breast mass. A full review of systems was otherwise negative, including lower urinary tract symptoms. His medications included simvastatin and aspirin. He took saw-palmetto and astaxanthin over the counter.

Physical exam revealed a 4x6cm, smooth, firm, mass of the inferior left breast that excluded the areola and was fixed to the chest wall. No associated erythema, skin puckering, or melanotic changes were appreciated. The remainder of his exam was benign. Initial suspicion was of a liposarcoma versus sarcoma of unknown primary source. Initial evaluation included mammogram and ultrasound, which revealed skin thickening and linear calcifications concerning for possible malignancy. CT chest with contrast showed invasion and destruction of the underlying ribs, without involvement of the parietal pleura. Biopsy of the mass was sent for molecular profiling and histologic stain. Histology showed carcinoma with glandular tissue, cuboidal to columnar cells, round nuclei, and prominent nucleoli. Molecular profiling was negative for breast markers and positive for NKX3.1 and P501s, confirming prostate tissue. Prostate specific antigen (PSA) was almost 20 times the upper limit of normal. CT of the abdomen and pelvis showed an enlarged prostate with right external iliac chain lymphadenopathy. Positron emission tomography (PET) showed multiple metastases in bilateral ribs, the right proximal humerus, the thoracic spine, lumbar spine, and bilateral pelvic bones. Prostate biopsy was deemed unnecessary given the distant metastases.

The patient was started on androgen deprivation therapy (ADT) with bicalutamide and leuprolide, followed by abiraterone and prednisone. He tolerated the regimen well with minimal adverse effects and saw significant reduction in the size of his breast mass.

No metastatic disease could be found on subsequent scans.

DISCUSSION:

Prostate cancer rarely presents with distant disease in an asymptomatic patient. When prostate cancer presents with distant disease, bone is the most common site followed by lymph node, liver, and thorax, with breast metastases being exceedingly rare. Metastases to the breast are known to present with pathologic features consistent with primary breast malignancy. Without molecular profiling, our patient could have been easily misdiagnosed and treatment could have been delayed. It is vital that male patients presenting with isolated breast mass be screened appropriately for prostate cancer as part of their work up.

**ATYPICAL MONONUCLEOSIS INFECTION PRESENTING
AS ACUTE CHOLESTATIC LIVER INJURY**

Yula Yzabelle Geniza, MD¹; Javier Barranco-Trabi, MD1; Pedro Manibusan, DO²

¹Department of Medicine Training Program, TAMC, Honolulu, HI

²Department of Medicine, TAMC, Honolulu, HI

Introduction: Infectious mononucleosis (IM), presents with a triad of tonsillar pharyngitis, fever, and lymphadenopathy. Most commonly caused by Epstein-Barr virus (EBV), is generally self-limited. Transmission is thought to spread mostly by contact with mucous membranes, such as kissing. Atypical presentation of IM is rare, a few literatures notably in pediatric¹ and elderly patients² and jaundice were published. We present a case of IM with an unusual presentation in a young adult female that presented as jaundice with hyperbilirubinemia with concomitant liver enzyme elevation consistent with a cholestatic pattern.

Case Presentation: A 26-year-old female presented to the emergency department three weeks after swimming in fresh water with jaundice, icterus and generalized body aches. Five days before presentation, she reported worsening symptoms to include fever, nausea, vomiting and drenching night sweats. Leptospirosis was suspected because of her exposure. She was started on empiric antibiotic treatment. She was afebrile, tachycardic with blood pressure within normal limits. On physical exam, patient had icterus, jaundice, no lymphadenopathy, benign abdominal exam and no hepatosplenomegaly. She had conjugated hyperbilirubinemia on with cholestatic liver enzyme elevation. The hepatitis panel, acetaminophen, and ammonia level were negative. She denies taking medications. The urine drug screen was positive for cannabinoid. A right upper quadrant ultrasound was negative for biliary duct dilation/obstruction. Computed tomography scan of the abdomen was notable for splenomegaly. Monospot and EBV serologies were positive. Gastroenterology's input was to defer Endoscopic Retrograde Cholangiopancreatography/Magnetic Resonance Cholangiopancreatography because there was no evidence of biliary obstruction the symptoms were consistent with IM from EBV. She improved with supportive care.

Discussion: Viral, alcoholic, medication, autoimmune causes of hepatitis can cause jaundice. Jaundice can be classified as conjugated or unconjugated hyperbilirubinemia. Conjugated hyperbilirubinemia with other liver derangements can be classified into a hepatocellular process and intra vs extra cellular cholestasis. Subsequently, a right upper quadrant ultrasound can detect a dilation of the intra and extra hepatic biliary tree. An appropriate next test would be an abdominal CT. In patients with intrahepatic cholestasis, the diagnosis is made with serological testing and percutaneous liver biopsy.³

Conclusion: Differential diagnosis of cholestatic liver injury is broad which requires detailed history. Our case aims to demonstrate the importance of cholestatic liver injury as a rare manifestation of EBV mononucleosis. We can include EBV and a monospot test on a work-up of cholestatic jaundice to save time and resources.

References:

¹ <https://pubmed.ncbi.nlm.nih.gov/29364802/>

² <https://pubmed.ncbi.nlm.nih.gov/27037083/>

³ Longo DL, Fauci AS, Kasper DL, Hauser SL, Jameson J, Loscalzo J. eds. Harrison's Principles of Internal Medicine, 18e. New York, NY: McGraw-Hill; 2012.

ECHOCARDIOGRAPHIC VALIDITY OF THE ELECTROCARDIOGRAPHIC DIAGNOSIS OF LEFT ATRIAL ENLARGEMENT IN THE ELDERLY ASIAN POPULATION

Maan Gozun, MD¹, Yoshito Nishimura, MD¹, Todd Nagamine, MD¹, Parthav Shah, MD¹, Koichi Keitoku, MD¹, Andrew Pham, MD¹, Gavin Ha, MD¹, Ricky Huang, MD¹, and Steven Azuma, MD, FACP²

¹University of Hawaii Internal Medicine Residency Program, Honolulu, HI

²University of Hawai'i, Department of Medicine, Honolulu, HI

Introduction: Left atrial enlargement (LAE) is recognized in its association with atrial fibrillation, stroke, myocardial infarction, heart failure with preserved ejection fraction, and major adverse cardiovascular outcomes [1,2,3]. Electrocardiogram (EKG) is a quick, inexpensive, readily available method to assess for LAE. We studied the diagnostic accuracy of EKG for left atrial abnormality (LAA) in a retrospective study of a single institution that primarily cares for an elderly Asian population.

LAA criteria used were 1) P terminal force >0.04 mm/s in V1, 2) P wave duration >120 ms, 3) widely notched P wave >40 ms, 4) left axis of the terminal P wave, 5) P wave amplitude in V1 >3 mm and 6) purely negative P wave in V1 >0.04 s [1,3,4,5].

Retrospective review included all patients who had EKG and transthoracic echocardiogram (TTE) between December 2020 through April 2022 in a private cardiology clinic in Honolulu, Hawaii. All EKG interpretations were made by an individual investigator and confirmed by a board-certified cardiologist. These criteria will be validated using left atrial volume derived using American Society of Echocardiography (ASE) guidelines. In this study, we aim to establish the impact of race and age on sensitivity and specificity of electrocardiographic diagnosis of LAA that can be useful to artificial intelligence in the future.

Discussion: Criteria for electrocardiographic diagnosis of LAA using echocardiographic criterion as gold standard have an overall sensitivity of 62%, a specificity of 46%, a positive predictive value of 22%, and a negative predictive value of 83% in this elderly Asian population studied. Among the individual criteria used, the p-wave duration of >120 ms has the highest sensitivity of 46%, and both widely notched P-wave and p terminal force of >0.04 mm/s have the highest specificity of 92%. Previous studies documented a sensitivity of 54-63% and a specificity of 57-78% of the electrographic diagnosis of LAA [6,7].

Atrial dilatation and muscle hypertrophy, elevated atrial pressure, impaired ventricular distensibility, and delayed intra-atrial conduction may play a role in causing P-wave conduction abnormalities [5], hence the term LAA is preferred. Limitations to this study include a single-centered study, limited to ages 65 years old and above, Asian ethnicity, and the use of echocardiography as a comparative radiographic modality for diagnosing LAE.

Conclusion:

EKG criteria for LAA are less sensitive and less specific in this study population. Combining the EKG criteria for LAA increases sensitivity significantly in the population studied but decreases specificity for the detection of LAA. Artificial intelligence using racial and age descriptors may improve sensitivity and specificity [8].

SMALL CELL LUNG CANCER PRESENTING WITH MECHANICAL FALL

Shuhei Hattori, MD¹, Christina Park, MD¹, and Kuo-Chiang Lian, MD, FACP²

¹University of Hawai'i Internal Medicine Residency Program, Honolulu, HI

² Queen's University Medical Group, Honolulu, HI

Introduction:

Syndrome of inappropriate antidiuretic hormone (SIADH) is a well-known paraneoplastic phenomenon associated with small cell lung cancer (SCLC). More than 90% of patients with SCLC are elderly current or past heavy smokers. Presenting manifestations may result from local tumor growth, intrathoracic spread, distant spread or paraneoplastic syndromes. This case features a classic example of SCLC associated with SIADH presenting with hyponatremia-related encephalopathy in a man with a heavy smoking history.

Case:

A 79-year-old man with tobacco abuse was brought in by ambulance after a fall. According to bystanders, the patient fell and hit his occiput, but there was no loss of consciousness or seizure-like activities. The patient did not recall the event and felt normal. Of note, the patient had been seen by his primary care physician two weeks prior for "slowed walking," after being lost to follow up for 8 years. At the time, the patient had difficulty elaborating his complaint, but otherwise had an unremarkable physical exam. Basic metabolic panel obtained concurrently was notable for sodium level of 122 mEq/L.

At the time of this presentation, vital signs were remarkable for blood pressure of 167/89 mmHg. Physical examination revealed a confused man only oriented to self and place with an occipital hematoma. He had a normal cardiopulmonary and neurological exam. Computed tomography head imaging was unremarkable. Laboratory tests were significant for sodium 114 mEq/L, serum osmolality 234 mOsm/kg, urine osm 431 mOsm/kg, urine sodium 78 mEq/L, and normal thyroid-stimulating hormone and cortisol levels, all indicative of SIADH.

Patient was treated with fluid restriction and 3% hypertonic saline, which gradually corrected his sodium to 135 mEq/L. The patient's mentation was improved by the time of planned discharge. However, his hospitalization was complicated by substernal chest tightness at rest. CT angiogram for was performed for work-up, which was negative for pulmonary embolism. However, it demonstrated a 4.9 cm right hilar mass suspicious for malignancy. The patient then underwent endobronchial ultrasound with biopsy of the mass, which confirmed a small cell carcinoma of the lung. After discharge, the patient was referred to oncology and he is currently receiving chemotherapy with etoposide and carboplatin.

Discussion:

Studies report that SIADH occurs in up to 26% of SCLC patients at presentation. Paraneoplastic syndromes can present at an early stage of the disease and may offer an opportunity for early diagnosis and intervention. Clinicians should have high suspicion for SCLC in patients with SIADH and heavy smoking history, as the presence of SIADH may be a clue to early diagnosis.

**A HEART STOPPING CASE; YOUNG WOMAN WITH CARDIAC TAMPONADE,
RIGHT ATRIAL MASS, AND MILIARY LUNG NODULES**

Helena Holmgren, MD¹, Sunghyun Lee, MD¹, Philip Verhoef, MD, FACP²

¹Kaiser Permanente Hawai'i Internal Medicine Residency Program, Honolulu, HI

²Hawaii Permanente Medical Group, Honolulu, HI

Introduction: We present the lessons learned from the diagnostic evaluation of a critically ill previously healthy woman with cardiac tamponade, right atrial mass, and miliary lung nodules.

Case Presentation: A 37-year-old previously healthy female presented to the ED after a syncopal event. She reported three weeks of progressive cough, dyspnea, and exercise intolerance. She also endorsed night sweats and 10 lb weight loss. Vital signs showed oxygen saturation of 90% on room air, respiratory rate of 112, blood pressure of 106/77, and temperature of 99.0 F. Bedside echocardiogram demonstrated pericardial effusion with tamponade. Pericardiocentesis drained 650 cc bloody fluid with hemodynamic improvement. She had hypoxemic respiratory failure requiring high flow nasal cannula.

Laboratory evaluation was notable for WBC 19.8 (neutrophil predominant), mild AST/ALT elevation. Chest x-ray and CT of the chest demonstrated innumerable tiny bilateral nodules in a miliary pattern. CT of the abdomen and pelvis demonstrated bilateral ovarian masses with mild ascites. Bronchoscopy with bronchoalveolar lavage was unrevealing. All infectious tests including cell free DNA were negative. Autoimmune testing was negative. Subsequent CT guided biopsy of the lung did not show any evidence of infection or malignancy. Transthoracic echocardiogram showed a 3.5 x 3 cm right atrial mass.

To obtain a definitive diagnosis, she underwent a right upper and middle lobe wedge resection with Cardiothoracic surgery. Pathology demonstrated high grade vascular neoplasm consistent with angiosarcoma. During her hospital course, CT with angiography of the chest demonstrated bilateral subsegmental pulmonary emboli. MRI of the brain showed several small cerebral metastases with vasogenic edema. MRI of the thoracic spine demonstrated sub-centimeter T2 and T6 thoracic spine lesions suspicious for metastasis.

She subsequently initiated chemotherapy with gemcitabine and docetaxel followed by doxorubicin without any evidence of disease response. She received gamma knife radiation to brain metastasis. Unfortunately, she had hemorrhagic conversion of the brain metastasis and passed away five months after initial presentation.

Discussion: Angiosarcoma is a rapidly growing malignancy arising from blood or lymphatic vessels. Although rare, angiosarcomas are the most common primary cardiac tumor and often occur in the setting of prior radiation exposure. As seen in this patient's case, the tumor is usually located in the right atrium. Due to the nature of the disease including hematogenous metastatic spread, angiosarcomas can cause a miliary pattern of lung nodules in addition to other patterns. Unfortunately, cardiac angiosarcomas have a high prevalence of distant metastasis at the time of diagnosis and carry a poor prognosis.

This case demonstrates the extensive evaluation required to diagnosis cardiac angiosarcoma. We learned the importance of simultaneously stabilizing her critical condition while pursuing diagnostic workup.

**A COMPLICATED DIAGNOSIS OF NEUROSARCOIDOSIS
PRESENTING AS A SUBDURAL HEMATOMA**

Gabrielle Houser, DO¹; Javier Barranco-Trabbi, MD¹;
William Wadzinski, MD, FACP²; Matthew Blattner, MD²

¹Department of Medicine Training Program, TAMC, Honolulu, HI

²Department of Medicine, TAMC, Honolulu, HI

Introduction:

Neurosarcoidosis occurs in less than 10% of patients with the already rare disease of sarcoidosis. Neurologic symptoms are the presenting feature in less than half of those cases. Diagnosis of sarcoidosis often depends on radiologic findings consistent with granulomatous disease generally in multiple organs, histopathologic findings of noncaseating granulomas, and exclusion of other processes. This vague and indefinite set of diagnostic criteria makes sarcoidosis difficult to confirm. Diagnosis becomes even more complicated when a patient presentation lends itself to an even wider differential. Our patient case exemplifies an unusual initial presentation of sarcoidosis as a subdural hematoma, histopathologic findings blurring the lines between caseating and noncaseating granulomas, and a personal patient history of broad exposures to similarly presenting diseases.

Case:

A 40-year-old Active Duty Military male presented to the Emergency Department with four days of intermittent word-finding difficulty and headache and 4 months of intermittent right-hand tingling. He had a remote history of head trauma many months prior. CT head and angiogram indicated a subacute subdural hematoma with midline shift. Patient was admitted to the ICU for close monitoring; anti-seizure prophylaxis was initiated with Keppra. Further imaging, MRI-brain, reported the same subdural hematoma, but expanded the differential to include meningioma or hypertrophic pachymeningitis. Given the radiographic evidence, Tumor Board discussions resulted in a recommendation for craniotomy with biopsy for suspected meningioma. The mass was an avascular lesion densely adherent to the brain surface. Pathology specimens were first reported as fibrotic tissue with granulomas. Rheumatology, Infectious Disease, and Neurology were quickly consulted to sort through a variety of autoimmune, atypical infectious, and neoplastic causes of granulomas. The patient's history of travel with the military including to 3 continents with cave exploring in Guam and sheep/cattle ranching in California, put him at risk of an unrivaled number of atypical infections, including nearly all "endemic mycoses". Testing for this wide differential slowly resulted as negative. Concurrently, necrotizing granulomas originally thought to be caseating, were determined to be noncaseating on second opinion, altering the differential. Finally, multiorgan manifestation with mild bilateral hilar/mediastinal lymphadenopathy and hypodensities of the liver and spleen on CT C/A/P provided more evidence of sarcoidosis. As an outpatient, EBUS was later completed indicating similar noncaseating granulomas, and symptoms have improved with steroid treatment.

Discussion:

This patient's initial presentation of an apparent subdural hematoma on imaging with focal neurological deficits prolonged the already extensive workup before diagnosing neurosarcoidosis. His diagnosis was further complicated by granulomatous necrosis that highlighted the importance of distinguishing caseating versus noncaseating granuloma. Overall, this is a unique case of what appeared to be a straightforward diagnosis at onset that later resulted in an exhaustive diagnostic panel ending in a rare diagnosis of neurosarcoidosis.

Poster #16

PROLONGED COVID-19 INFECTION: EXPANDING GUIDELINES FOR THE IMMUNOCOMPROMISED

Courtney Kolberg, MD¹, Kirstin Hancock, DO¹, Matthew Perkins, MD²,
Nathaniel Copeland, MD², Ryan Jones, MD³, and George Giacoppe, MD⁴

¹Department of Medicine Training Program, TAMC, Honolulu, HI

²Infectious Disease Service, Department of Medicine, TAMC, Honolulu, HI

³Hematology and Oncology Service, Department of Medicine, TAMC, Honolulu, HI

⁴Pulmonology and Critical Care Service, Department of Medicine, TAMC, Honolulu, HI

Introduction: Current COVID-19 guidelines are meant to screen for, diagnose, and treat COVID-19 in immunocompetent persons. Current guidelines make assumptions about active viral replication duration in immunocompromised patients, potentially leading to undertreatment.

Case Presentation: A 51-year-old male with Crohn's colitis and Hodgkin's lymphoma, treated with splenectomy, bendamustine, vedolizumab, and rituximab, clinically in remission developed fever and cough three weeks after a positive home COVID-19 test. He received maintenance rituximab one week later, after which symptoms worsened. Following an empiric levofloxacin course, chest CT demonstrated bilateral lower lobe predominant ground-glass infiltrates thought secondary to rituximab-induced lung injury. Bronchoscopy was negative for *Pneumocystis jirovecii*, bacterial, fungal, or AFB infection. SARS-CoV-2 PCR was negative at that time. He received Bactrim for *Pneumocystis pneumonia* and steroids for presumed drug-induced lung disease. Symptoms initially improved but returned following steroid taper completion. Symptoms returned one month later, which were empirically treated with levofloxacin and prednisone. CT pulmonary angiogram demonstrated pulmonary emboli and received enoxaparin. SARS-CoV-2 PCR was positive 11 weeks after initial positive testing. He was admitted, received five days of remdesivir and dexamethasone, and was discharged on apixaban. Five days later, he was re-admitted with fever. He received three weeks of steroids due to concern for ongoing drug-induced lung injury and intermittent empiric antibiotics with periodic clinical worsening. Repeat bronchoscopies failed to show new infectious agents but SARS-CoV-2 PCR testing remained positive. He then received 10 days of remdesivir with minimal improvement.

Discussion among pulmonary, oncology, and infectious disease led to the consensus that the most plausible cause of his illness was inability to clear COVID-19 infection. Review of PCR results indicated correlation of cycle threshold (Ct) values (a semi-quantitative measure of viral load) with clinical status. He received intravenous immunoglobulin (IVIG). Viral culture was sent and returned positive. He received 14 days of remdesivir with treatment duration determined by requiring two negative SARS-CoV-2 PCR tests five days apart (negative test defined by Ct >35). Following treatment, the patient's oxygen requirements were eliminated at rest and he was discharged home.

Conclusion: Current COVID-19 guidelines may make overly optimistic predictions about immunocompromised patients' ability to clear COVID-19 and may prompt unnecessary pursuits of alternative diagnoses. Incorporating cycle times to quantify viral load may help better determine appropriate treatment duration for immunocompromised patients. IVIG may also be important for viral clearance in patients with impaired humoral immunity.

Poster #17

NEW-ONSET COMPLETE HEART BLOCK FOLLOWING RECENT COVID-19 INFECTION

Landon Kozai, MD¹, Kevin Benavente, DO¹, Christina Park, MD¹, and Kuo-Chiang Lian, MD, FACP²

¹University of Hawai'i Internal Medicine Residency Program, Honolulu, HI

²The Queen's University Medical Group, Honolulu, HI

Atrioventricular (AV) block is caused by a delay in electrical cardiac conduction between the atria and ventricles. Complete heart block (CHB) is a severe manifestation of this wherein communication between the atrial and ventricles is completely severed. Infection is recognized as an important cause of AV block, often resulting from myocarditis. COVID-19 often causes myocardial injury and may manifest as heart failure, acute coronary syndrome, myocarditis, and conduction abnormalities, among others. AV block is a suspected consequence of COVID-19 and may present in patients without active myocarditis.

A 68-year-old man with a past history of hypercholesterolemia presented to the emergency department with one month of dyspnea on exertion. His recent history was notable for acute COVID-19 infection one month prior to the current presentation, and at the time he was symptomatic with only cough and rhinorrhea. These symptoms improved with supportive care and he completed a ten-day quarantine. However, he subsequently complained of gradually worsening dyspnea on exertion. He had no history of cardiovascular disease. The physical exam was notable for junctional escape rate in the 40s with preserved hemodynamics; he had an otherwise normal cardiac and pulmonary examination. Laboratory results showed normal serum electrolytes, thyroid function tests, and cardiac-specific troponin levels. In addition, an echocardiogram showed a normal left ventricular ejection fraction of 55% and no wall motion abnormalities or valvular abnormalities. A 12-lead ECG demonstrated A-V dissociation consistent with CHB. He underwent dual-chamber pacemaker placement and noted immediate improvement in his symptoms post-procedurally. At two-week outpatient follow-up, the patient remained symptom-free.

We present a patient with CHB manifesting as dyspnea on exertion occurring in the setting of recent COVID-19 infection. The etiology of the CHB remains unclear, although we speculate that it may be due to COVID-19 due to its temporal association. Cardiac ischemia and active myocarditis are less likely, owing to normal cardiac troponins, unremarkable echocardiogram, absence of chest pain or ST-T changes on EKG, but idiopathic age-related degeneration of the conduction system is possible. Although active myocarditis is typically associated with AV block in COVID-19, the long duration of symptoms prior to presentation may have allowed for resolution of active inflammation. AV block is a known dysrhythmia that can occur during acute COVID-19 infection, and although the exact etiology is unclear, the mechanism is thought to be related to myocardial inflammation or in some cases, acquired autonomic dysfunction. However, the occurrence of cardiac dysrhythmias after the resolution of acute COVID-19 is less frequently reported. This case demonstrates a possible post-COVID-19 sequelae of complete heart block in the absence of active myocarditis. Patients with new onset cardiac dysrhythmias should therefore be evaluated for recent history of COVID-19 infection if the cause remains unclear.

Poster #18

A CASE OF CLINICALLY ISOLATED SYNDROME MANIFESTING AS OPTIC NEURITIS

Landon Kozai, MD¹, Kevin Benavente, DO¹, Christina Park, MD¹,

Tory Czech, MD¹, and Kuo-Chiang Lian, MD, FACP²

¹University of Hawai'i Internal Medicine Residency Program, Honolulu, HI

²The Queen's University Medical Group, Honolulu, HI

Optic neuritis (ON) is defined as inflammation of the optic nerve. It is associated with multiple sclerosis (MS) when presenting as a precursor entity known as clinically isolated syndrome (CIS) but may also present atypically with other inflammatory disorders or in isolation. In some cases, the underlying diagnosis remains unknown, however the current literature provides some guidance into which patients are more likely to progress to MS.

A 43-year-old woman with a history of depression and anxiety presented with worsening visual acuity in her left eye over one month. She described the appearance of black and white spots, with subsequent color desaturation and loss of peripheral field vision. She also reported a left-sided temporal headache with associated photophobia, fatigue, and occasional slurring of speech. Physical exam demonstrated a left afferent pupillary defect. She reported only being able to see movement and black and white shadows in the left eye. MRI of the brain and orbits revealed abnormal T2 hyperintense signal and contrast enhancement of the left optic nerve involving the distal cisternal, intracanalicular and posterior intraorbital segments, consistent with left optic neuritis. MRI of the cervical and thoracic spine did not show any evidence of demyelination. Given a high index of suspicion for clinically isolated syndrome, the patient was treated with five days of IV methylprednisolone. She was discharged to outpatient Neuroimmunology follow up on an oral steroid taper.

At two-month follow up, the patient complained of persistent left-sided headache and loss of visual acuity despite completing a course of steroids. Repeat examination demonstrated optic disc pallor and persistent deficit in visual acuity with left afferent pupillary defect. CSF studies revealed the presence of a single unique oligoclonal band. It was decided to monitor her off disease-modifying therapy due to a relatively lower risk of transition to clinically definite MS in the absence of multiple unique oligoclonal bands.

Optic neuritis is a common presentation of CIS. However, a portion of those with CIS have a monophasic illness and do not progress to clinically definite MS. Patients with CIS who have demyelinating lesions on baseline MRI are at greater risk of progressing to MS over time. A higher number of oligoclonal bands signifies a higher risk of developing clinically definite MS.

In general, one unique oligoclonal band is favored to be relatively non-specific, whereas more oligoclonal bands have high diagnostic accuracy, typically five, but sometimes two oligoclonal bands are considered as "positive." MS disease modifying therapy has been shown to reduce risk of progression from high-risk CIS to MS. Therefore, patients with CIS must be closely monitored for clinical and radiographic progression to MS and initiated on disease modifying therapy promptly if any new symptoms consistent with MS develops.

**CHATTERJEE PHENOMENON: A DEMONSTRATION OF
CARDIAC MEMORY IN PACED RHYTHMS**

Jason Kuniyoshi, MD¹, Maggie Kwock, MD¹, Krixie Silangcruz, MD¹,
Clarke Morihara MS⁴², and Dipanjan Banerjee, MD³

¹University of Hawai'i Internal Medicine Residency Program, Honolulu, HI

²University of Hawaii John A. Burns School of Medicine, Honolulu, HI

³The Queen's Medical Center, Honolulu, HI

While T wave inversions (TWI) in electrocardiograms (EKG) are commonly associated with certain cardiac pathologies, it is rarely associated with cardiac memory. This rare cause of TWI is usually the result of either a ventricular paced rhythm or in patients with a known history of tachycardic rhythms. This abnormal conduction induces alterations in both early and late myocardial activation potentials leading to cardiac remodeling and heterogenous depolarization and has been coined the Chatterjee phenomenon.

Case:

A 76-year-old male with a past medical history significant for heart failure with preserved ejection fraction (HFpEF), asthma, sick sinus syndrome with a DDD pacemaker and newly diagnosed COVID-19 infection with recent COVID-19 vaccination, presents with chest tightness and new onset TWI in his precordial leads. Seven days prior to admission, the patient received his second Moderna COVID-19 vaccination and noted chest tightness, but remained afebrile, without loss in taste or smell. On admission, the patient tested positive for COVID-19 infection, but remained relatively asymptomatic and required supplemental oxygen that was eventually weaned off after the patient was restarted on his home prednisone. His troponin remained stable at 0.05 ng/mL and his EKG was noted to have TWI throughout his precordial leads. Compared to an EKG taken prior to hospitalization, it showed normal sinus rhythm without a paced rhythm nor ST wave abnormalities. Interrogation of his pacemaker revealed an AV paced rhythm.

Decision-making:

Our patient was monitored after one day of observation for his COVID-19 infection. Given his chest tightness without dynamic changes in his troponin nor EKG, the patient's symptoms were deemed to not be cardiac in nature. He was discharged for home isolation for his COVID-19 infection.

Conclusion:

Herein, we present a patient in whom, his AV paced rhythm and EKG was significant for narrow QRS complexes with TWI localized to his precordial leads without evidence of active cardiac ischemia, suggestive of Chatterjee phenomenon.

Poster #20

HEMOPTYSIS OR NOT?: ACUTE HYPOXEMIC RESPIRATORY FAILURE SECONDARY TO ASPIRATION FROM CANNABINOID HYPEREMESIS SYNDROME

Jerrick J. Laimana, MD¹; John A. Kileci, MD^{1,2}.

¹Kaiser Permanente Hawaii Internal Medicine Residency Program, Honolulu, HI

²Section of Pulmonary and Sleep Medicine, Hawaii Permanente Medical Group, Honolulu, HI

Introduction:

As usage rates of cannabis increase amongst all age groups, so too has Cannabinoid Hyperemesis Syndrome (CHS), a relatively new syndrome associated with intractable vomiting and chronic cannabis use. We present a case of acute hypoxemic respiratory failure secondary to aspiration from CHS.

Case Description:

A 28-year-old man with Type 1 DM presented to the emergency department (ED) with nausea, vomiting with bloody contents, and hypoxemia. Patient had been previously hospitalized 2 months earlier with similar complaints and with rapid resolution of symptoms. EGD at that time was negative for any high-risk stigmata for bleeding but was positive for H pylori, for which he was discharged with triple therapy. Two months after hospitalization patient presented again to the ED for nausea, vomiting with bloody contents and hypoxemia (82% saturation) with exam significant for acute distress, tachycardia, and bilateral and diffuse rhonchi. Labs were significant for elevated WBC of 16500/mcL and a stable hemoglobin of 11.6 gm/dL. CT chest was positive for diffuse bilateral ground glass opacities, concerning for hemoptysis from diffuse alveolar hemorrhage (DAH). Patient was subsequently transferred to the ICU for non-invasive positive-pressure ventilation, started on high-dose steroids for DAH and started on broad-spectrum antibiotics. Patient improved rapidly despite only receiving one dose of methylprednisolone 125mg IV, and by the next day he was clinically stable with 100% saturation on 1LPM O₂ by nasal cannula with resolution of symptoms. Upon further inquiry, patient detailed long-term significant daily marijuana use (average of 5 joints per day) with 10-15 prior episodes of intractable vomiting in the past year with similar bloody contents. Given this history, and his rapid resolution of symptoms, we suspected his presentation was more consistent with hyperemesis and aspiration with blood-tinged sputum. Patient was weaned to room air the following day and discharged. He was ordered to abstain from marijuana and complete a rheumatologic work-up. On outpatient follow-up, he reported that he did trial the use of marijuana two times, which caused nausea to reoccur. Otherwise, patient remained asymptomatic, and rheumatologic work-up was negative. Repeat chest CT 1 month after hospitalization showed resolution of ground glass opacities.

Discussion:

From 2002 to 2019 prevalence of marijuana use increased from 11.0% to 17.5% among people aged 12 or older. As the prevalence of marijuana use continues to rise so too can we expect the frequency of CHS to rise. CHS can be a challenging diagnosis to make and is reliant on taking an appropriate history detailing use of cannabis. Thus, CHS should be considered in all patients presenting with episodes of intractable vomiting and concurrent marijuana usage.

**USE OF AN OVER-THE-SCOPE CLIP IN MANAGING
ADULT ANASTOMOTIC ULCER BLEEDING**

Anson Y. Lee, BS, BA¹, and Scott K. Kuwada, MD, AGAF, FACP²

¹University of Hawaii John A. Burns School of Medicine, Honolulu, HI

²Queen's University Medical Group Center, Honolulu, HI

Introduction:

Anastomotic ulcers (AU) following surgical procedures such as ileocolonic resection in patients without Crohn Disease are a rare occurrence. The overall incidence of AUs among both adult and pediatric patients is estimated to be between 0.3%-8%. Primary symptoms include abdominal pain, iron deficiency anemia, and evidence of gross or occult gastrointestinal (GI) bleeding. However, effective treatment options are lacking, and physicians often resort to resecting the affected AU with re-anastomosis of the ileocolonic region. To date, no study has reported the use of an over-the-scope clip (OTSC) in the successful closure of an AU in an adult patient to treat recurrent bleeding.

Case Report:

The patient is a 67-year-old woman with a past medical history of pulmonary fibrosis, rheumatic heart disease, status post mitral commissurotomy and mechanical mitral valve replacement; with warfarin, atrial fibrillation, benign colon mass, status post colostomy, and history of two recurrent episodes of ileocolonic anastomosis bleeding. She presented to the emergency department with progressively bloody small volume “plum-colored” stools over three days but continued to take warfarin. Laboratory studies conducted on her day of presentation identified glucose: 122 mg/dL, RBC: 3.21 million/L, Hgb: 9.1 g/dL, Hct: 28.2%, PT: 29.2 seconds, PTT: 37.4 seconds, and INR: 2.9. Same day computed tomography angiogram for acute gastrointestinal bleeding revealed a lack of active gastrointestinal tract bleeding. She had no antibiotic exposures or changes in diet and was admitted for an in-patient stay.

On day two, a colonoscopy identified a normal terminal ileum, blood in the examined colon, as well as an actively bleeding seven-millimeter-wide AU at the patient’s functional end-to-side ileocolonic anastomosis. Hemoclips were placed for hemostasis, but a repeat colonoscopy was conducted eight days later due to recurrent hematochezia and acute posthemorrhagic anemia. A single 14-millimeter OTSC was then positioned across the entirety of the ulcer and successful hemostasis achieved. Since OTSC placement, the patient has not had recurrent lower GI bleeding or worsening anemia for 6 months, while continued on chronic warfarin.

Discussion:

AUs are often difficult to manage and in this case, the patient presented with overt GI bleeding and anemia. OTSCs are increasingly being employed as a non-surgical modality for treating adult GI hemorrhages, ulcer bleeding, perforations, fistulas, and anastomotic leaks. While not created intentionally for the closure of AUs, it proved to be beneficial in the current patient. The novel use of such a device for AUs emphasizes the importance of experiences described in case reports and opens up the possibilities of its use in future practice.

FALSE POSITIVE? TWO CASES OF PERSISTENTLY ELEVATED TROPONIN I WITHOUT CLINICAL EVIDENCE OF CARDIAC INVOLVEMENT

Brett W. Mathews, MD¹, Kiana Kaya¹; and Stacey A. Honda, MD²

¹Kaiser Permanente Hawaii Internal Medicine Residency, Honolulu, HI

²Hawaii Permanente Medical Group, Honolulu, HI

Introduction: With the widespread adoption of high sensitivity troponin assays, clinicians must recognize elevations can be caused by several cardiac and noncardiac conditions. Growing evidence in adult populations demonstrates “true” false positives, while rare, have been caused by heterophile antibodies, hemolysis, and fibrin interference. We add to this body of literature with two cases in adolescents of persistently elevated high sensitivity troponin I without cardiac involvement.

Case 1: A 16-year-old male with situs inversus total is presented with non-exertional, right-sided chest tightness beginning while he was sitting in class. He denied radiation, palpitations, shortness of breath, nausea, diaphoresis, constitutional symptoms, or preceding upper respiratory infection. He had no prior episodes of chest pain, had otherwise been healthy, and had not received COVID-19 vaccination. Labs were significant for high sensitivity troponin I 1811, ESR 19, CRP 0.2, SARS-COV-2 PCR negative, SARS-COV2-Ab positive, and Heterophile antibody negative. ECG demonstrated clear j-point ST elevations consistent with early repolarization. Telemetry did not demonstrate arrhythmia. Echocardiogram was normal (apart from dextrocardia), and cardiac MRI did not demonstrate myocardial enhancement, pericardial effusion, or pericardial thickening. 1 month after his initial presentation, high sensitivity troponin I remained elevated at 1750. Cardiac troponin T sent to an outside lab returned negative.

Case 2: A 16-year-old male presented with sternal chest pain that woke him from sleep. He denied radiation, diaphoresis, nausea, SOB, palpitations, constitutional symptoms, or preceding upper respiratory infection. He reported several episodes of similar chest pain occurring monthly for the past few years aggravated by pressing on his sternum. He had received a COVID vaccine 1 month prior. Labs were significant for high sensitivity troponin I 548, ESR 13, CRP 0.2, CK-MB 1.8, SARS-COV-2 PCR negative, and Heterophile antibody negative. ECG demonstrated early repolarization in the inferior and lateral leads. Echocardiography was normal, and cardiac MRI did not demonstrate myocardial enhancement, pericardial effusion, or pericardial thickening. 3 months following his initial presentation, he returned to the ER with similar chest pain. Troponin remained elevated at 345. ESR, CRP, CK-MB were normal. ECG was unchanged from prior. Cardiac troponin T sent to an outside lab returned negative.

Discussion: While myocarditis had been considered (particularly in the setting of prior SARS-COV-2 infection and vaccination for each patient respectively), absence of inflammatory markers or focal enhancement on cardiac MRI strongly argued against this diagnosis. Further, the presence of persistently positive cardiac troponin I in the setting of negative cardiac troponin T and CK-MB was highly suggestive of a false positive result. Notably, heterophile antibodies were not present in either patient. These cases highlight the importance of recognizing false positive results to avoid risk associated with unnecessary invasive diagnostic testing.

Poster #23

AN UNUSUAL CAUSE OF RECURRENT IDIOPATHIC SMALL BOWEL OBSTRUCTION

Michelle Pang, MS¹, JABSOM; Scott Kuwada, MD, AGAF, FACP^{2,3}

¹University of Hawaii, John A Burns School of Medicine, Honolulu, HI

²University of Hawai'i, Department of Medicine, Honolulu, HI

³Queen's University Medical Group, Honolulu, HI

A 66-year old caucasian woman was referred for partial small bowel obstruction (SBO). The patient had been experiencing diffuse crampy abdominal pain, diarrhea and hives over the past several weeks for which an allergist and dermatologist had prescribed prednisone 10mg/d, cetirizine 10mg/d, and ranitidine 150mg/d. She then developed severe diffuse abdominal cramps with nausea and vomiting and went to the Emergency Department. CT abdomen showed partial SBO with a small bowel transition point. The SBO resolved within days with conservative management. An EGD and colonoscopy with biopsies were performed and were unremarkable but a pillcam study showed non-raised pigmented spots in the distal small bowel. Urine 5-HIAA and blood tryptase levels were normal but a urine histamine level was 9-times the upper limit of normal.

Over the next two years, she was hospitalized for two more episodes of SBO. With each episode of SBO, her CT scans showed transition points at different locations in her small bowel, making adhesions unlikely causes of SBO. She had no history of prior abdominal surgeries or pelvic inflammatory disease. Allergy testing and avoidance were unable to prevent hives or episodes of abdominal pain.

She was referred to an expert at a major medical institution for evaluation for suspected mast cell disease. Mutation testing for KIT D816V from a bone marrow biopsy was negative for mutation and systemic mastocytosis but she was felt to have Mast Cell Activation Syndrome (MCAS). She was advised to go on a starch- and sulfate- free diet.

The diet did not help so the patient was started on cromolyn 200mg po QID. Over the subsequent 5 years, her abdominal pains diminished and she only had symptoms of SBO once and no hospitalization was required. Unfortunately, her hives were not completely alleviated and trials of prednisone and cyclosporine were ineffective.

The patient was diagnosed with Idiopathic MCAS, a condition in which the patient experiences repeated episodes of the symptoms of anaphylaxis – allergic symptoms such as hives, swelling, low blood pressure, difficulty breathing and severe diarrhea. High levels of mast cell mediators are released during those episodes. Histopathological diagnosis from non-bone marrow tissues of MCAS can be tricky since mast cells can rapidly degranulate.

There are previous reports of SBO due to MCAS, which are felt to be due to tissue edema, but this is the first case in which recurrent SBO was successfully alleviated with cromolyn. Further studies are required to study the long-term efficacy of cromolyn and avapritinib in patients with severe problems due to MCAS.

Poster #24

A RARE PRESENTATION OF NEW ONSET OCCIPITAL SEIZURES IN DIABETIC KETOACIDOSIS

Carly Pappo, MD¹, Kelsey Kwong, MD¹, and Young Rho, MD²

¹University of Hawai'i Internal Medicine Residency Program, Honolulu, HI

²The Queen's Medical Center, Honolulu, HI

Case:

A 73-year-old male with a past medical history of type 2 diabetes and HSV Zoster infection was admitted for persistent dizziness for two weeks, which he describes as “everything around me is moving.” His wife also noticed poor appetite, fatigue, and increased irritability. On neurological examination, the patient was alert and oriented, with left hemianopsia, decreased sensation over his left V1-V3 region, left-sided neglect, left arm pronator drift, and left hemibody weakness (4+/5). Speech was fluent, no facial droop was present, and there were no abnormalities with reflexes, coordination, or gait. Examiner then witnessed a 1-minute episode of left arm jerking; the patient was conscious throughout with no gaze preference. Labs revealed diabetic ketoacidosis (DKA) with an initial glucose of 487, serum osmolality of 304, pH 7.32, bicarbonate of 26, anion gap of 29, B-hydroxybutyrate of 3.51, and 1+ ketones/4+ glucose in the urine. CT head was negative for hemorrhage or ischemia, and MRI brain was only notable for right P2 stenosis. Continuous EEG monitoring revealed focal motor seizures of right occipital onset with spread. The patient was treated with hydration and insulin, but he continued to seize after the glucose normalized, requiring treatment with Keppra and subsequently Phosphenytoin. The patient was discharged with Keppra and a basal/bolus insulin regimen. At the time of discharge, all neurologic deficits had resolved except for the left hemianopsia.

Discussion:

In rare cases such as this, hyperglycemia can present with neurologic findings that mimic a stroke. In our patient whose multiple deficits could not be localized to a specific region, hyperglycemia-induced seizures likely led to global cerebral dysfunction. The transient nature of his deficits may suggest a Todd's phenomenon.

The mechanism of hyperglycemia-induced seizures is incompletely understood. Previously, the mechanism was thought to be via the hyperosmolality of DKA causing brain cells to accumulate intracellular osmolytes. More recent theories suggest that fluctuations in cerebral blood flow causing a hypoperfusion and reperfusion injury with vasogenic edema, in combination with an inflammatory reaction disrupting the blood brain barrier, is the underlying mechanism. Some studies have also suggested that preexisting lesions (such as an area of prior ischemia or encephalomalacia) may predispose patients with hyperglycemia to focal seizures.

Conclusion:

This case illustrates the importance of recognizing uncommon neurologic presentations and complications of DKA. Treatment focuses on glucose lowering, though anti-epileptic medications may be required.

**A CASE OF BILIARY OBSTRUCTION CAUSED BY
ASCARIS LUMBRICOIDES INFECTION**

Christina Park, MD¹, Jonathan Estaris, MD¹, Landon Kozai, MD¹, and Kuo-Chiang Lian, MD, FACP²

¹University of Hawai'i Internal Medicine Residency Program, Honolulu, HI

²The Queen's Medical Center, Honolulu, HI

Ascaris lumbricoides is the largest intestinal nematode that parasitizes the human intestine. While most patients are asymptomatic, aggregation of *Ascaris* in the intestine or invasion of the biliary ducts may lead to complications such as intestinal obstruction, cholecystitis, pancreatitis, and cholangitis. However due to its rare presentation in the developed world, it remains a less frequently recognized cause of obstructive cholangitis. Here we present a case of biliary ascariasis in a patient presenting from micronesia with chronic abdominal pain and constipation.

A 77-year-old Chuukese male with a past history of medically treated trichuriasis, pancreatic adenoma treated with distal pancreatectomy, and cholecystectomy presented with diffuse abdominal pain, most prominent on the right upper quadrant, associated with chronic constipation. Physical examination revealed a soft abdomen with well-healed surgical scar and normoactive bowel sounds, but right upper quadrant tenderness without guarding or rebound. Initial laboratory studies were remarkable for leukocytosis of 18,000/uL with eosinophilia of 29.4%, direct hyperbilirubinemia of 0.7 mg/dl, and elevated alkaline phosphatase of 209 IU/L.

The CT abdomen revealed biliary distention with a left hepatic hypodense lesion consistent with small abscess. MRCP confirmed a linear filling defect extending throughout the extrahepatic into the right intrahepatic bile duct with liver abscess. The patient underwent ERCP, which identified six roundworms in the duodenum and bile duct that were manually removed with forceps. A common bile duct stent was also placed. On the following day, the patient also coughed up one intact roundworm. The histopathology of the worm revealed *Ascariasis lumbricoides*. Patient was treated with antibiotics for the liver abscess and a single dose of albendazole for the helminthic infection. There were no worms visualized during a two-month follow-up ERCP to remove the common bile duct stent and he remained symptom-free.

This case features a unique cause of biliary obstruction due to ascariasis infection in a patient who immigrated from the Federal State of Micronesia. Although ascariasis is a rare cause of biliary obstruction in the developed world, such cases are common in developing countries. In a report from India, up to one third of the causes of biliary and pancreatic diseases are attributed to ascariasis. Therefore, clinicians should have a higher suspicion for ascariasis as cause of biliary obstruction when evaluating travelers from endemic areas, especially when there is an associated eosinophilia. Early recognition of the ascariasis as etiology for obstruction is crucial as it can prevent complications such as cholangitis and liver abscess by easily treating with albendazole.

Poster #26

WHAT IS THE CAUSE OF SEVERE HEADACHE IN THIS 28-YEAR-OLD ASIAN MAN? A RARE CASE OF INTRACRANIAL MIXED GERM CELL TUMOR

Christina Park, MD¹, Maveric Abella, MS³, Kuo-Chiang Lian, MD, FACP^{2,3}

¹University of Hawai'i Internal Medicine Residency Program, Honolulu, HI

²University of Hawaii John A. Burns School of Medicine, Honolulu, HI

³The Queen's University Medical Center, Honolulu, HI

Germ cell tumors (GCTs) typically arise in the gonads and have a predilection for brain metastasis in about 15% of cases. Extragonadal GCTs typically arise in the anterior mediastinum, retroperitoneum and intracranial regions in adults, and sacrococcygeal and intracranial regions in children. This case features a rare primary extragonadal GCT found in the corpus callosum of an adult male.

A 28-year-old Filipino male with a history of thalassemia minor presented with left-sided weakness and generalized headache described as cramping, associated with nausea and vomiting for two days. The patient reported no trauma or fall, nor any focal neurologic symptoms. Initial exam was notable for decreased strength in left upper and lower extremities, grade 2/5 and 4/5, respectively. MRI brain demonstrated a 4.5 cm corpus callosum hemorrhagic mass extending into the right lateral ventricle with obstructive hydrocephalus, suggestive of central neurocytoma. Neurosurgery was consulted for tumor resection. While awaiting surgery, the patient had a partial seizure, which was resolved with levetiracetam. Subsequently, he underwent craniotomy, ventriculocisternostomy of the third ventricle, and external ventricular drain placement. Postoperative MRI revealed residual tumor, edema of the resection site and an acute lacunar infarction of the right centrum semiovale. Pathology of resected tissue revealed a malignant mixed germ cell tumor with immature teratoma (75%), germinoma (20%), and yolk sac tumor (5%), with positive AFP and hCG markers, suggestive of nongerminomatous germ cell tumor (NGGCT). At this time, a scrotum exam was performed and ultrasound was obtained, which was negative for any mass. CT of chest, abdomen and pelvis, and spine MRI did not show metastasis. Postoperatively, patient was found profoundly weaker. This was presumed to be from post-surgical edema and was treated with steroid taper. Within two weeks of steroids and physical therapy, the patient's strength improved to 4+/5 in all extremities. The patient was discharged to a rehabilitation facility with plans to initiate chemoradiation therapy.

Primary intracranial GCTs are very rare. Most common sites are pineal gland and suprasellar regions. Peak incidence is during teenage years, and with male predominance. In the United States, there is a higher incidence among Asians and Pacific Islanders. Common symptoms include headache, vomiting, and lethargy; endocrinopathies may be present when involving hypothalamic and pituitary glands. GCTs can be categorized into germinoma and NGGCT consisting of yolk sac tumor, choriocarcinoma and teratomas. The standard of care for localized germinoma is radiation as it is exquisitely sensitive to radiation with 90% progression-free survival. In contrast, NGGCTs have poor prognosis and require multimodality therapy consisting of neoadjuvant chemotherapy and craniospinal irradiation.

Poster #27

PRIMARY EFFUSION LYMPHOMA (PEL): VIGILANCE IS KEY TO DIAGNOSIS

Andrew Pham, MD¹ and Kaori Arnone, MD²

¹University of Hawaii Internal Medicine Residency Program, Honolulu, HI

²Queen's University Medical Group, Pulmonary and Critical Care, Honolulu, HI

Introduction:

PEL is a rare large B-cell lymphoma caused by human herpesvirus type 8 (HHV-8), often associated with human immunodeficiency virus (HIV) infection. PEL presents as effusion affecting the pleural, peritoneal, or pericardial space, typically without a detectable mass. A common presentation is an immunocompromised male with shortness of breath and pleural effusion on imaging. For our case, we present a rare case of PEL in an immunocompetent individual with initial workup negative for malignancy.

Case Presentation:

A 90-year-old male with a history of chronic kidney disease, diabetes mellitus, and hypertension presented with shortness of breath. Computed tomography (CT) of the chest showed moderate left pleural effusion and a 3 mm nodule in the right upper lobe (RUL). Left-sided thoracentesis indicated that the effusion was exudative and monocyte-predominant. However, cytology did not find evidence of malignant cells and cultures had no growth. The patient later presented with dyspnea and bilateral lower extremity edema. Chest x-ray demonstrated an enlarged heart, along with recurrence of left pleural effusion. Electrocardiogram revealed atrial flutter and results were significant for elevated Troponin and B-Natriuretic Peptide of 294. Echocardiogram was unremarkable and he was managed with diuretic therapy. He also underwent repeat left-sided thoracentesis, but cytology was not investigated as his symptoms were suspected to be secondary to acute decompensated heart failure. The patient presented again with dyspnea and chest x-ray displayed bilateral pleural effusions. Repeat CT chest showed a stable 4 mm ground-glass nodule in the RUL. Right-sided thoracentesis was performed. Cytology of the pleural effusion exhibited abnormal cells with enlarged regular nuclei and prominent nucleoli, positive for CD45/LCA, CD30, and HHV-8, consistent with PEL. Positron emission tomography (PET) scan revealed pericardial hypermetabolism suggesting pericardial involvement, but no evidence for nodal or solid organ involvement. The patient opted not to proceed with chemotherapy. A right indwelling tunneled pleural catheter was placed due to rapid symptomatic pleural fluid re-accumulation.

Conclusion:

The diagnosis of PEL is confirmed with fluid or biopsy demonstrating large, multinucleated lymphoid cells expressing markers such as CD45. Although it most commonly presents in young males with advanced HIV, it can occur in elderly immunocompetent patients infected with HHV-8, such as our patient. It should be noted that the initial cytology for our patient did not identify any malignant cells. Another case report of a patient with confirmed diagnosis of PEL had thoracentesis with cytology that was also negative for malignancy. It is likely that initial cytology may miss PEL, and a high index of suspicion is key for timely diagnosis.

Poster #28

A CASE OF GLEICH SYNDROME (EPISODIC ANGIOEDEMA WITH HYPEREOSINOPHILIA): UNDERSTANDING ITS CONTEXT WITHIN THE FRAMEWORK OF EOSINO

Nicholas Richwagen, MD¹, Javier Barranco-Trabi, MD¹, Ryan Jones, MD², Oliver Lee, MD³

¹Department of Medicine Training Program, TAMC, Honolulu, HI

²Department of Medicine, TAMC, Honolulu, HI

³Hematology/Oncology Service Chief, TAMC, Honolulu, HI

Introduction: Episodic angioedema with eosinophilia (EAE), also called Gleich syndrome, is a rare disease characterized by recurrent episodes of hypereosinophilia (HE), angioedema, weight gain, and elevated IgM immunoglobulin.

Eosinophilia is the presence of serum absolute eosinophil account (AEC) > 500 cells / μ L. Hypereosinophilia, AEC > 1500 cells / μ L, often presents with severe symptomatology attributable to eosinophilic tissue damage. Eosinophilia is associated with many diverse conditions, though principally in atopic (allergic/asthmatic) reactions and helminth infections. Autoimmune diseases, primary immunodeficiencies, and select malignancies are other notable causes. Hypereosinophilic syndrome (HES) includes conditions of any etiology with sustained HE and organ damage directly attributable to eosinophils.

Overwhelmingly, treatment revolves around managing underlying causes, but in HES acute reduction in AEC is key in preventing potentially fatal progression. EAE does not meet consensus criteria for HES as it does not cause tissue damage. Research suggests both EAE and HES are T-cell mediated diseases.

Case Presentation: An 86-year old male with hypertension presented to the ER with swelling in bilateral hands, lips, and mouth with complaints of difficulty swallowing. Vital signs were notable only for hypertension. Exam findings significant for bulbous swelling of lips and bilateral hands. Labs were concerning for elevated CRP and hypereosinophilia (AEC 19,900 cells / μ L).

After confirming stable airway, initial workup focused on allergy/medication history, as several medications had recently been discontinued and patient had started consuming almond milk. Allergy consultation focused on acquired vs. NSAID-induced angioedema; however, C4/C1EI levels were normal. Ultimately, allergic involvement was deemed unlikely in the absence of hives/urticaria, and with multi-day symptomatology. Infectious disease workup revealed no evidence of helminthiasis, erysipelas, HSV, or mycoplasmosis.

Further chart review revealed similar presentation 8 years prior resolving with corticosteroids. Conversation with family elicited descriptions of prior episodes of facial/upper-extremity edema. Testing identified elevated IgM (2026 mg/dL) and normal cell morphology on blood smear. In the setting HE, elevated IgM, and prior episodes of swelling, EAE became the working diagnosis after excluding malignancy. Treatment with prednisone saw rapid improvement. Patient was discharged after 6 days tapering steroid treatment.

Discussion: Our patient met inclusion criteria for Gleich syndrome proposed by Mormile et al. (2021): (1) episodic and recurrent angioedema with (2) blood HE, and (3) exclusion of all alternate diagnoses for both angioedema and HE. However, aspects of presentation and history were atypical with no evidence of sustained monthly episodes and absence of pruritic urticaria. As the disease remains extremely rare, with only <40 published case reports available as of early 2019, Our case adds to the body of evidence behind diagnosis and management of this unusual syndrome.

**ACUTE CEREBROVASCULAR EVENTS ASSOCIATED WITH COVID-19 INFECTION
IN A MULTI-ETHNIC POPULATION IN HAWAII**

Parthav Shah, MD¹; Koichi Keitoku, MD¹; Pola Chojecka, MD^{2,4},

Gehan Devendra, MD^{3,4}; Stacy C. Brown, MD^{2,4}

¹University of Hawaii Internal Medicine Residency Program, Honolulu, HI

²Neuroscience Institute, Queens Medical Center, Honolulu, HI

³Department of Pulmonary Critical Care Medicine, Queens Medical Center, Honolulu, HI

⁴University of Hawaii John A. Burns School of Medicine, Honolulu, HI

Introduction/Rationale:

Coronavirus disease 2019 (COVID-19) has been associated with an increased risk of acute cerebrovascular events (ACE). Disparities in COVID-19 outcomes by race and ethnicity have also been described. We sought to characterize and describe the multi-ethnic population of COVID-19 patients with associated stroke or transient ischemic attack (TIA) presenting to our tertiary medical center in Honolulu, HI.

Methods:

We performed a retrospective, cross-sectional study of adult patients (ages ≥ 18 years) admitted to our tertiary medical center between January 2020 and May 2022 with COVID-19 infection confirmed by positive severe acute respiratory syndrome coronavirus 2 reverse transcriptase–polymerase chain reaction test. Patients with cerebrovascular disease in their chart problem lists were identified. We then conducted manual chart review to confirm diagnoses of acute ischemic stroke, hemorrhagic stroke, or TIA. Patients were excluded if the ACE occurred more than 30 days before or after COVID-19 diagnosis. Outcome data as well as demographic and medical variables known to be associated with cerebrovascular disease were collected.

Results:

A total of 5911 patients were included (mean age 63.71 ± 19.2], female 2635 [44.6%]). Among these, 112 (1.9%) patients developed ACE within 30 days of positive COVID test. Out of the patients who had ACE, 93 patients had ischemic stroke, 13 had hemorrhagic stroke and 5 patients had TIA. Patients with ACE had a mean age of 68.2 and majority were male (60.7%). These patients were predominantly Filipino (36.6%), White (16.1%), and Native Hawaiian (13.4%). 40.2% were admitted to the intensive care unit. The mortality rate was 13.4%. 33% were discharged to a destination other than home.

Discussion:

In a multi-ethnic population of COVID-19 patients presenting to a tertiary medical center in Honolulu, HI, ACE occurred in 1.9% of patients. Patients with ACE trended toward higher ICU admission and mortality rates. Future studies aim to further characterize stroke subtypes in this population and determine associated risk factors and outcomes.

A CASE OF DISGUISED LATE-STAGE DIFFUSE LARGE B-CELL LYMPHOMA PRESENTING WITH SEVERE TYPE B LACTIC ACIDOSIS

Dylan Singh, MS¹, Kuo Chiang Lian, MD³, Jason Kuniyoshi, MD² and Alison Goo, MD²,

¹University of Hawaii John A. Burns School of Medicine, Honolulu, HI

²University of Hawai'i Internal Medicine Residency Program, Honolulu, HI

³The Queen's Medical Center, Honolulu, HI

Introduction: Most reported cases of type B lactic acidosis are associated with hematologic malignancies, including lymphomas. Cases of large B-cell lymphoma (DLBCL) specifically, leading to type B lactic acidosis, are both scarce and poorly understood. Herein, we present a unique case of late stage DLBCL and secondary chronic type B lactic acidosis, presenting as rapidly progressive, ill-defined abdominal mass.

Case Report: A 73-year-old female presented with chief complaints of shortness of breath, abdominal pain, 40-pound weight loss over the past six months, fatigue, and bilateral lower extremity edema. On admission, the patient had a right sided hydropneumothorax with pleural fluid negative for malignancy. CT scan revealed irregular thickening of the distal stomach, which ascites. The patient was scheduled for biopsy via EGD; however, the procedure was postponed due to other complicating factors, including acute hypoxia. The patient was found to have a lactic acidosis of 14mg/dL and was treated with recurrent intermittent bicarbonate infusions with limited effect. Furthermore, the patient suffered from numerous repeated hypoglycemic episodes. Repeat CT was later performed which revealed that the mass may have originated from the head of the pancreas and extended into the stomach and duodenum. In addition, there was spread of the presumed malignancy into the porta hepatis, a circumferential gastric mass, and omental thickening which was biopsied. Unfortunately, the patient's condition continued to deteriorate, requiring transfer to the intensive care unit for hypoxic respiratory failure. Despite medical management, the patient's respiratory function continued to decline with eventual transition to comfort measures only and expiration. The omental mass biopsy revealed a high-grade B-cell lymphoma, consistent with diffuse large B-cell lymphoma, germinal center type.

Discussion: This study presents a unique case of DLBCL associated with type B lactic acidosis. Initially, the patient's chief complaints were suspicious for malignancy despite the negative pleural fluid. The imaging revealing gastric thickening was presumed to be primary gastric malignancy without metastatic progression. This was difficult to biopsy given the patient's unstable respiratory condition, which resulted in delayed treatment and time for possible metastatic progression. Interestingly, repeat imaging revealed that the mass may actually be originating from the pancreatic head, while the patient experienced recurrent hypoglycemic episodes. The elevated lactic acid in the absence of hypoperfusion conditions, was suspicious for type B lactic acidosis. Given that imaging studies support hepatic it is possible that the patient's persistently elevated lactate levels was due to the metastatic lesion hindering the liver's metabolic activity.

Conclusion: Overall, this disguised presentation of a Type B lactic acidosis associated DLBCL was quite unique. Due to its location, other differential diagnoses included pancreatic and gastric malignancies. This deadly malignancy can present atypically, with rapid clinical deterioration making the diagnosis difficult. This case illustrates the need to also have a high degree of suspicion for hematologic malignancies in the setting of an extremely high lactic acidosis and potential abdominal mass.

Poster #31

CHARACTERISTICS OF OLDER ADULTS WITH POSITIVE NEUROCOGNITIVE SCREENS IN THE GERIATRIC ED

Mikayla L. Sonnleitner¹, Vaishal M. Toila, and Edward M. Castillo²

¹University of Hawaii John A. Burns School of Medicine, Honolulu, HI

²University of California, La Jolla, CA

Background:

The older adult population has a higher risk for developing neurocognitive disorders and is rapidly increasing worldwide, leading to increased use of emergency services. Geriatric Emergency Departments (GEDs) with specialized geriatric nurses can improve the identification of neurocognitive disorders and change clinical management. The purpose of this study is to describe characteristics of older adults with positive neurocognitive screens, and determine whether seeing specialized geriatric nurses changes clinical management.

Methods:

We conducted a retrospective study among older adult patients (≥ 65 years) who received care at Level 1 Accredited GED from 12/1/2016 through 6/30/2022. Demographic (sex, age, and ethnicity) and specialized screening results were compared between patients with positive and negative neurocognitive screen for screens for delirium, cognition, and Alzheimer's. Statistical analysis included two sample t-tests, and p-values < 0.05 were considered statistically significant.

Results:

56,326 patients over 65 were seen in the La Jolla ED, 22,200 (39.4%) of which qualified to receive specialized services. Of these patients, 5,355 (24.1%) patients were seen by a specialized geriatric nurse and 463 (8.6%) of these patients had positive neurocognitive screening results. Patients with positive screening results had a higher average age included more minority populations (avg age = 82 vs 77; race = 37.5% Black, Asian, and other/mixed race combined vs 32.2%; and Hispanic ethnicity = 13.8% vs 12.7%; 32.2%; $p < 0.05$). There were no significant differences in sex ($p > 0.05$). Patients with positive neurocognitive screens had higher positivity rates on screening assessments for Activities of Daily Living (54.9%), depression (41.2%), elder abuse (1.2%), and malnutrition (42.6%) compared to their counterparts (26%, 31.3%, 0.8%, and 26.6%, respectively; $p > 0.05$). A total of 59.7% of patients who saw a specialized geriatric nurse were referred, compared to only 13.5% of patients who did not see one ($p < 0.05$).

Conclusions:

Overall, patients who were seen by specialized geriatric nurses had higher detection rates on neurocognitive screens, had more referrals, and were more likely to be positive on other screens. The implementation of geriatric EDs and specialized geriatric nurses has great implications for the care and quality of life of the aging population.

**POSTERIOR CIRCUMFLEX HUMERAL ARTERY
ANEURYSM FROM WEIGHT TRAINING**

Megan P. Sterling, DO¹ and William J. Wadzinski, MD, FACP²

¹Dept of Medicine Training Program, TAMC, Honolulu, HI

²Dept of Medicine, TAMC, Honolulu, HI

Posterior circumflex humeral artery aneurysm (PCHA) is an extremely rare condition reported to affect young professional athletes. These aneurysms can lead to ischemia of the arm, forearm, hand, or fingers. A 2019 literature review highlighted the diagnostic challenges with PCHA due to patient population, rarity of condition, and likelihood of clinicians to mis-attribute this disease process to acute or chronic musculoskeletal injuries. Prompt recognition, diagnosis, and treatment of PCHA is critical as a delay or failure to diagnose can have a catastrophic impact on an individual's livelihood and overall functionality.

We present the case of 22-year-old active-duty marine with PCHA. Two months prior to diagnosis, he presented to his primary care manager with right shoulder pain after strength training exercises. He later presented to our institution where an evaluation with angiogram revealed PCHA with distal occlusion of an 8cm segment of the brachial artery and subsequent distal reconstitution. He was treated with tPA/heparin for thrombolysis. On hospital day three, he had a physical exam that was back to his baseline. He was provided activity restrictions and discharged to his home. One month later, he underwent coil embolization of the left posterior humeral circumflex artery aneurysm. His post-operative course was uneventful, and he returned to activity without restrictions one month following coil embolization.

The typical presentation of PCHA is a young professional athlete complaining of ischemic symptoms, defined as pain, numbness, or digital cyanosis. Exam findings may reveal absence of pulses in the affected extremity without neurologic deficits. Diagnosis is obtained most frequently through Doppler Ultrasound or Angiography and less commonly via Magnetic Resonance Angiography or CT-Angiography. Treatment is not standardized, but modalities include embolization, resection without revascularization, fibrinolytic treatment, or observation. Given a young, active, and athletic patient clinicians should consider vascular injuries in their differential diagnosis.

Poster #33

CT-BASED SCREENING FOR MODERATE TO SEVERE HEPATIC STEATOSIS IN A MULTIETHNIC POPULATION

Melia N. Takakusagi, BS¹, Ruixue Zhang, BS¹,

Bradley J.I. Thomas, BA¹, and Hyo-Chun Yoon, MD²

¹University of Hawaii John A. Burns School of Medicine, Honolulu, HI

²Hawaii Permanente Medical Group, Department of Internal Medicine, Honolulu, HI

Background and Aim:

Data on prevalence of Nonalcoholic Fatty Liver Disease (NAFLD) in Hawai'i is limited. We determined the prevalence of moderate to severe hepatic steatosis within a multi-cultural, multi-ethnic, and multi-racial cohort in Hawai'i undergoing CT for reasons unrelated to fatty liver disease.

Methods:

We performed a retrospective analysis of patients between 20-75 years of age whom were members of an integrated healthcare system with CT scans including the liver between 1/1/2020 and 12/31/2020. On each CT scan, 4 regions of interest (ROI) of the liver were obtained. The mean of all 4 ROIs was calculated to adjust for liver heterogeneity. Moderate to severe hepatic steatosis was determined by an average ROI attenuation value less than 40 Hounsfield units (HU) for non-contrast-enhanced CT and a mean ROI less than 90 HU for contrast-enhanced CT. Patients' EMR were reviewed for existing diagnoses of hepatic steatosis, obesity, and diabetes mellitus type 2, data to calculate a FIB-4 index, and self-reported race and ethnicity.

Results:

26.6% of patients were found to have moderate to severe hepatic steatosis, while only 11.3% of those patients had an active diagnosis of fatty liver disease in their EMR. Native Hawaiians and Pacific Islanders (33.1%) had the greatest prevalence of hepatic steatosis followed by Whites (28.4%), Asians (27.7%), and other ethnicities (10.8%). 61.4% patients with fatty liver were found to obese, while 33.4% had a BMI <30.0 kg/m². 26.1% of patients with liver steatosis had an active diagnosis of type 2 diabetes mellitus. While 86.2% patients had enough information in their EMR from which to calculate a FIB-4 score and the mean FIB-4 index was 1.66 ± 3.50 .

Conclusions:

Moderate to severe hepatic steatosis is common among patients, particularly Native Hawaiians and Pacific Islanders, undergoing CT studies for reasons not related to hepatic steatosis in this multiethnic population, most of whom did not have a diagnosis of fatty liver disease. Therefore, there may be considerable value in having radiologists evaluate for hepatic steatosis in patients undergoing CT for reasons unrelated to fatty liver disease.

Instructions for claiming CME credit and MOC Points

Go to the Hawai‘i Chapter webpage and follow the prompts to claim credit and points.

The American College of Physicians (ACP) is accredited by the Accreditation Council for Continuing Medical Education (ACCME) to provide continuing medical education for physicians.

The ACP designates this other activity (live component and enduring component) for a maximum **6.50 AMA PRA Category 1 Credit(s)**[™]. Physicians should claim only the credit commensurate with the extent of their participation in the activity.

Successful completion of this CME activity, which includes participation in the evaluation component, enables the participant to earn up to 5.5 medical knowledge MOC point in the American Board of Internal Medicine’s (ABIM) Maintenance of Certification (MOC) program. It is the CME activity provider’s responsibility to submit participant completion information to ACCME for the purpose of granting ABIM MOC credit.

Mahalo for joining us!

Index

- Abella, 47
Ah Cho, 24
Aiumtrakul, 22
Al Daheen, 23
Ali, 18
Aramaki, 18
Arayangkool, 15
Arnone, 48
Asai, 13
Aurelio, 13
Azuma, 33

Banerjee, 40
Barranco-Trabi, 24, 32, 36, 49
Benavente, 38, 39
Bettick, 17
Biala, 17
Brown, 13, 50

Castillo, 52
Chang, 25
Chau, 26
Cheng, 27, 28
Choi, H, 14
Choi, J, 13
Chojacka, 50
Choo Loy, 19
Christensen, 18
Chun, 29
Colgan, 14
Copeland, 37
Crump, 30, 31
Czech, 39

Devendra, 50
Doi, 19

Ehrlich, 17
Estaris, 46

Gearhart, 17
Geniza, 32
Giacoppe, 37
Goo, 51

Gozun, 33

Ha, 33
Hancock, 37
Hattori, 34
Holmgren, 19, 35
Honda, 43
Houser, 36
Huang, 33

Ibrao, 18
Ikeda, 20

Jones, 37, 49

Kaya, 43
Keitoku, 20, 33, 50
Kieu, 27
Kileci, 41
Kim, 26
Kistler, 14
Kolberg, 37
Kozai, 38, 39, 46
Kuniyoshi, 40, 51
Kurasaki, 18
Kuwada, 42, 44
Kwock, 40
Kwong, 45

Laimana, 41
Lau-Amii, 28
Lee, 15, 35, 42, 49
Lian, 15, 34, 38, 39, 46, 47, 51
Lo, 18

Manibusan, 32
Manibusan, 16
Mank, 24
Martino, 16
Marumoto, 27
Masaki, 18
Mathews, 43
Mercado, 14, 23
Moriwara, 40

Nagamine, 33
Nishimoto, 25
Nishimura, 14, 33

Orcine, 18
Owodunni, 17

Pandula, 19, 30, 31
Pang, 44
Pappo, 45
Park, 34, 38, 39, 46, 47
Perkins, 37
Pham, 20, 33, 48

Rho, 45
Richwagen, 49
Roberts, 24

Seto, 19
Shah, 33, 50
Shi, 26
Silangcruz, 40
Singh, 51
Sonnleitner, 52
Sterling, 53
Su, 27
Sylvester, 18

Takakusagi, 54
Takenaka, 18
Tanaka, 22
Thomas, 54
Toila, 52

Verhoef, 25, 29, 35

Wadzinski, 24, 36, 53
Watai, 22
Wen, 18
Wong, 27

Yoon, 54

Zhang, 54

Mahalo to our Sponsors!

AstraZeneca

What science can do

AstraZeneca plc is a multinational pharmaceutical and biopharmaceutical company headquartered in Cambridge, England. It has Research and development concentrated in three strategic centres; Cambridge, Gothenburg, Sweden and Gaithersburg, U.S. AstraZeneca has a portfolio of products for major disease areas including cancer, cardiovascular, gastrointestinal, infection, neuroscience, respiratory and inflammation. AstraZeneca AB, the Swedish arm of the company, is a subsidiary of Astra Zeneca plc.

<https://www.astrazeneca.com/>

Contact Specialist:

Michael Ocasek

AstraZeneca

Respiratory Specialty Team - Hawaii

(808) 255-8685 cell phone

Michael.ocasek@astrazeneca.com



What is eNavvi?

We are a healthcare IT startup that helps prescribers throughout the prescription decision process; our first product is a formulary navigator that shows prescribers and patients how much a patient's drugs will cost and any requirements to prescribe it, among other useful data. In the long term we are building a platform to streamline healthcare delivery by democratizing data for clinicians and patients while helping insurers meet transparency regulatory compliance.

Simon Chang, DO
626-755-0500
simon@enavvi.com

Alex Prevallet, DO
alex@enavvi.com



GlaxoSmithKline

GSK is a science-led global healthcare company with a mission to help people do more, feel better, live longer. We research, manufacture and make available a broad range of medicines, vaccines and consumer healthcare products. Visit our exhibit for information about our products and resources.

<http://www.gsk.com/>

Account Specialist contact information:

Chris A. Furuya
GSK - Hawai'i Representative
808-497-7571 Cell phone
Chris.a.furuya@gsk.com



Join the Hawai'i Pacific Health Medical Group which is comprised of more than 700 employed physicians, advanced practice registered nurses and physician assistants. Together with our four hospitals (Kapi'olani, Pali Momi, Straub, and Wilcox) and more than 50 convenient clinic locations statewide, our nonprofit health system is one of the state's largest health care providers. Our network of primary care providers and specialists work together to provide a distinctive and effective model of coordinated care for maintaining the health and wellness of our patients.

For more information, visit our website:

<https://physician.hawaiipacifichealth.jobs/>

Please send CV and Cover Letter to: Peggy G. Peros Andes, Physician Recruiter

✉ peggy.andes@hphmg.org

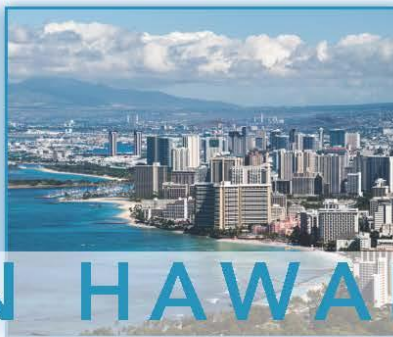☎ 808-522-3006

📠 808-522-4006

LIVE.



WORK.



PLAY.



IN HAWAII

Creating a *healthier* Hawai'i

EOE/AA/Disabled/Vets



INTERNAL MEDICINE

INTERNAL MEDICINE SUBSPECIALTIES

Hawaii Permanente Medical Group is the state’s largest and most experienced multi-specialty group comprised of over 600 providers dedicated to providing the highest quality clinical care and building lifetime relationships with peers and patients within Hawaii’s richly diverse communities.

OPPORTUNITIES AT HPMG:

- Addiction Medicine (Oahu)
- Cardiology (Oahu)
- Critical Care Medicine (Oahu)
- Endocrinology (Oahu)
- Internal Medicine (Big Island, Maui)

HPMG OFFERS AN EXCELLENT INCENTIVE AND BENEFIT PACKAGE:

- Relocation Allowance
- Pension plus Profit-Sharing Plans
- Flexible Spending Plans
- Vacation and Paid Holidays
- Comprehensive Medical and Dental Insurance
- Educational Leave and Allowance
- Sick Leave and Disability Income Benefits
- Professional Liability Insurance
- Identity Theft Protection

TO APPLY:

For Addiction Medicine, Cardiology, Endocrinology
Send your Cover Letter and CV to:

Ms. Amy Akamine, Recruiter

Email: Amy.RA.Akamine@kp.org

Phone: (808) 432-5679, press option 2

Fax: (808) 432-5827

For Critical Care Medicine and Internal Medicine
Send your Cover Letter and CV to:

Ms. Thao Hartford, Recruiter

Email: Thao.Hartford@kp.org

Phone: (808) 432-5679, press option 1

Fax: (808) 432-5827

For Locum Tenens Employment:

Send your Cover Letter and CV to:

Ms. Kristen Yamabe, Recruiter

Email: Kristen.S.Yamabe@kp.org

Phone: (808) 432-5679, press option 4

Fax: (808) 432-5827

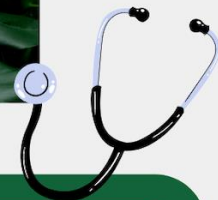careers.hawaiipermanent.com

Equal Opportunity and e-Verify Employer



IMIG

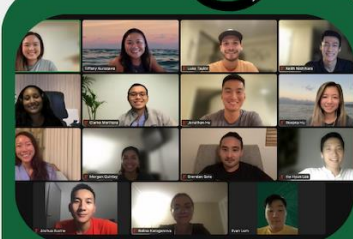INTERNAL MEDICINE INTEREST GROUP



Our annual Subspecialty Mixer allows medical students to discover all internal medicine has to offer.



IMIG members volunteer at a blood pressure clinic.



Meet our 2022-2023 IMIG Board!

About Us

IMIG is a student-run interest group at the John A. Burns School of Medicine (JABSOM). We're dedicated to providing information about careers in internal medicine, fostering communication between students and physicians, and connecting with the community to promote health awareness.

Past Events (Fall 2022)

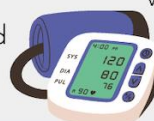- Subspecialty Mixer
- JABSOM IM Resident Panel
- ACP Pau Hana
- UHIMRP Primary Care Forum
- Amyloidosis Bureau Patient Speaker
- Physician Mentorship Program
- Journal Club
- Check Your Pressure (CYP) x IMIG: Blood Pressure Clinic
- Preclinical Unit Review Sessions

Upcoming Events (Spring 2023)

- Health Fair Initiative
 - Coming this March
 - Location: Cultural Plaza
 - Provide blood pressure, glucose, lipid, and BMI checks to the local community
- IMIG x JAM: Hawaii ACP Chapter's Rock the Doc
 - Coming this April, in collaboration with JABSOM Artists and Musicians (JAM)
 - Join us along with the Hawaii ACP Chapter to showcase your talents and enjoy free food and drinks
- Ultrasound Workshop
 - Coming this April
 - Dr. Yoshito Nishimura will lead a POCUS workshop for interested students

Contact us!

✉ uhimig@hawaii.edu
 🌐 <https://imig.uhmed.org/>



A ROYAL VISION HAS BECOME TODAY'S PREMIER HEALTH SYSTEM IN HAWAII

The Queen's Health Systems is a proud supporter of
the American College of Physicians Annual Regional Scientific Program.

In 1859, more than 160 years ago, Queen's began as a single hospital
founded by Queen Emma and King Kamehameha IV to provide in perpetuity health care and healing
for Native Hawaiians and all of the people of Hawai'i. Today, that mission remains the same,
but now extends to four hospitals and over 70 health care centers
and labs throughout Hawai'i and the Pacific Basin.



**THE QUEEN'S
HEALTH SYSTEMS**

www.queens.org



The Queen's Medical Center
Punchbowl



The Queen's Medical Center
West Oahu



Molokai General
Hospital



Queen's North Hawai'i
Community Hospital



Sanofi

Pharmaceutical Company

"We chase the miracles of science to improve people's lives".

[linkin.bio/sanofi](https://www.linkedin.com/company/sanofi)

Tim Cason

Medical Specialist –

Regeneron Healthcare Solutions

777 Old Saw Mill River Road

Tarrytown, NY 10591-6707

Cell: 949/342-0362

Email: timothy.cason@regeneron.com

Denise Grundy

Area Business Manager

Pulmonology Specialty Care Division

Sanofi

Cell Phone: [310-968-6646](tel:310-968-6646)/310-382-4102

Email: denise.grundy@sanofi.com

SANOFI

450 Water Street, Cambridge, MA 02141

USA

Phone 1-617-252-7500



Service with a caring heart. That's UHA.

UHA was founded by physicians,
and the caring that physicians
have for people, really powers
our company. Here's to **over 25**
years of better health.



Index: