

# Clinical Pearls in Headache Management

LYNSEE HUDSON, MD  
NEUROLOGIST  
COLORADO PERMANENTE MEDICAL GROUP  
DENVER, CO

# Disclosures

- ▶ No Disclosures



# Learning Objectives

- ▶ Recognition & sensible workup of Primary vs Secondary Headache
- ▶ Identification of migraine type headache vs trigeminal autonomic cephalgias
- ▶ Acute home & in-office abortive strategies for refractory migraine
- ▶ Treating analgesic overuse headache & preventing recurrence

# Common Primary Headache Syndromes

- ▶ Migraine and Migraine variants (w/aura, basilar, retinal, hemiplegic)
- ▶ Tension Type Headache
- ▶ Primary Cough, Coital, or Exertional Headache
- ▶ Trigeminal Autonomic Cephalgias



# Common Secondary Headaches

- ▶ Medication Overuse Headache
- ▶ Giant Cell Arteritis
- ▶ Low Pressure Syndromes (CSF leak)
- ▶ High Pressure Syndromes (venous occlusion, mass, edema)
- ▶ Infectious Headache
- ▶ Traumatic Head or Neck etiologies
- ▶ Acute Stroke or Blood
- ▶ Nocturnal Hypoxia

# Recognizing Migraine

5 attacks fulfilling criteria below

- A. 1 of 2: Photophobia/phonophobia **AND/OR**  
Nausea or vomiting
- B. 4-72 hours duration
- C. 2 of the following: unilateral  
pulsating  
moderate to severe  
worse with activity



# Recognizing Migraine Aura

- ▶ Recurs more than 1 time
- ▶ **Last more than 5 minutes but less than 60 minutes and has one of the following:**

Fully reversible visual symptoms (scintillation, flickering, spots) OR loss of vision (homonymous field cut)

OR

Fully reversible sensory symptoms (tingling or numbness)

OR

Fully reversible dysphasia

# Red Flags of Secondary Headache

- ▶ Arousal from sleep or precipitated by valsalva
- ▶ Fever, neck stiffness with limited ROM
- ▶ Significant postural component
- ▶ New focal deficit or seizure
- ▶ Hx of head injury
- ▶ New thunderclap headache (peak intensity w/in 5 minutes)
- ▶ New headache in HIV, cancer, elderly, or pregnant patient
- ▶ Papilledema
- ▶ Temple tenderness, jaw claudication, or fever >50 yo



# When to image a Headache?

- ▶ If hx of migraine & no red flags, imaging is **NOT** warranted
- ▶ If no hx of migraine but diagnostic criteria met & no red flags, imaging is **NOT** warranted
- ▶ If atypical headache, consider imaging case by case
- ▶ If red flags, Consensus opinion:
  - MRI brain w/o gadolinium is more sensitive
  - CT head w/o contrast is more sensitive for acute blood

# Work up in Setting of Red Flags

**“Every headache does not need every evaluation”**

- ▶ Exertional headaches → CTA or MRA
- ▶ New deficit not consistent with aura → MRI without contrast
- ▶ Focal Tenderness in elderly +/- jaw claudication → ESR or CRP
- ▶ Obese w/ visual complaints → dilated eye exam
- ▶ Thunderclap headache → CT
- ▶ Fever, meningismus → CT and lumbar puncture
- ▶ High pressure features → MRV or CTV



# What if Patient Demands Imaging?

- ▶ CT imaging is very low yield in routine headache cases
- ▶ Counsel patients on risk of imaging and chance of a distracting incidental finding
- ▶ 1 in 8100 risk of cancer for routine head CT in women and 1 in 11,080 in men

Evans RW. Diagnostic testing for the evaluation of headaches. *Neurol Clin.* 1996;14;1-26.



# Case Review

- ▶ 28 yo obese female presents with 1 month of increasing headaches that are frontal in nature with phonophobia and light sensitivity, often worse in the morning. She also reports vague transient visual obscurations throughout the day with position change. Upon questioning, she also has some pulsatile tinnitus. Your exam reveals an obese female with a nonfocal exam. You aren't confident in your funduscopic exam but you cannot see spontaneous visual pulsations.



# What features suggest this is not migraine?

1. Visual obscurations with position change



2. Exclusively Frontal Nature



3. Absence of Spontaneous Venous Pulsations



4. All of the Above





Answer: D All of the above

Diagnosis: Idiopathic Intracranial  
Hypertension



# Idiopathic Intracranial Hypertension: Initial Work up

- ▶ Send for dilated eye exam if you cannot be certain of papilledema
- ▶ Urgent (within 48 hours) MRI/MRV of brain to exclude mass or sinus thrombosis
- ▶ Referral for LP for opening pressure and neuro consult for definitive treatment

# Trigeminal Autonomic Cephalgias: Not your Mother's Migraine

- ▶ Primary headaches w/ brief episodes of **SEVERE** unilateral headaches w/ ipsilateral **AUTONOMIC** features
- ▶ Within the group of TACs, difficult to distinguish
- ▶ Distinction from MIGRAINE is important because
  - TAC Headaches are disabling
  - Treatment Strategies are different
  - Misdiagnosis can be costly



# What are the Trigeminal Autonomic Cephalgias?

**Highest Attack**

**Frequency**

**Lowest Attack**

**Frequency**

Short lasting  
Neuralgiform  
Headache  
(SUNCT/SUNA)

Paroxysmal  
Hemicrania

Cluster  
Headaches

Hemicrania  
Continua

**Shortest Duration**

**Longest Duration**

# Clinical Features of TACS

- ▶ Pain is knife like, boring, or stabbing
- ▶ SEVERE to VERY SEVERE pain
- ▶ Site is often temple or orbit
- ▶ Duration of attacks are shorter than migraine on the order of minutes (except HC)
- ▶ Autonomic features are always present with attacks
- ▶ Often episodic or clustering

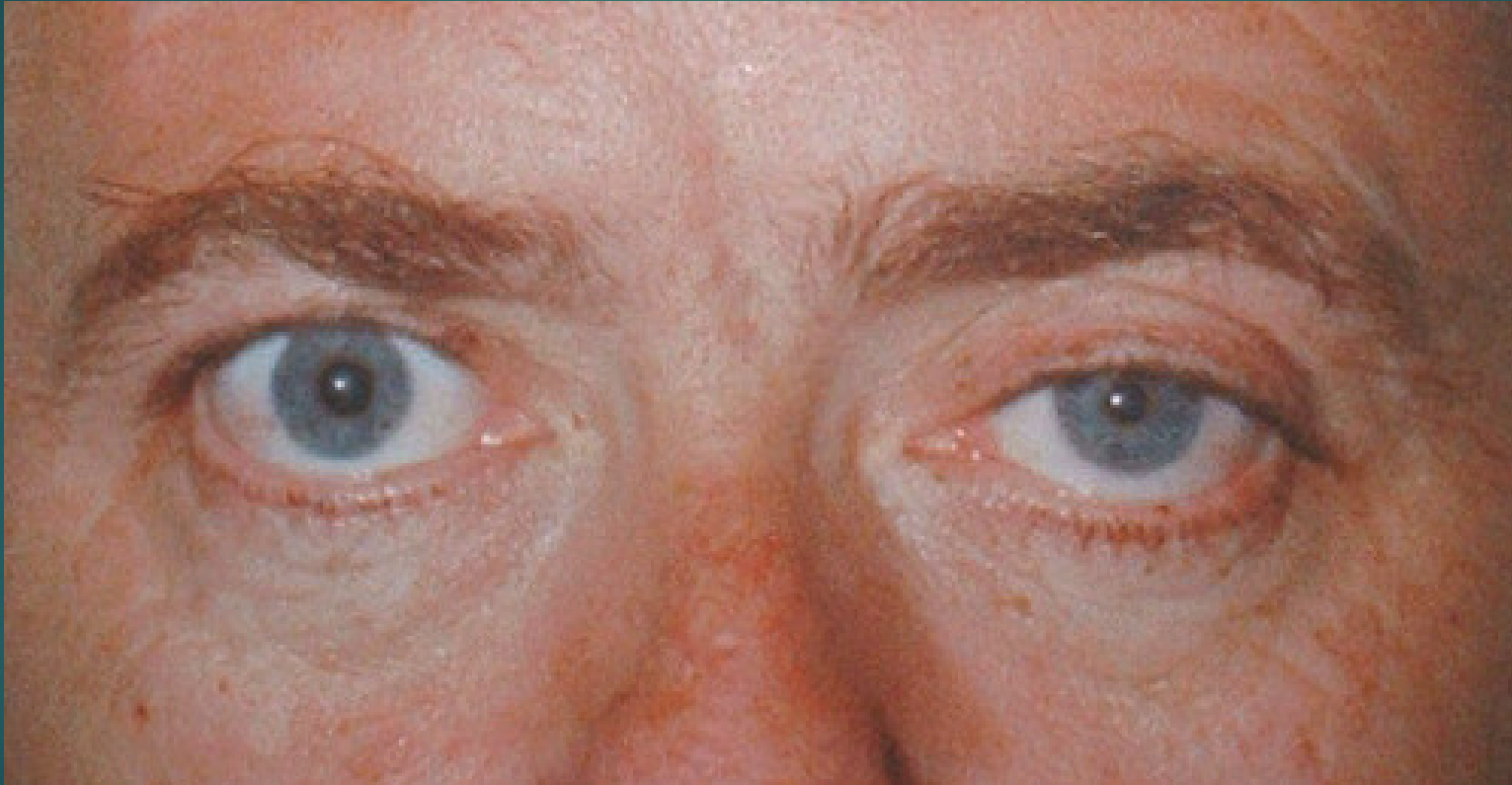

# Autonomic Features of TAC:

## Requires $\geq 1$ ipsilateral

- ▶ Conjunctival injection
- ▶ Lacrimation
- ▶ Nasal congestion or discharge
- ▶ Miosis
- ▶ Ptosis

# Horner's Syndrome



<http://www.reviewofophthalmology.com/content/d/oculoplastics/c/32801/>



# Do you need to Image the TACs?

- ▶ **YES!!!** Non-urgent **MRI brain w/o contrast**. Lesions in or around the pituitary can mimic TACs
- ▶ Persistent INTER-ATTACK autonomic features require CTA brain and neck emergently
- ▶ TACs can mimic carotid dissection

# Role of Primary Care

- ▶ Recognize TAC
- ▶ Order appropriate imaging (MRI for all, CTA for persistent autonomic exam findings)
- ▶ Initiate abortive and bridge therapies
- ▶ Consult electronically or formally with neurology



# Case Presentation:

- ▶ 44 yo man presents with right sided, knifelike, periorbital attacks waking him from sleep. Upon asking, he reports nasal congestion and watering of the right eye with the attacks. The attacks peak quickly, are intolerable making him restless, and seem to relent within 20-30 minutes. He has had 5 attacks mostly nocturnally in 2 weeks but none prior. His neurologic and general medical exam are normal, but on medication review you can see he has a new prescription for Cialis in the last month.

# What is the likely Diagnosis?

1. Spontaneous Carotid Dissection

 **6%**

2. Hypothalamic Mass

**0%**

3. Cluster Headache

 **66%**

4. Paroxysmal Hemicrania

 **28%**



# Answer? Cluster Headache

- ▶ Nocturnal attack predominance
- ▶ Short duration (15-180 mins)
- ▶ Autonomic features during attack
- ▶ Male predominance 1:3
- ▶ Alcohol, NTG, or PDE-5 inhibitors can triggers

# Work-up: New Cluster Headache

- ▶ Non-urgent MRI brain w/o gadolinium
- ▶ EKG to screen for heart block for utilization of CCB
- ▶ Consider consult electronically or formally with neurology



# Treatment: Cluster Headache

- ▶ **Abortive:** **1<sup>st</sup> Line:** Trial of high flow O<sub>2</sub> (10-15 L via nonrebreather) prn onset of attack  
**2nd Line:** Sumatriptan 4-6 mg SQ or 20 mg nasal spray up to bid
- ▶ **Bridge Therapy:** Prednisone, 60-80 mg/day taper over 2-4 weeks.
- ▶ **Preventive:** Verapamil 240-480 mg/d divided in 3 doses, short acting preferred, titrate slowly



# Case Presentation:

- ▶ 56 yo female presents with 4 months of steady, 3/10 side-locked headaches with superimposed attacks of severe, stabbing temple pain 3-4x week lasting 2-4 hours without nausea, photophobia, phonophobia. During the severe attacks, she has a perception of a foreign body in her left eye and left eyelid appears "droopy". She has tried naratriptan and sumatriptan with minimal response and takes amitriptyline 50 mg qhs with no reduction in frequency after 8 weeks. She does not use additional analgesics.



# What is the likely Diagnosis?

1. Giant cell Arteritis

 **10%**

2. Chronic Migraine

 **6%**

3. Hemicrania Continua

 **78%**

4. Medication Overuse Headache

 **6%**

# Answer? Hemicrania Continua

- ▶ Often misdiagnosed as migraine
- ▶ Side locked steady headache with superimposed severe unilateral attacks
- ▶ Autonomic features during severe attacks which can last hours to days
- ▶ Female predominance 2:1
- ▶ Uniquely responsive to indomethacin



# Work-up: New Hemicrania Continua

- ▶ Non-urgent MRI brain w/o gadolinium
- ▶ Serum creatinine for planned indomethacin use
- ▶ Consider formal or electronic consult with neurology

# Treatment: of Hemicrania Continua

- ▶ **Abortive:** Indomethacin up to 300 mg daily (often requires higher than FDA approved maximum daily dose of 150 mg).
- ▶ **Preventives:** topirimate, melatonin, occipital nerve blocks and occipital nerve stimulators



# Case Presentation

- ▶ 34 yo female with pmhx of anxiety, insomnia and migraine w/o aura presents with a 5 day history of her typical migraine to your clinic. She is tearful and overwhelmed after trying home strategies of rizatriptan plus ibuprofen for 3 doses over 2 days. She appears uncomfortable but has a nonfocal exam.

# Diagnosis? Status Migrainosus

## Description:

A debilitating migraine attack lasting for more than 72 hours.

## Diagnostic criteria:

- ▶ Features of **Migraine without aura** typical of previous attacks except duration
- ▶ Headache has both:
  - unremitting for >72 hours and severe intensity
- ▶ Not attributed to another disorder



# Status Migrainosus Treatment Pearls

- ▶ In future, treat typical migraine attack quickly & early to avoid central sensitization
- ▶ Recurrence w/in 24 hours = effective therapy with **TOO SHORT of HALF LIFE!** Change to LONG-ACTING triptan (frovatriptan) or repeat second dose of initial medication (table 1-1)
- ▶ Failed Response to Initial Appropriate therapy = Novel or combination **RESCUE** Strategy needed
- ▶ Consider using combination of lower risk therapies which can be synergistic

# Home Treatment of Status Migrainosus



Medication	Dose	Issues/comments
Sumatriptan + Naproxen Sodium	100 mg oral 500-550 mg oral	Combo synergistic
Metoclopramide + Benadryl + Ibuprofen	10 mg oral tablet 25 mg OTC 600 mg OTC	For triptan or DHE intolerant patients. RCTs not available for combination therapies, sedating
DHE + prochlorperazine	0.5 mg each nostril, max 4 mg/d 10 mg oral or 25 mg rectal	Avoid with vascular disease
Prednisone	60 mg oral x 1d and rapid taper	Use rarely, warn of avascular necrosis
Dexamethasone	4-8 mg oral x 1d and rapid taper	Use rarely, warn of avascular necrosis



# In-office Rescue Therapies: Initial Steps

- ▶ **Step 1:** Start an IV and hydrate
- ▶ **Step 2:** Provide a dopamine receptor antagonist, IM or IV (risks of akathisia, dystonia, and hypotension):
  - metoclopramide 10 mg IV
  - promethazine 12.5-25 mg IM or IV
  - prochlorperazine 10 mg IV
- ▶ **Step 3:** Consider a repeat trial of DHE or triptan unless cardiac risks or max dose already received
  - Sumatriptan 6 mg SQ or 20 mg intranasal
  - Dihydroergotamine 0.5-1 mg IV

# In-office Rescue treatments: Step 4

Abortive Agent	Dosing and route	Risks/comments
Magnesium Sulfate	500-1000 mg IV	Hypotension
Ketorolac	30-60 mg IM or IV	Gastritis
Sodium Valproate	400-1200 mg IV	Risk of acute hyperammonemia if on TPX
Methylprednisolone	100-200 mg IV	Risk of avascular necrosis, data mixed
Dexamethasone	4-16 mg IV	Risk of avascular necrosis, evidence in HA >72 hours



# Case presentation

- ▶ 32 yo F with migraine since 16 yo, frequency 2-4x/month until 1 year ago with now nearly 25 days of headache a month, 15 of which are severe. She describes headaches often awakening her in the morning with her typical migraine features (unilateral, nausea, photophobia) and other days having more mild diffuse headache with allodynia. She has used abortive combination of butalbital, aspirin, caffeine for 7 years and currently uses 4-6 pills on bad days and 2 pills on good days with intermittent use of ibuprofen 600 mg. She is inconsistently taking propranolol 20 mg bid. Her neurologic and general exam including fundi are entirely normal.



# What factors have increased the frequency of her headache?

1. Type of Abortive compound used

■ 2%

2. Frequency of use of abortive

■ 15%


3. Pre-existing headache type

0%

4. All of the above

■ 84%





Answer?  
All of the above

# Diagnosis: Medication Overuse Headache (MOH)

- ▶ Headache > 15 days a month
- ▶ Regular overuse of abortive treatments for > 3 months
- ▶ Pattern has worsened during medication overuse
- ▶ Headache improves within 2 months of removing overuse
- ▶ Preventives **FAIL** to reduce headaches



# Risk Factors for MOH

- ▶ Frequency or DAYS/week of abortive use is greater provocative than dose or quantity of abortive use
- ▶ Migraine type and chronic migraine type HA
- ▶ Female predominance 3:1
- ▶ Opioid use alone increases risk by 44% for transformation to a chronic headache syndrome
- ▶ Butalbital compounds increase risk 70%

# MOH Approach and Treatment

- ▶ Withdraw Abortive (wean barbiturates and opioids, stop triptans, NSAIDS, DHE, OTCs abruptly)
- ▶ Treat Withdrawal Headache (steroid taper)
- ▶ Amplify Preventive (use evidence base migraine preventives)
- ▶ Re-Introduce selective, infrequent ( $\leq 2$ x/week) and appropriate abortive
- ▶ Encourage complimentary therapies and overall reduction in triggers



# MOH Education for Patients

- ▶ Help patients understand that frequent abortive use upregulates the headache cycle
- ▶ Create realistic expectations of initial worsening of headache and weeks to months before headache severity and frequency decreases
- ▶ Consider providing objective handouts about the problem of opioids or butalbital use in migraine population to patient (see resources)
- ▶ Emphasize prevention with pharmacologic and lifestyle factors offers best long-term outcome



# Step 1: Wean or withdraw abortives

- ▶ Ergots, triptans, NSAIDs, & OTCs can be stopped **ABRUPTLY** without wean, & avoid re-introduction for 10-14 days
- ▶ Opioids and barbiturate cessation can cause serious withdrawal syndromes.
- ▶ Long acting derivatives can be substituted (phenobarbital for butalbital, morphine SR for hydrocodone) with 4-8 week slow taper to minimize withdrawal risks.



# Step 2: Treat Withdrawal Headache

- ▶ Only a subset of patients desire treatment with substitute for the overused abortive
- ▶ Outpatient treatment is preferred:
  - Prednisone 60 mg oral x 1 d and 7d taper
  - Decadron 8 mg oral x 1 d and 5d taper
- ▶ In rare circumstances inpatient detoxification with “terminators” of IV DHE plus Reglan for 72-96 hours have been used, but this is costly strategy without clear superiority to outpatient regimens and may promote “sick role”

# Step 3: Amplify Preventives.

- ▶ Topirimate (Level A)
- ▶ Propranolol, Metoprolol, and Timolol (Level A)
- ▶ Divalproex and Valproic Acid (Level A)
- ▶ Amitriptyline and Venlafaxine (Level B)
- ▶ Botulinum A Toxin should be reserved for patients meeting chronic migraine criteria and failing >2-3 well preventive trials



# Nutraceuticals and Complimentary Preventives

- ▶ Butterbur (petasites) dose 150 mg/day is established as effective preventive. (Level A) Caution around risk of hepatic toxicity
- ▶ Riboflavin (400 mg/day), magnesium (400 mg/day), and MIG-99 (50-100 mg/day (feverfew) are probably effective for prevention (Level B)
- ▶ Biobehavioral treatments (Biofeedback, CBT, or Relaxation training) are probably effective Level B
- ▶ Acupuncture may be effective
- ▶ Chiropractic may be effective



# Step 4: Prevent MOH recurrence

- ▶ Reintroduce appropriate abortive with controlled use of frequency. General rule: **NO MORE than 2 days/week of abortive use**
- ▶ Opioids and butalbital have no role in primary headache treatment, do **NOT** reintroduce
- ▶ Encourage headache patients to explore lifestyle management with trigger avoidance, sleep hygiene, daily morning exercise, and treatment of underlying mood disorders



# Take Away Points

- ▶ Migraine criteria present and no red flags = No imaging is warranted
- ▶ Autonomic features with brief, severe, unilateral headache is likely a trigeminal autonomic cephalgia
- ▶ Refractory Migraine may respond to home combination therapies
- ▶ Consider Medication Overuse Headache as a cause of frequent headaches
- ▶ Minimize patient use of abortives & amplify preventives and lifestyle factors for best long-term outcomes



# References

1. IHS Classification ICHD-II, [www.ihs-classification.org](http://www.ihs-classification.org)
2. Chaudry P, Friedman D. Neuroimaging in Secondary Headache Disorders. Curr Pain Headache Rep. 2015 Jul;19(7):30. doi: 10.1007/s11916-015-0507-y.
3. Headache Classification Committee of the International Headache Society (IHS). The International Classification of Headache Disorders, 3<sup>rd</sup> edition. Cephalia 2013;33 (9):665-671.
4. Evans RW. Diagnostic testing for the evaluation of headaches. Neurol Clin. 1996;14;1-26.
5. Goadsby PJ, Lipton RB. A review of paroxysmal hemicranias, SUNCt syndrome and other short lasting headache with autonomic features, including new cases. Brain 1997;120:193-209.
6. Cittadini E, Matharu MS. Symptomatic trigeminal autonomic cephalgias. Neurologist 2009;15 (6):305-312.
7. Francis GJ, Becker WJ, Pringsheim TM.. Acute and preventive pharmacologic treatment of cluster headache. Neurology 2010;75(5);463-473.



# References

8. Newman LC, Lipton RB, Solomon S. Hemicrania continua: ten new cases and a review of the literature. *Neurology* 1994;44 (11):2111-2114.doi:10.1212/WNL.44.11.2111.
9. Cittadini E, Goadsby PJ. Hemicrania continua; a clinical study of 39 patients with diagnostic implications. *Brain* 2010; 133 (pt 7):1973-1986.doi:10.1093/brain/awq137.
10. Brandes JL, Kudrow D, Stark SR, et al. Sumatriptan-naproxen for acute treatment of migraine: a randomized trial.*JAMA* 2007;297 (13)1443-1445.doi:0.1001/jama.297.12.1443
11. Rabbie R, Derry S, Moore RA. Ibuprofen with or without an antiemetic for acute migraine headaches in adults. *Cochrane Database Syst Rev* 2013;4::CD008039.doi:10.1002/14651858.CD008039.pub3
- 12.Primary care management of headache in adults. Toward Optimized Practice website.[www.topalbertadoctors.org/cpgs/10065](http://www.topalbertadoctors.org/cpgs/10065). Published July 2012
13. Thorlund K, Mills EJ, WU P et al. Comparative efficacy of triptans for abortive treatment of migraine:a multiple treatment comparison meta-analysys. *Cephalgalgia* 2014;34 (4):258-267.doi:10.1177/0333102413508661
14. Cete Y, Dora B, Ertan C, et al. A randomized prospective placebo-controlled study of intravenous magnesium sulphate vs metoclopramide in management of acute migraine attacks in the emergency department. *Cephalalgia* 2005;25(3):199-204.doi:10.1111/j.1468-2982.2004.00840.x.



# References

15. Friedman BW, Mulvery L, Esses D, et al. Metoclopramide for acute migraine; a dose finding randomized clinical trial. *Ann Emerg Med* 2011; 57 (5):475-482.e1.doi:10.1177/0333102414535997
16. Friedman BW, Greenwald P, Bania TC et al Randomized trial of IV dexamethasone for acute migraine in the emergency department. *Neurology*.2007;69(22):2038-2044..doi:10.1212/01.WNL.0000281105.78953.1d
17. Rothrock JF. Successful treatment of persistent migraine aura with divalproex sodium. *Neurology* 1997;48(1): 261-622. doi:10.1212/WNL.48.1.261
18. Kristoffersen ES, Lundquist C. Medication-overuse headache: epidemiology, diagnosis and treatment. *Ther Adv Drug Saf* 2014;5(2):87-99.doi:10.1177/2042098614522683.
29. Lipton Rb. Chronic migraine, classification, differential diagnosis and epidemiology. *Headache* 2011;51 (suppl 2):77-83.doi:10.1111/j.1526-4610.2011.01954.x.
20. Olesen J. Detoxification for medication overuse headache is the primary task. *Cephalgia* 2012;32 (5):420-422.doi:10.1177/0333102411431309.
21. Holland S, Silberstein SD, Freitag F, et al. Evidence-based guideline update: NSAIDs and other complementary treatments for episodic migraine prevention in adults: report of the Quality Standards subcommittee of the American Academy of Neurology and the American Headache Society. *Neurology* 2012;78(17):1346-1353.doi:10.1212/WNL.0b013e3182535d0c.



# Triptans: Dose and Half Life

## table 1-1

Triptan Generic Name	Dose	Half Life
Almotriptan tablet	12.5 mg, max 25 mg/d	3-4h
Eletriptan tablet	40 mg, max 80 mg/d	4 h
Frovatriptan tablet	2.5 mg, max 5 mg/d	26h
Naratriptan tablet	2.5 mg, max 5 mg/d	6 h
Rizatriptan tablet	10 mg, max 20 mg/d	2-3 h
Rizatriptan wafer	10 mg, max 20 mg/d	2-3 h
Sumatriptan tab	50-100mg,max 200 mg/d	2.5 h
Sumatriptan intranasal	20 mg, max 40 mg/day	2.5 h
Sumatriptan injection	4-6 mg, max 12 mg/day	2.5 h
Zolmitriptan tablets	2.5 mg, max 10 mg/d	3h
Zolmitriptan wafer	2.5 mg, max 10 mg/d	3h

# Provider Resources

The American Headache Society's Headache journal toolbox:

[http://www.americanheadachesociety.org/professional\\_resources/headache\\_journal\\_toolboxes/](http://www.americanheadachesociety.org/professional_resources/headache_journal_toolboxes/)

International Headache Society, IHS classification ICHD-II

<http://ihs-classiciation.org>

The American Academy of Neurology, Headache Guidelines

<https://www.aan.com/Guidelines/Home/ByTopic?topicId=16>



# Avoid Opioids; an abstract for all

Tepper, S. J. (2012), Opioids Should Not Be Used in Migraine. Headache: The Journal of Head and Face Pain, 52: 30–34. doi: 10.1111/j.1526-4610.2012.02140.x

Opioids should not be used for the treatment of migraine. This brief review explores why not. Alternative acute and preventive agents should always be explored.

Opioids do not work well clinically in migraine. No randomized controlled study shows pain-free results with opioids in the treatment of migraine. Saper and colleagues' 5-year study showed minimal effectiveness, with many contract violations, interfering with the therapeutic alliance.

The physiologic consequences of opioid use are adverse, occur quickly, and can be permanent. Decreased gray matter, release of calcitonin gene-related peptide, dynorphin, and pro-inflammatory peptides, and activation of excitatory glutamate receptors are all associated with opioid exposure. Opioids are pro-nociceptive, prevent reversal of migraine central sensitization, and interfere with triptan effectiveness.

Opioids precipitate bad clinical outcomes, especially transformation to daily headache. They cause disease progression, comorbidity, and excessive health care consumption. Use of opioids in migraine is pennywise and pound foolish.



# Triptans: Consensus Statement regarding cardiovascular disease

- ▶ Consensus Statement: Triptans are associated with a modestly elevated incidence of chest symptoms (ie, triptan sensations) relative to placebo in well-controlled clinical trials that excluded patients with significant cardiac risk factors or known ischemic heart disease. The chest symptoms in clinical trials were generally transient, mild, and nonserious. Class II evidence, Level A conclusion.
- ▶ Consensus Statement: Among patients without known or suspected coronary artery disease, the safety profile of triptans is well defined and appears to reflect a very low risk of serious cardiovascular adverse events.
- ▶ Nonetheless triptans are contraindicated in patients with KNOWN CAD and it is recommended to AVOID triptans in patients with > 2 modifiable Cardiac Risk Factors

Dodick, D., Lipton, R. B., Martin, V., Papademetriou, V., Rosamond, W., MaassenVanDenBrink, A., Loutfi, H., Welch, K. Michael., Goadsby, P. J., Hahn, S., Hutchinson, S., Matchar, D., Silberstein, S., Smith, T. R., Purdy, R. A., Saiers, J. and The Triptan Cardiovascular Safety Expert Panel (2004), Consensus Statement: Cardiovascular Safety Profile of Triptans (5-HT<sub>1B/1D</sub> Agonists) in the Acute Treatment of Migraine. Headache: The Journal of Head and Face Pain, 44: 414–425. doi: 10.1111/j.1526-4610.2004.04078.x



# Patient Resources

The American Headache Society's Patient Education Page

<http://www.headachejournal.org/view/0/toolboxes.html>

For Patient Friendly **Handouts** and other resources:

American Council For Headache Education

[www.achenet.org](http://www.achenet.org)

National Headache Foundation

[www.headaches.org](http://www.headaches.org)

American Headache Society

[www.ahsnet.org](http://www.ahsnet.org)

National Center for Complementary and Alternative Medicine. NCCAM  
Clearinghouse

<http://nccam.nih.gov>