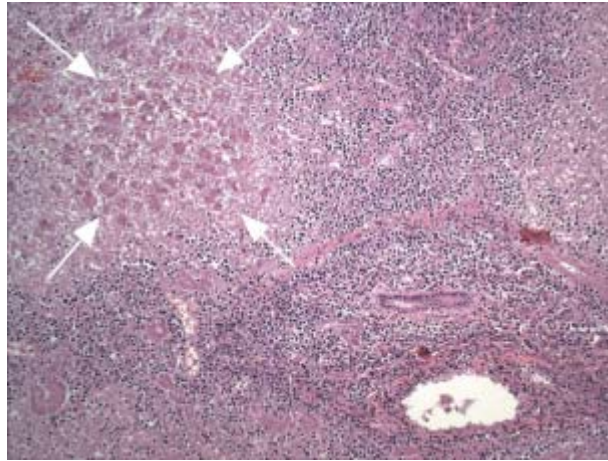


Figure 3. Autopsy findings for patient 3.



The figure shows total lobular necrosis, with pink hepatocytes lacking nuclei (*area within arrows*). Portal triads are densely infiltrated by lymphoid cells. (Hematoxylin--eosin; original magnification, $\times 10$).