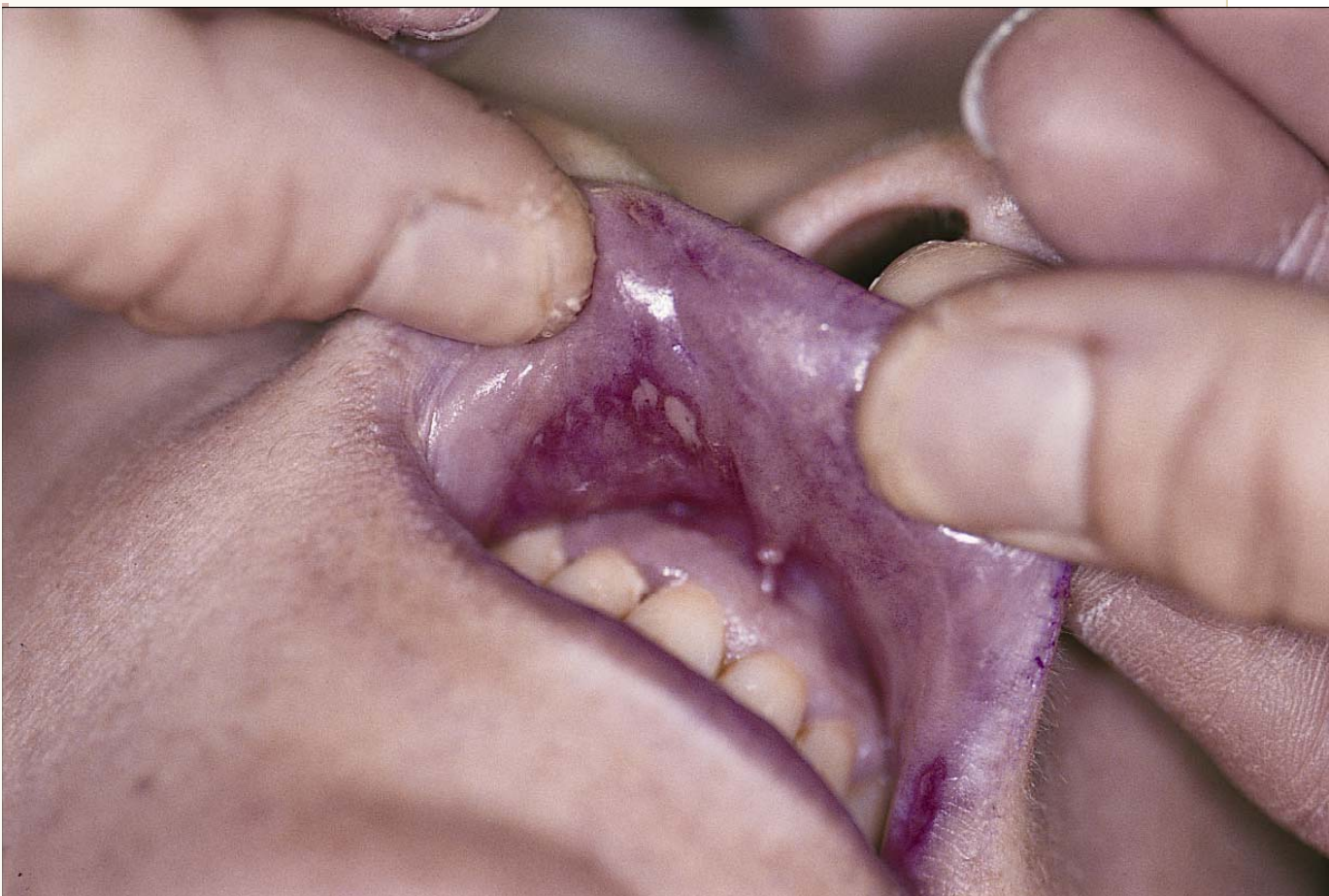




Aphthous Ulcers



An aphthous ulcer is characterized by a painful, small shallow ulcer with a white base and yellow border and is surrounded by a red areola. It can occur on the buccal and labial mucosa and the floor of the mouth.