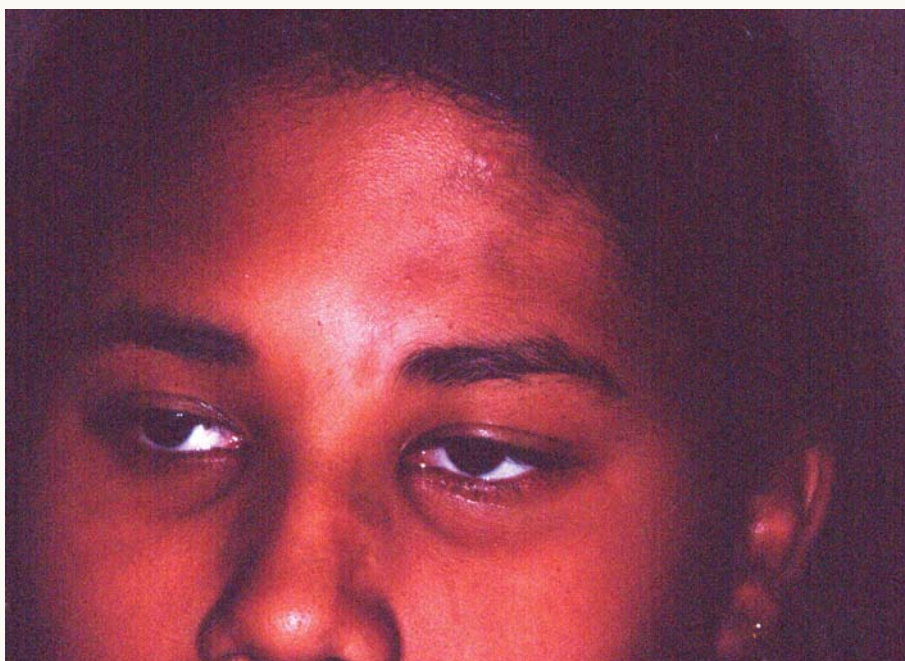




Discoid Lupus



This patient has discoid lupus involving the forehead and extending down to the nose. It is polygonal in shape and there is evidence of cutaneous atrophy in the middle forehead, erythema, and hyperpigmentation and follicular plugging near the hairline