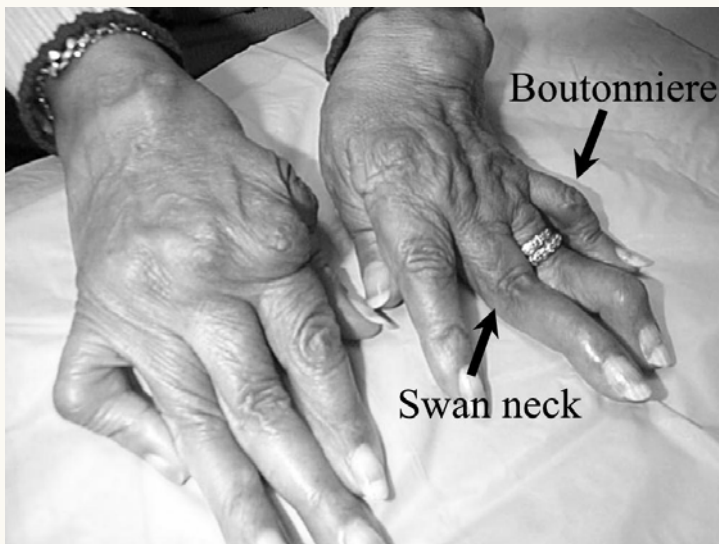




Hand Deformities



Characteristically found in rheumatoid arthritis, swan neck and boutonnière deformities are caused by synovitis destroying the tendon attachments around the joints. The boutonnière deformity is flexion of the proximal interphalangeal joint with concomitant hyperextension of the distal joint. Swan neck deformity is caused by hyperextension of the proximal interphalangeal joint and flexion of the distal joint.