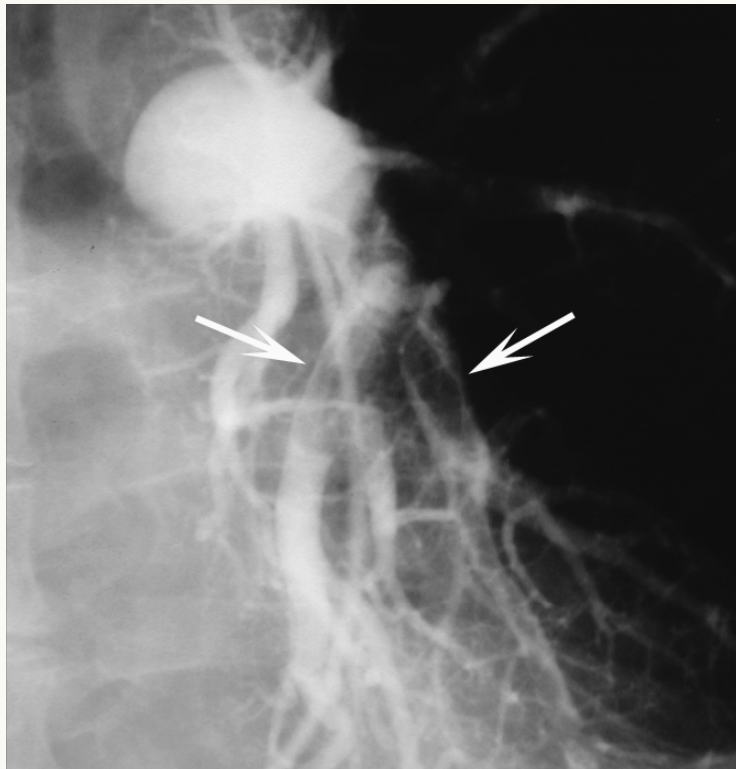




Pulmonary Angiogram



Left pulmonary artery angiogram in a patient with acute pulmonary embolism shows an intravascular filling defect with "trailing edges" of contrast (arrows), diagnostic of acute pulmonary embolism.