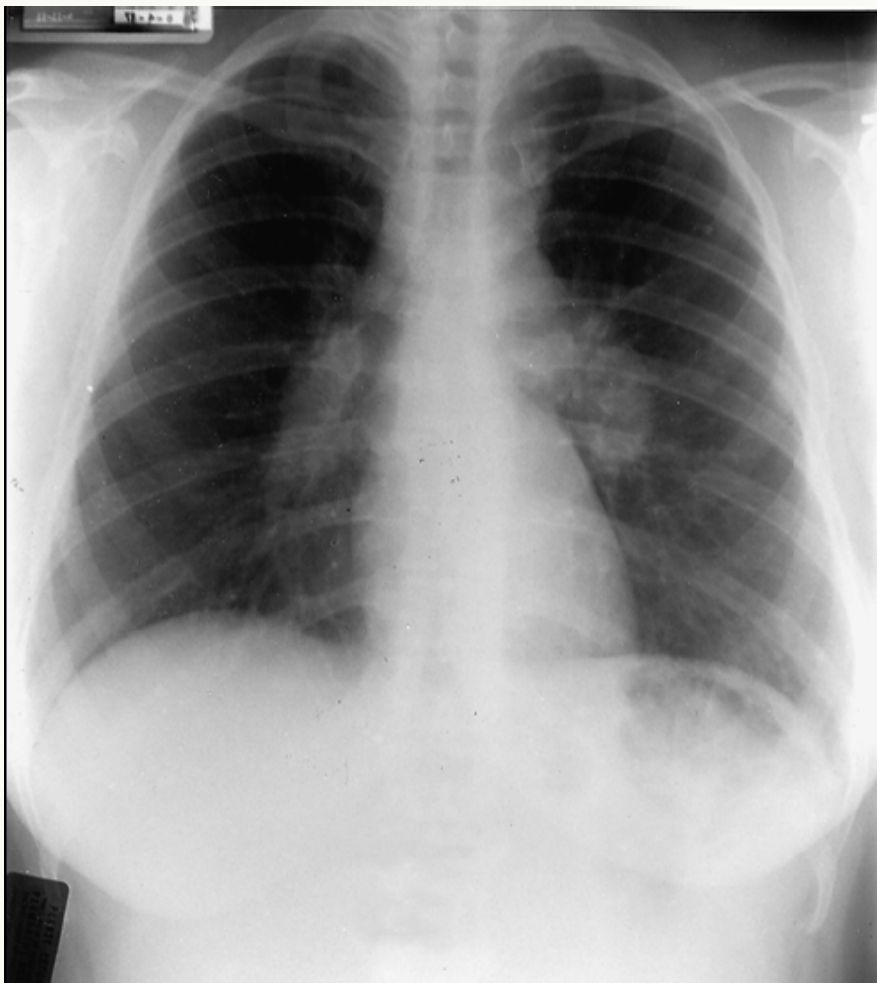




## Hilar Lymphadenopathy



This radiograph shows bilateral hilar lymphadenopathy characteristic of sarcoidosis. Sarcoidosis can be associated with interstitial lung disease.