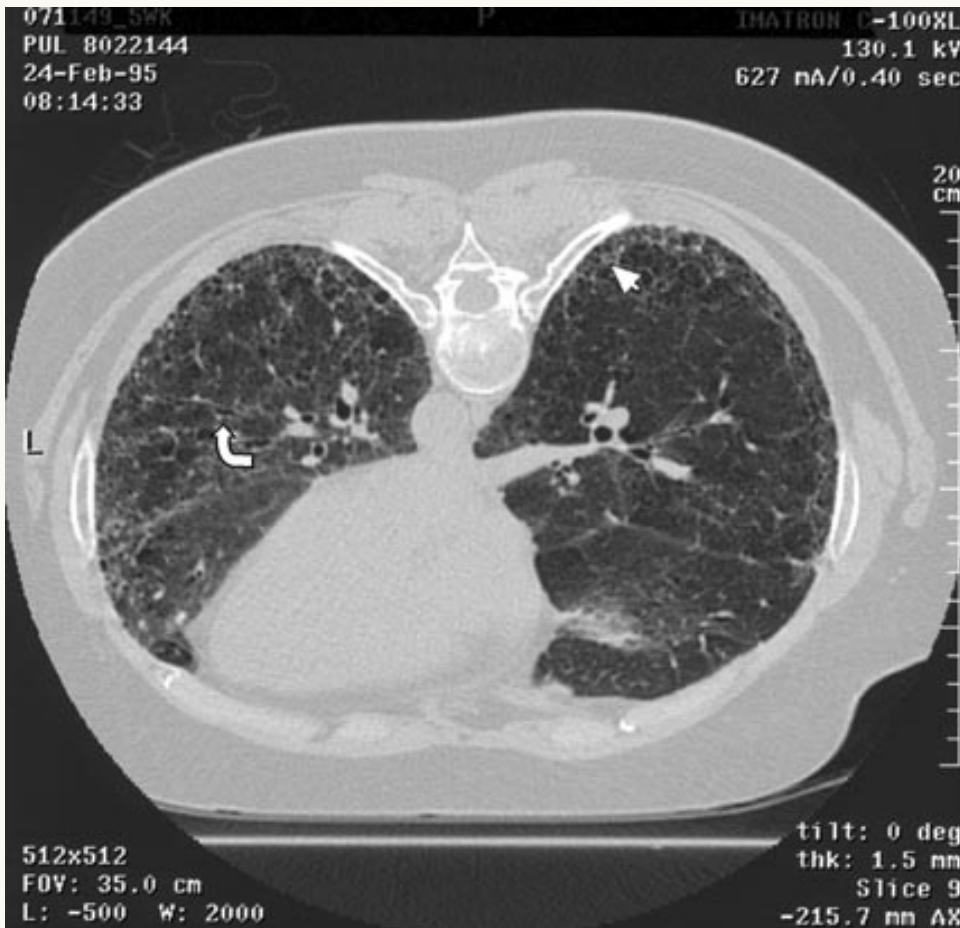




Pulmonary Fibrosis



High resolution CT scan of the chest showing lower lobe predominant interstitial infiltrates with increased septal markings, subpleural honeycomb change (arrow head) with traction bronchiectasis (curved arrow). Open lung biopsy confirmed idiopathic pulmonary fibrosis.