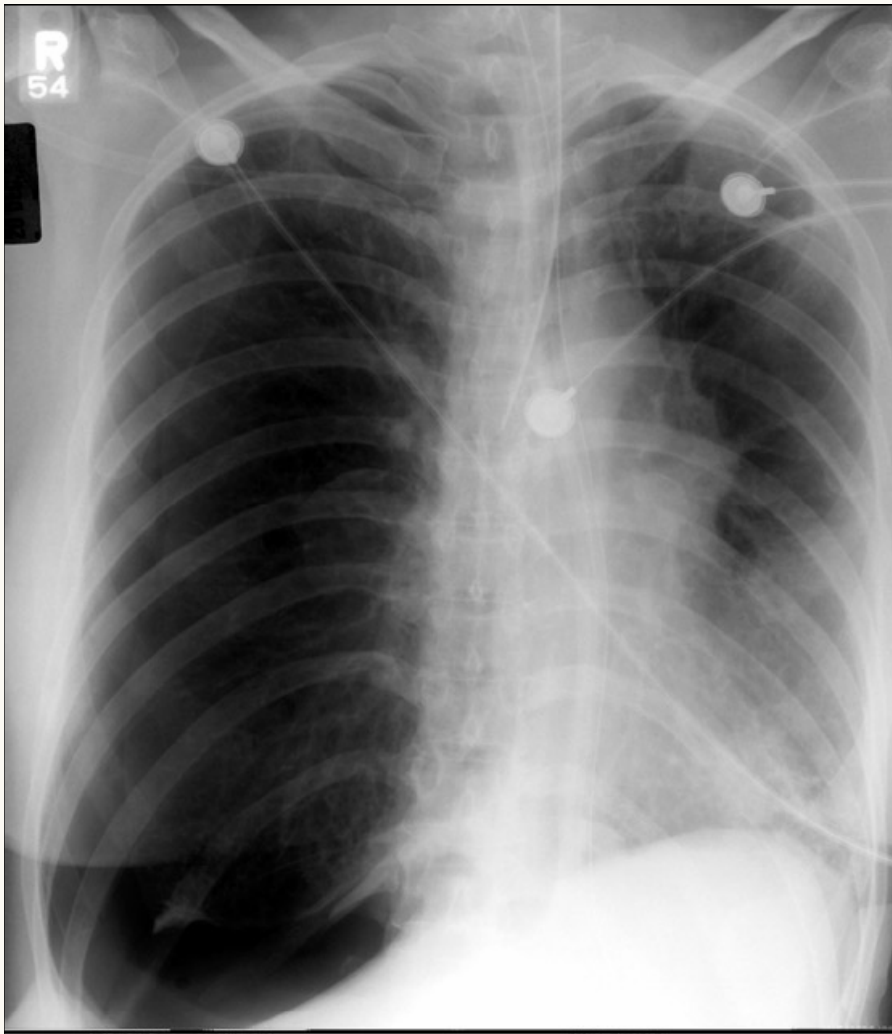




Tension Pneumothorax



Chest x-ray showing large right tension pneumothorax pushing the mediastinal structures to the left.