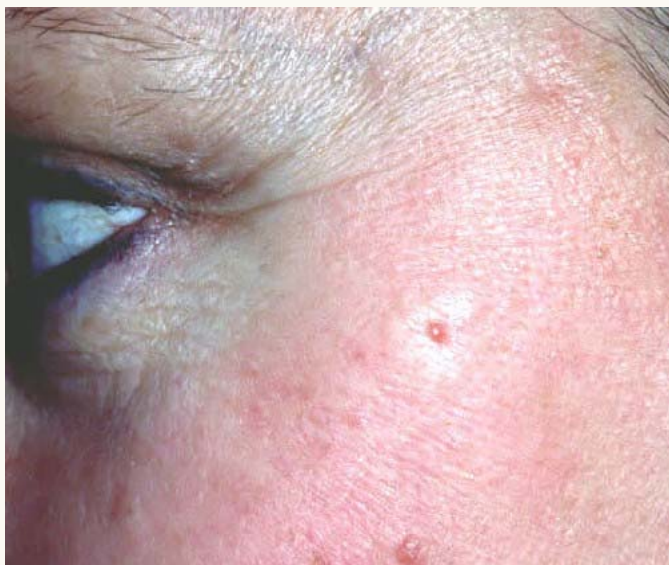




Morpheaform basal cell carcinoma



Morpheaform basal cell carcinoma characteristically presents as a smooth, flesh-colored, or sometimes a very lightly erythematous papule or plaque that is frequently atrophic with a firm or indurated quality and ill-defined borders.