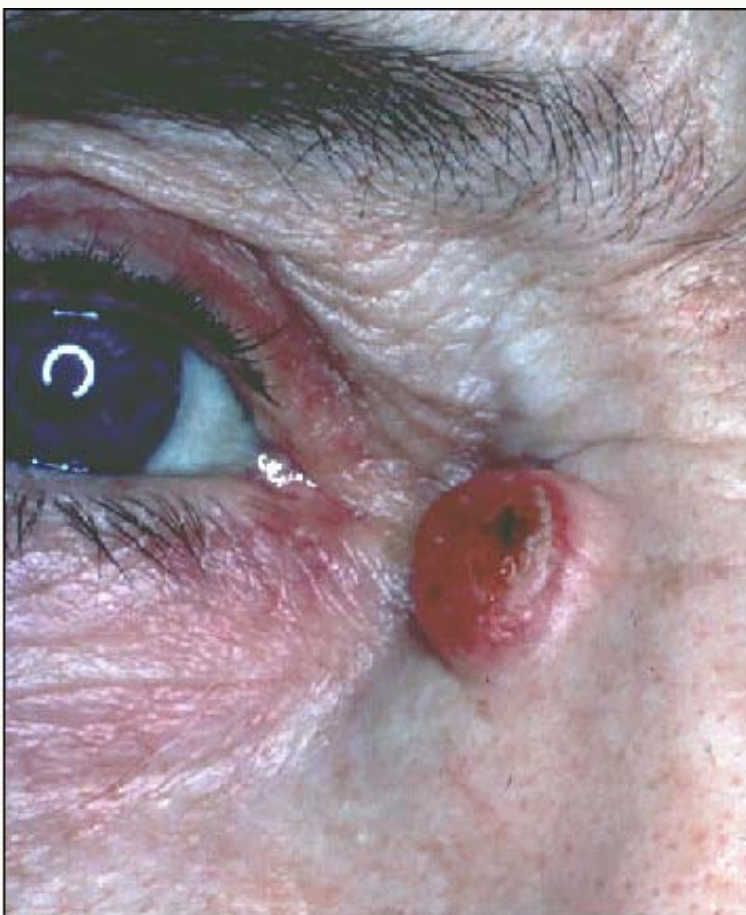




Nodular Basal Cell Carcinoma



Nodular basal cell carcinoma is most commonly recognized as a firm pearly papule with telangiectasias. It may also have rolled borders with a central depression or ulcer. Spontaneous bleeding may occur.