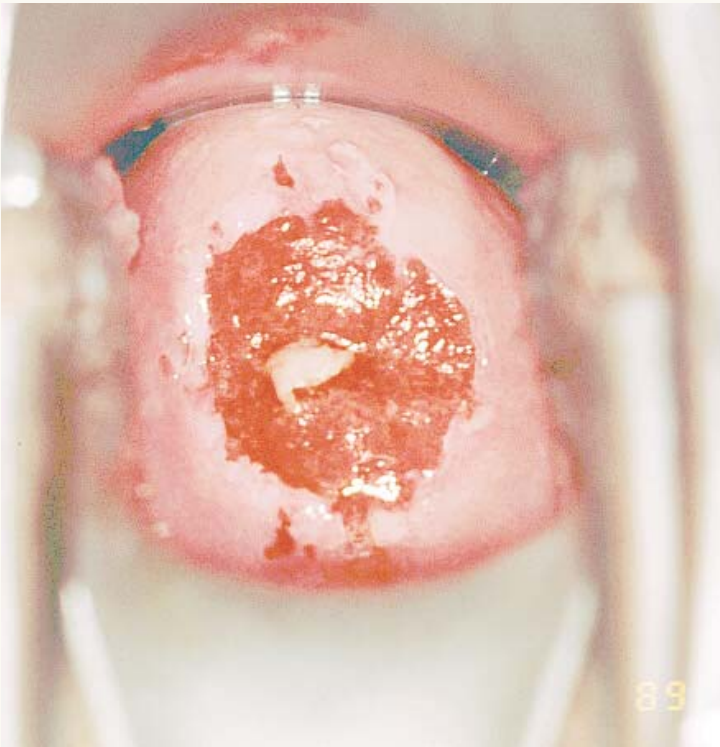




## Cervical Ectopy



Cervical ectopy is defined as the presence of columnar epithelium on the ectocervix and is a normal variant. In this image the squamocolumnar junction is obvious at the color change from pink to beefy red.

Reproduced with permission from: JHPIEGO. 1999. *Atlas of Visual Inspection of the Cervix with Acetic Acid (VIA)*. JHPIEGO: Baltimore, MD. Copyright © by JHPIEGO, an affiliate of The Johns Hopkins University. All rights reserved. Slides contributed by Paul Blumenthal, EngenderHealth/Thomas Wright, and Francisco Garcia.