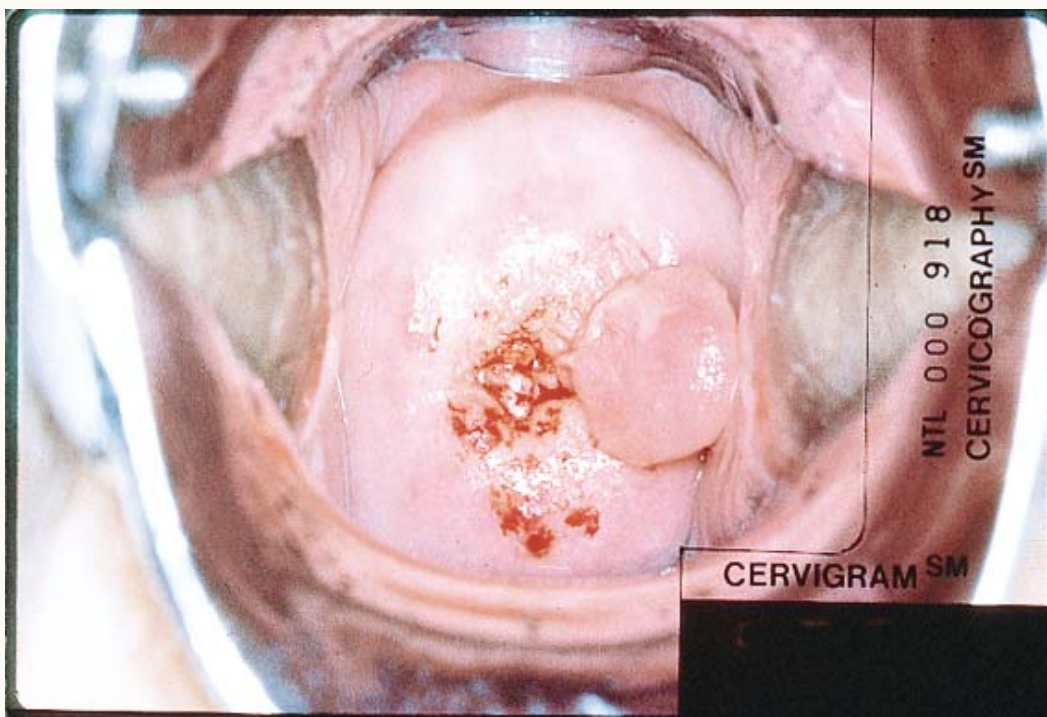




Cervical Polyp



A cervical polyp appears as a finger-like projection in the cervical os. Polyps may emanate from cervical or endometrial tissue and cause menorrhagia and post-coital bleeding. Almost always benign, they are typically removed and sent for pathological evaluation.

Reproduced with permission from: JHPIEGO. 1999. *Atlas of Visual Inspection of the Cervix with Acetic Acid (VIA)*. JHPIEGO: Baltimore, MD. Copyright © by JHPIEGO, an affiliate of The Johns Hopkins University. All rights reserved. Slides contributed by Paul Blumenthal, EngenderHealth/Thomas Wright, and Francisco Garcia.