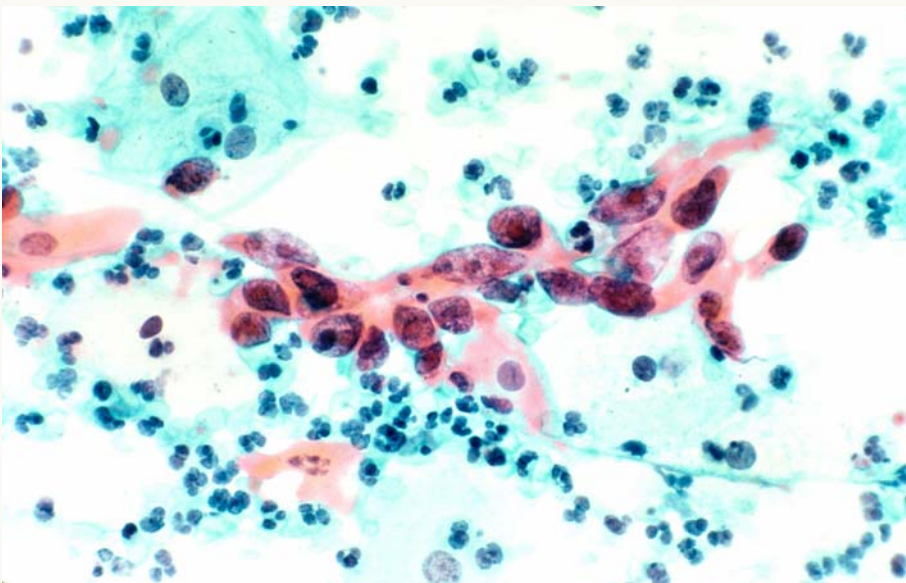




## Cervical Cancer



Histological section showing squamous cell carcinoma in the cervix. Tissue is stained with pap stain and magnified x200.

Image is from the National Cancer Institute.