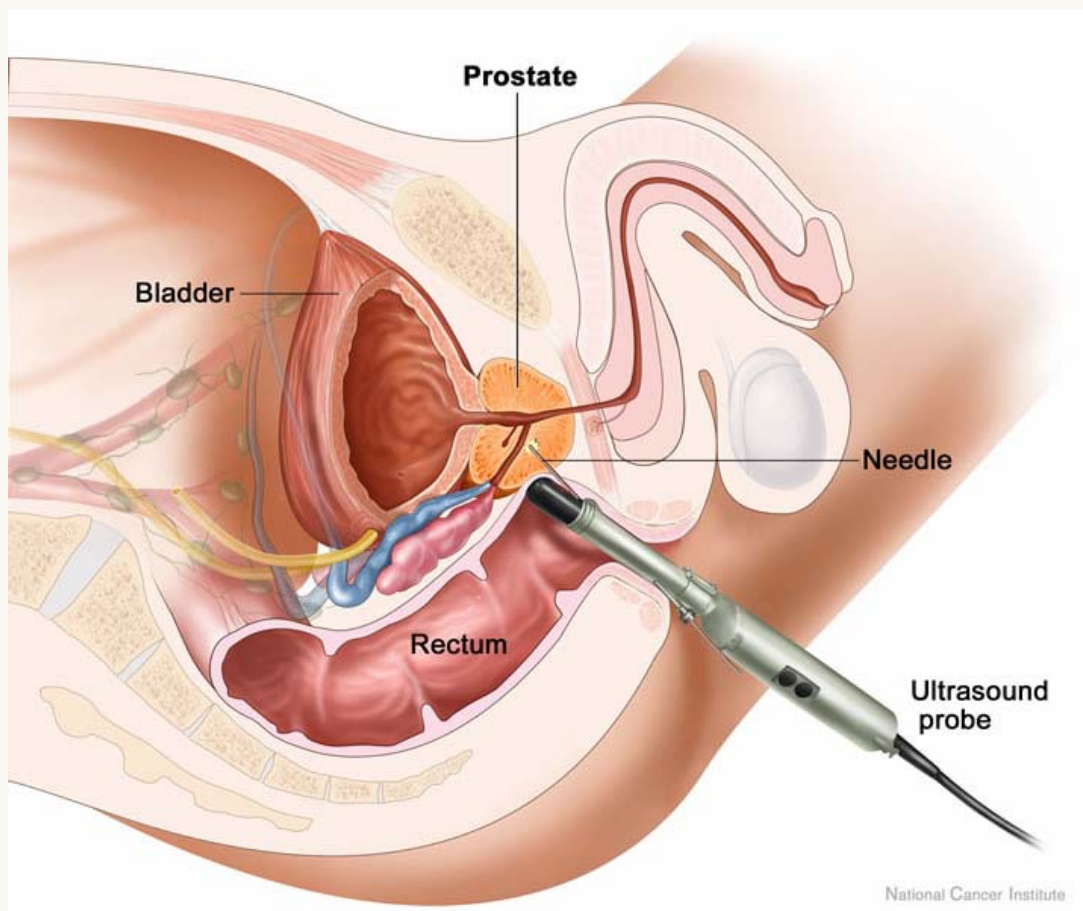




Transrectal Biopsy



This illustration from the National Cancer Institute shows a side view of prostate, bladder, and rectum and an ultrasound probe with a needle inserted into the rectum to remove a tissue sample from the prostate.