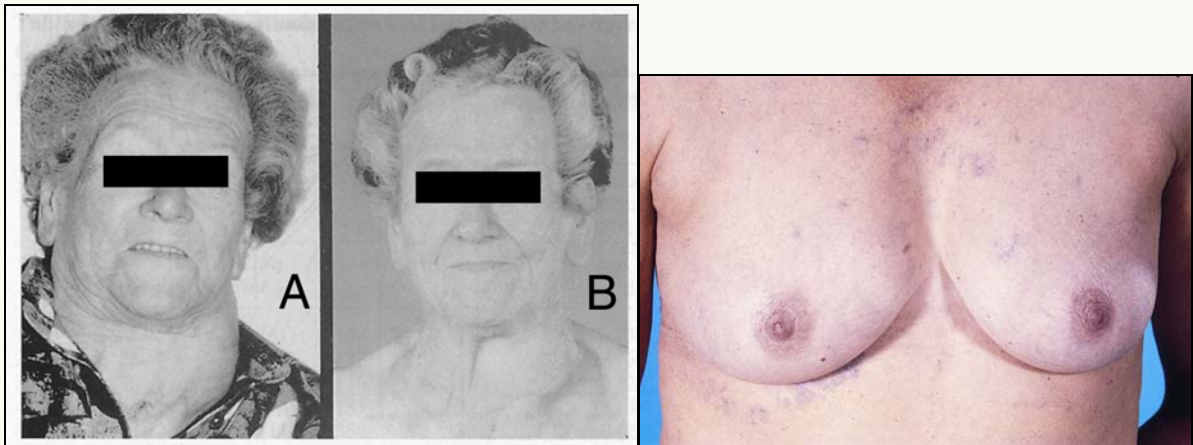




Superior Vena Cava Syndrome



Panel A shows the face of the patient prior to the onset of the superior vena cava syndrome (SVCS). Panel B shows development of facial and neck edema and venous distention following the onset of the SVCS. Panel C shows venous engorgement and edema of the chest as a result of the SVCS.