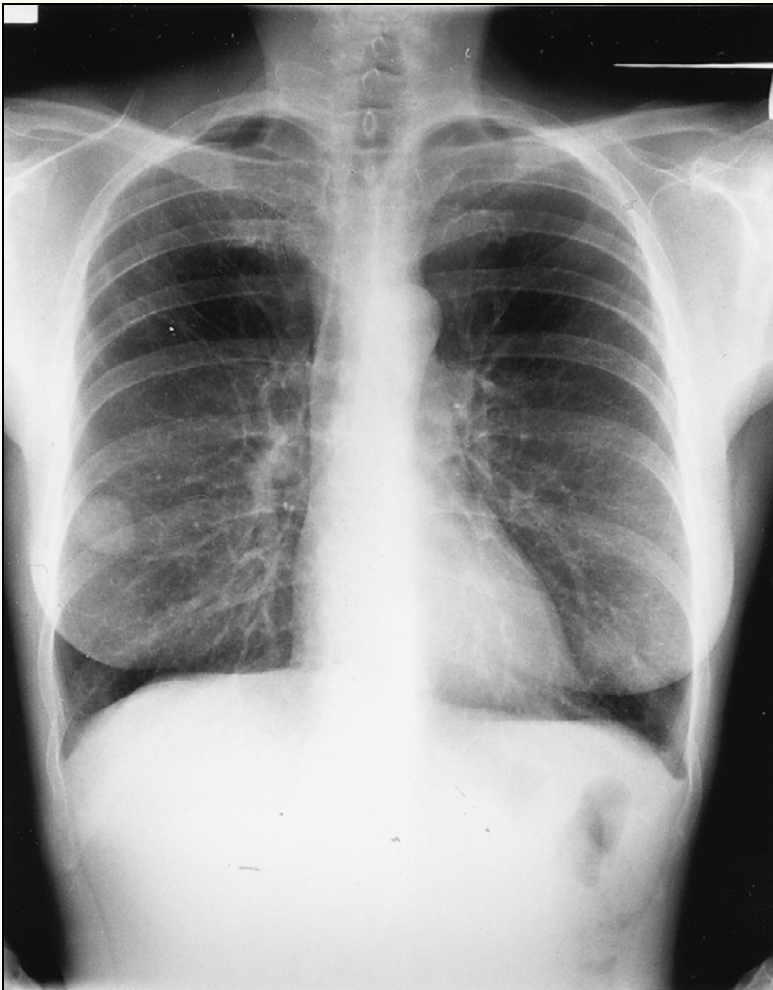




## Pulmonary Nodule



A 3-cm, smooth and sharply circumscribed nodule is present at the base of the right lung.