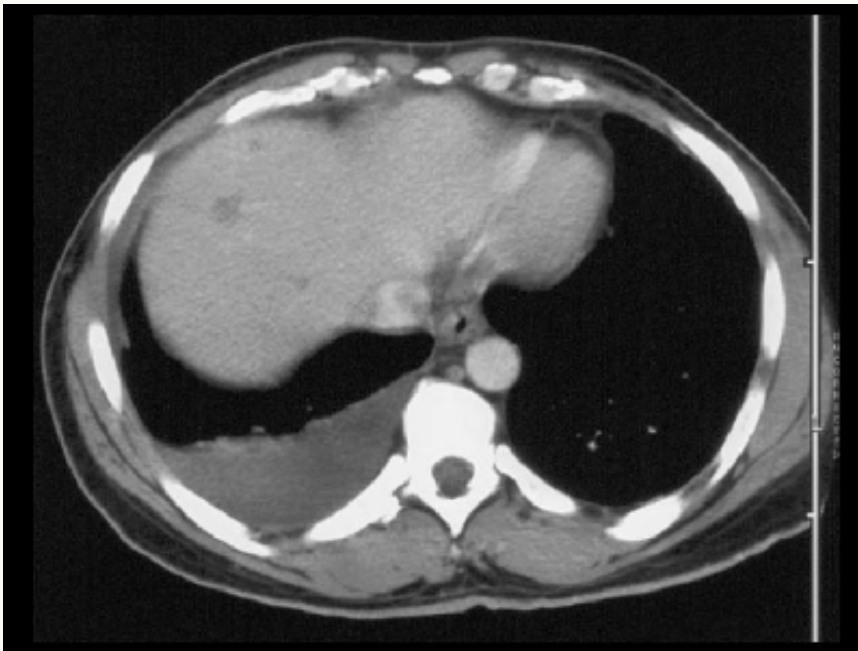




## Liver Metastases



CT of the upper abdomen shows multiple hypodense liver lesions in a patient with histologically proven small cell lung cancer. A right pleural effusion is also seen.