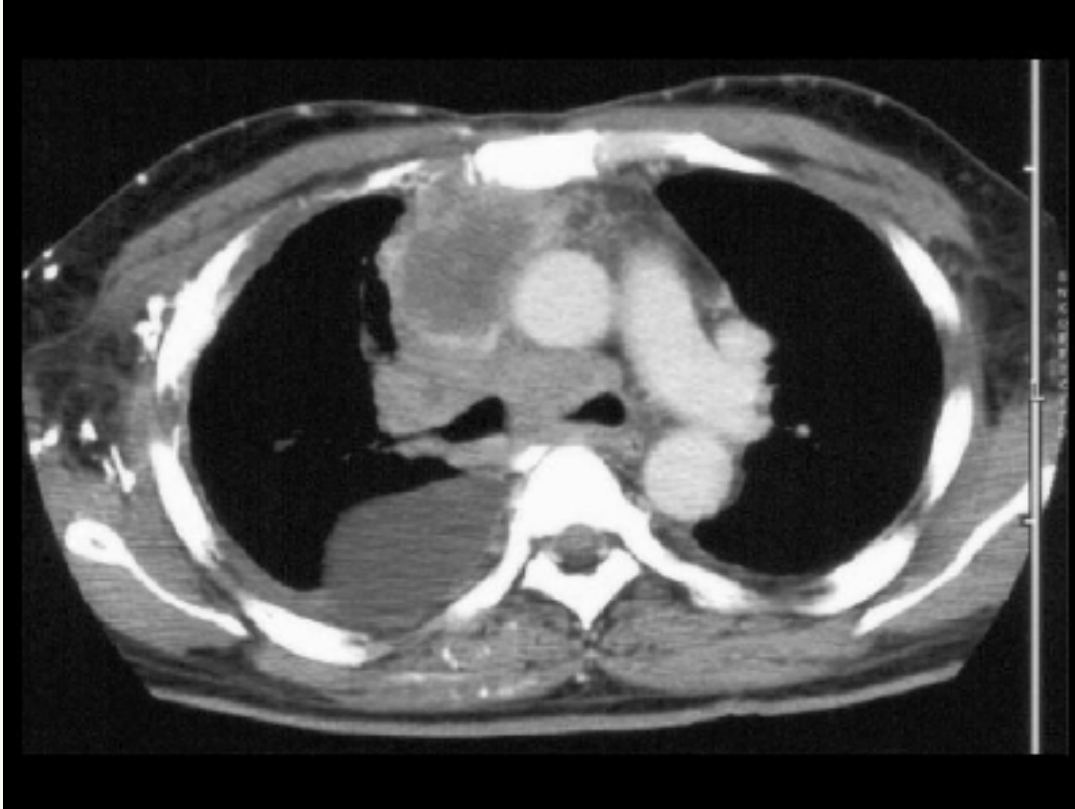




Locally Advanced Cancer



CT Scan of Chest Showing Locally Advanced Lung Cancer : CT scan of the chest shows a large right hilar mass and mediastinal lymphadenopathy that result in occlusion of the superior vena cava. The patient presented with superior vena cava syndrome.