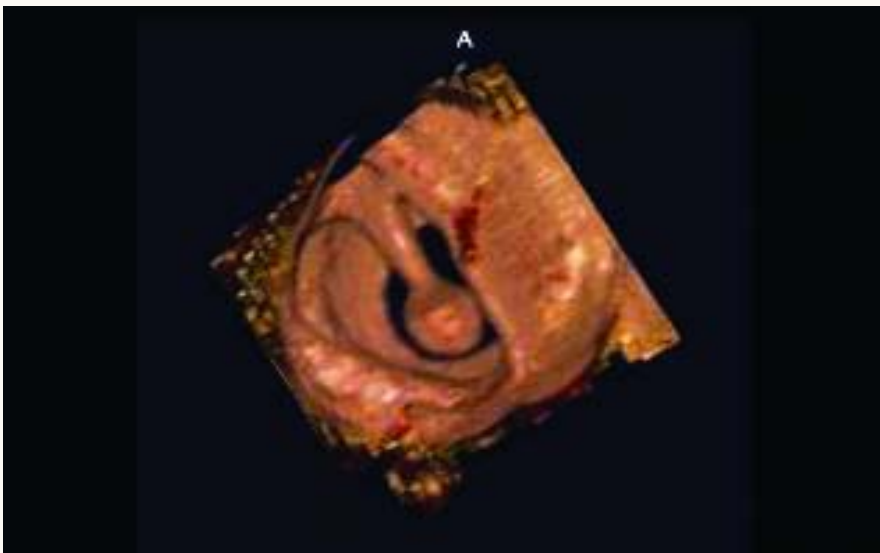




Virtual Colonoscopy



Colonic polyp on a stalk as visualized with virtual colonoscopy.

Contributed by Dr. Eric Paulson, Department of Radiology, Duke University Medical Center.