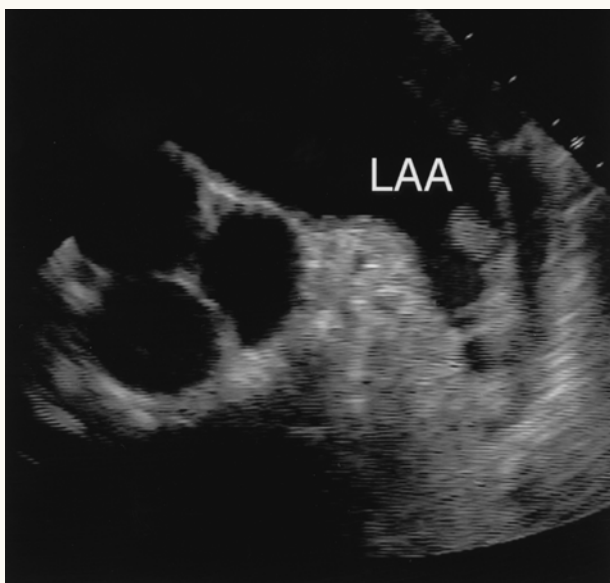




Left Atrial Thrombus



Echocardiogram showing left atrial thrombus that developed as a consequence of atrial fibrillation. This thrombus has the potential to break free and enter the systemic circulation and obstruct arteries. In the brain, this could lead to stroke.