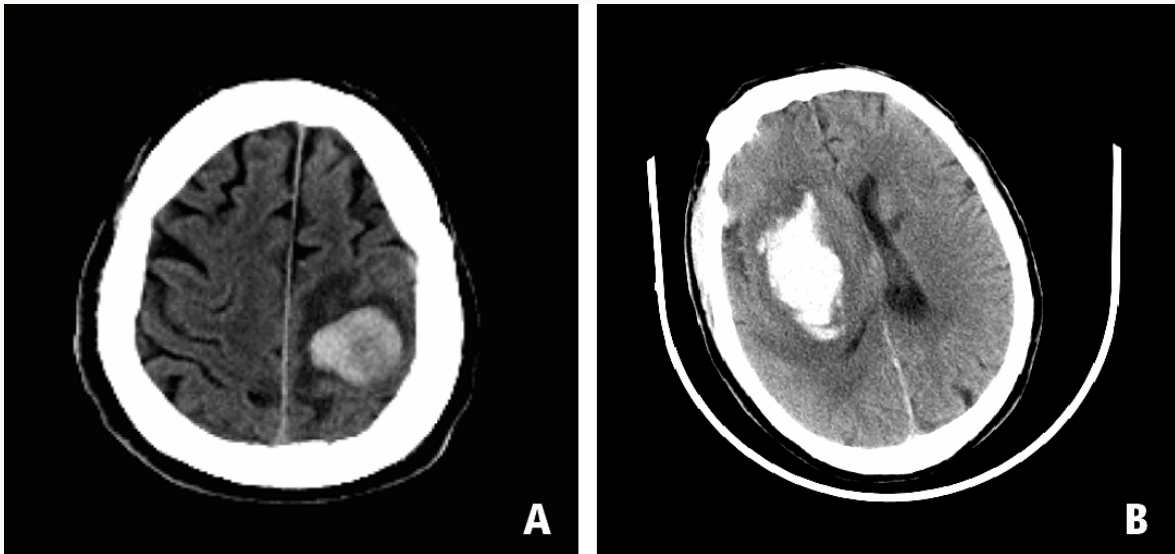




Hemorrhage Stroke



The left panel shows a patient with left lobar (frontal-parietal) intracerebral hemorrhage, such as is commonly associated with cerebral amyloid angiopathy. The right panel shows right deep (basal ganglionic) intracerebral hemorrhage, a common location of hypertensive hemorrhages.