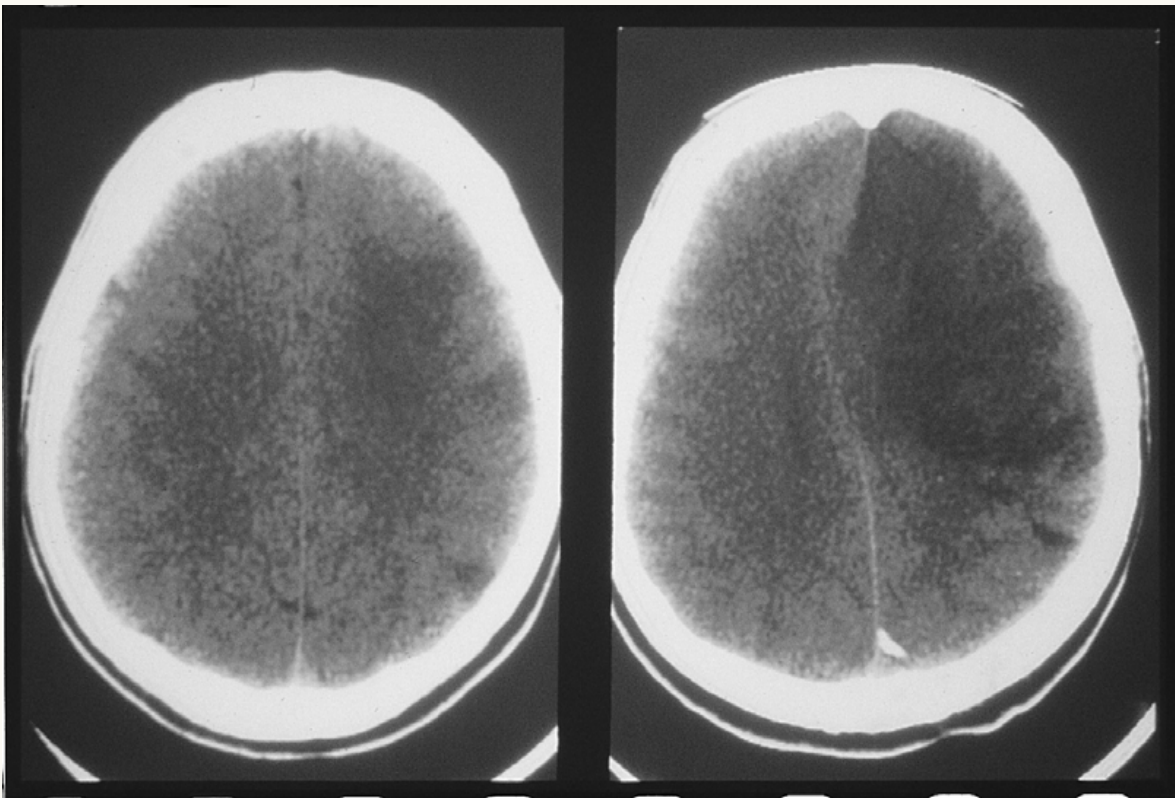




Ischemic Stroke



Left panel shows a small, hypodense area in the left frontoparietal region with loss of the gray-white interface. Right panel shows a large, wedge-shaped hypodensity in the left middle cerebral artery distribution with mass effect.