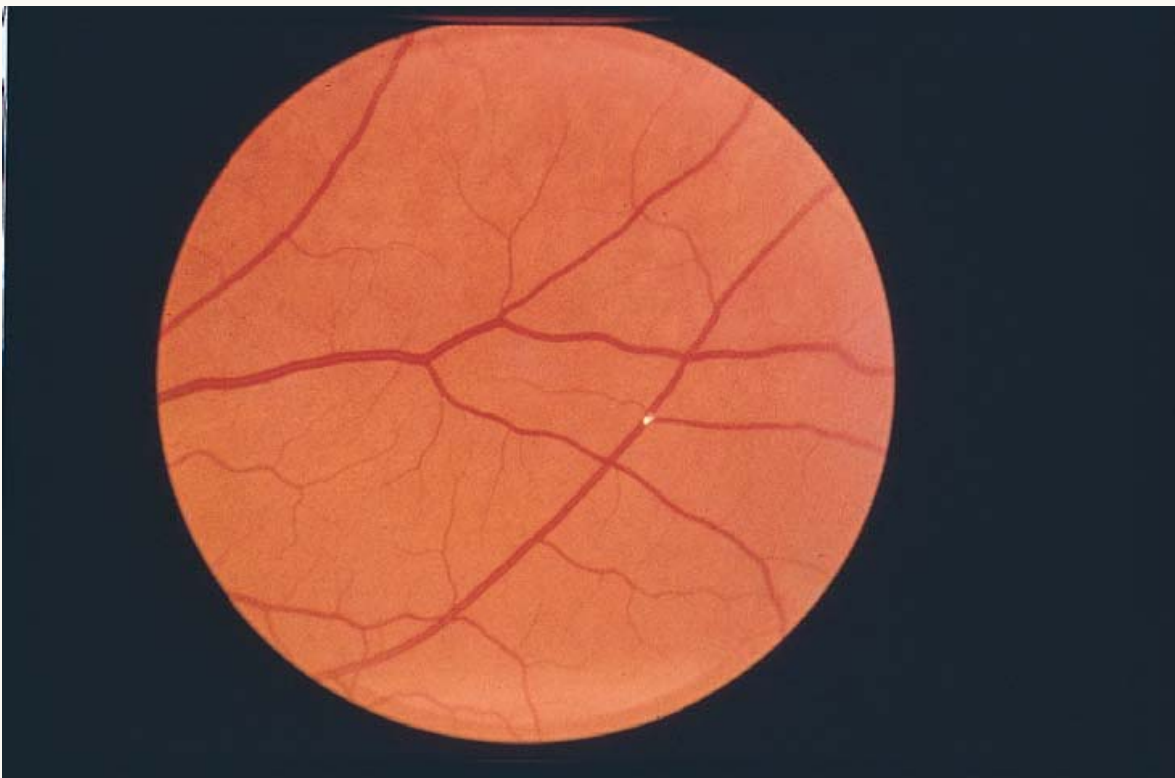




Hollenhorst Plaque



A Hollenhorst plaque is a highly refractile, yellow or golden body within a retinal arteriole representing a cholesterol emboli. This finding implicates an embolic etiology of TIA or stroke, often arising from the carotid artery.