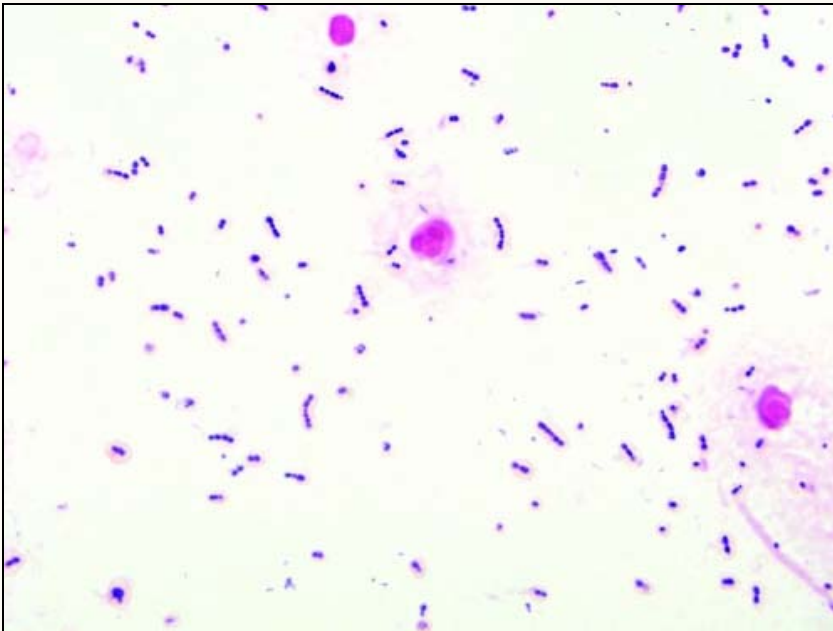




Cerebral Spinal Fluid



Gram-stain of cerebral spinal fluid showing Gram-positive diplococci characteristic of *S. pneumoniae meningitis*.