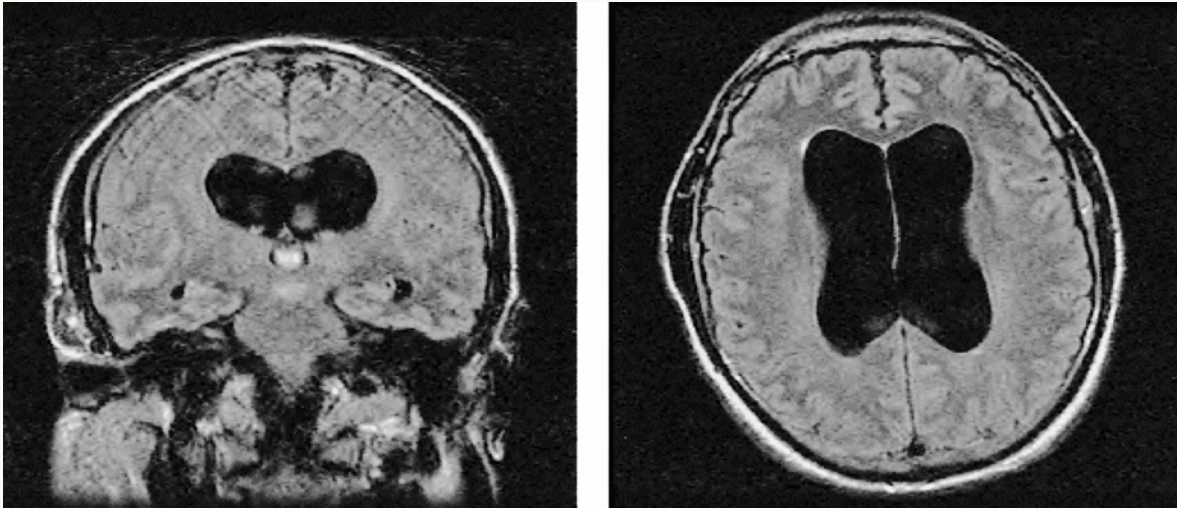




Normal Pressure Hydrocephalus MRI Scan



The MRI scan shows ventricular dilatation typical of normal pressure hydrocephalus. Some patients with this condition respond very well to cerebral fluid shunting.