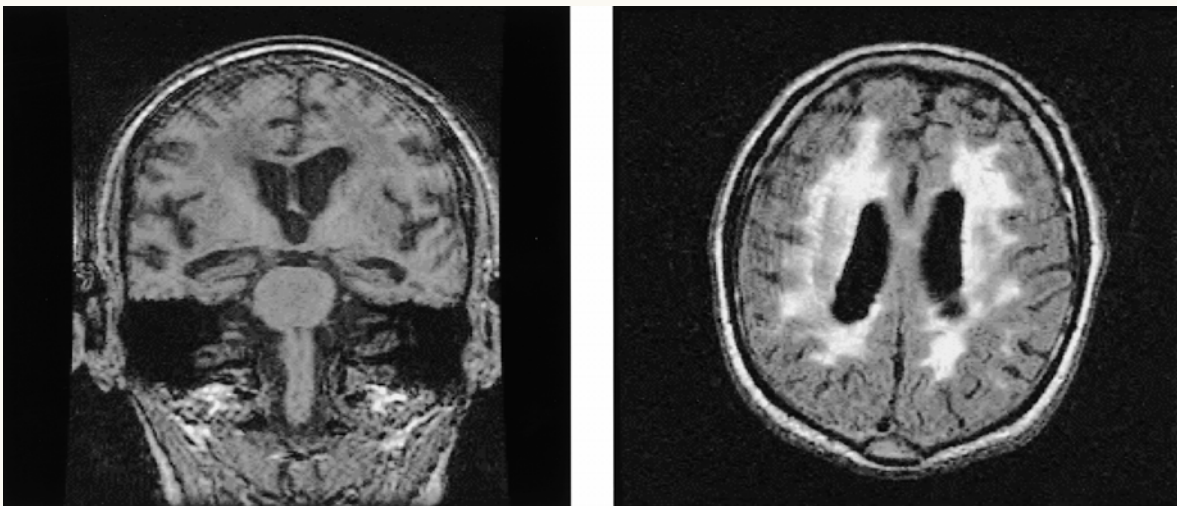




## Vascular Dementia MRI Scan



The MRI scan shows confluent periventricular white matter changes reflected as decreased signal intensity on the coronal image (left) and increased intensity on the axial image (right), typical of vascular dementia.