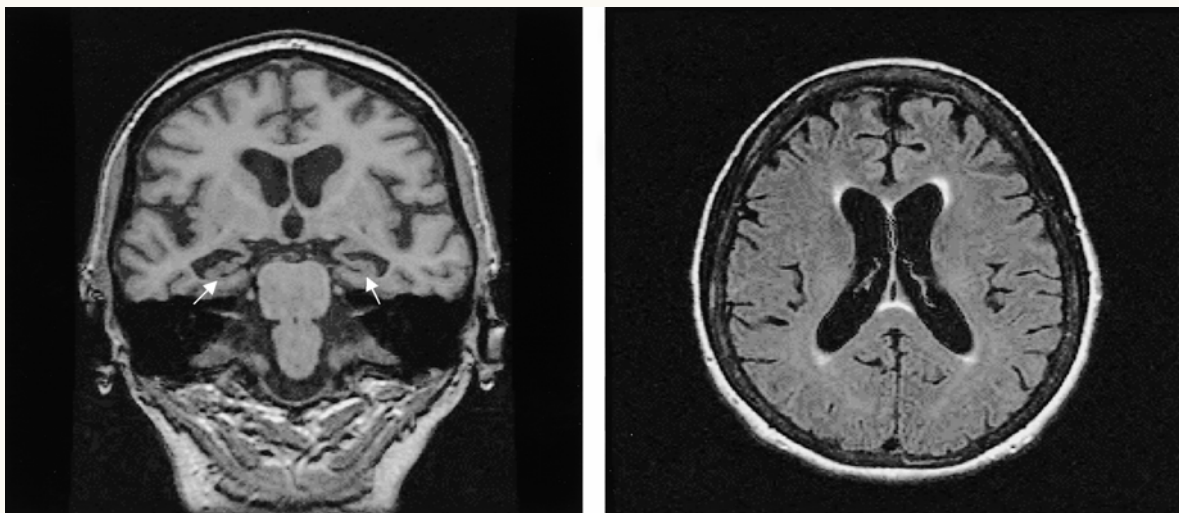




## Alzheimer's Disease MRI Scan



This MRI scan shows bilateral hippocampal atrophy (arrows), which is a typical feature of Alzheimer's disease as well as mild cortical atrophy.