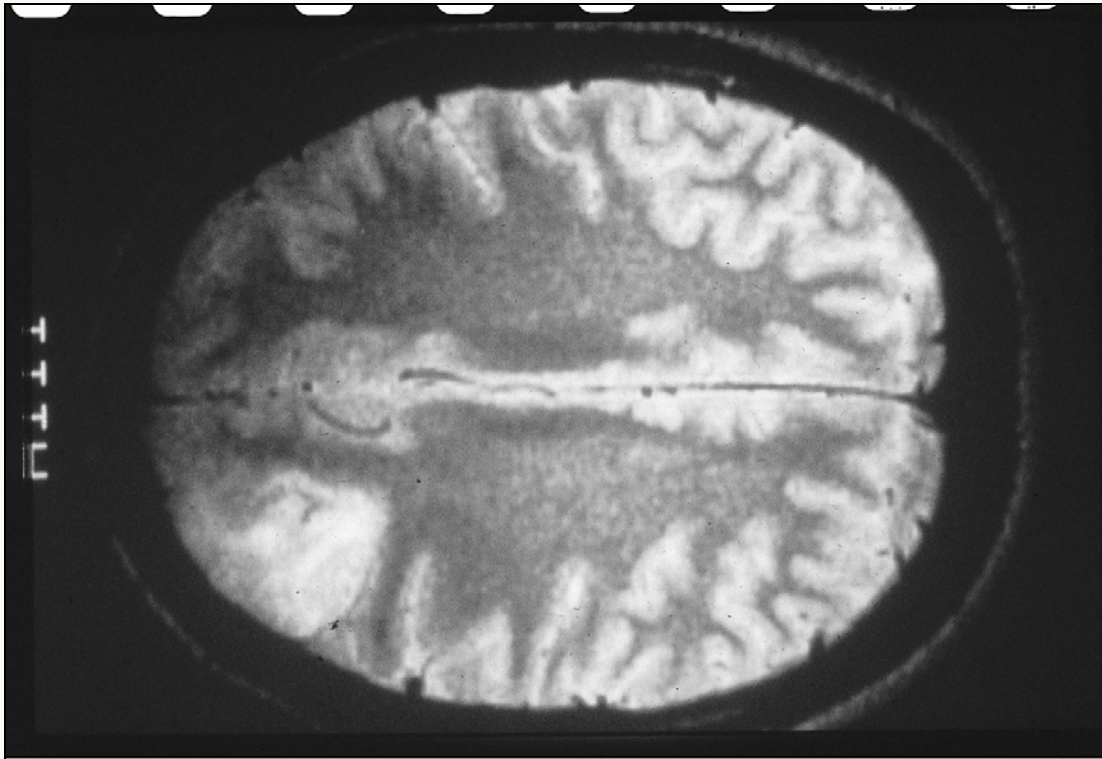




Brain Tumor



MRI Showing Primary Brain Tumor: A right frontal high-signal abnormality on an MRI scan characteristic of a primary brain tumor.