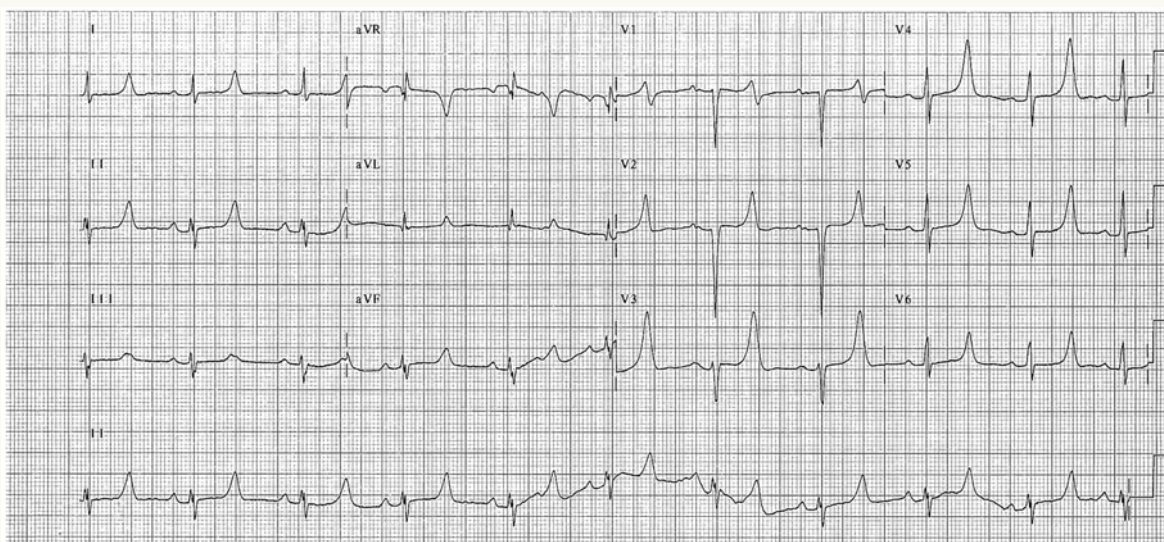




Hyperkalemia



Electrocardiogram showing tall, peaked, narrow-based T waves characteristic of hyperkalemia.