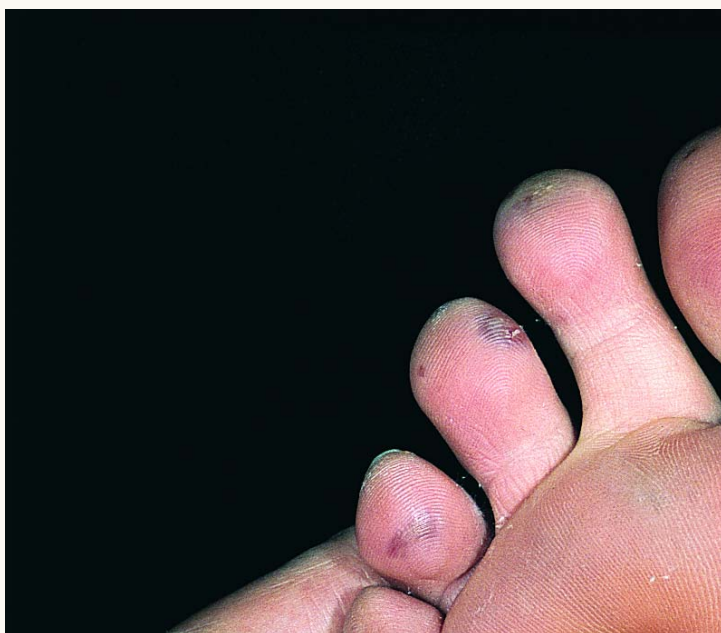




## Blue Toe Syndrome



Small artery occlusions and cutaneous infarctions ("blue toe") secondary to arterio-arterial embolism of small pieces of atheromatous material from an atherosclerotic plaque of the aorta following a cardiac catheterization.