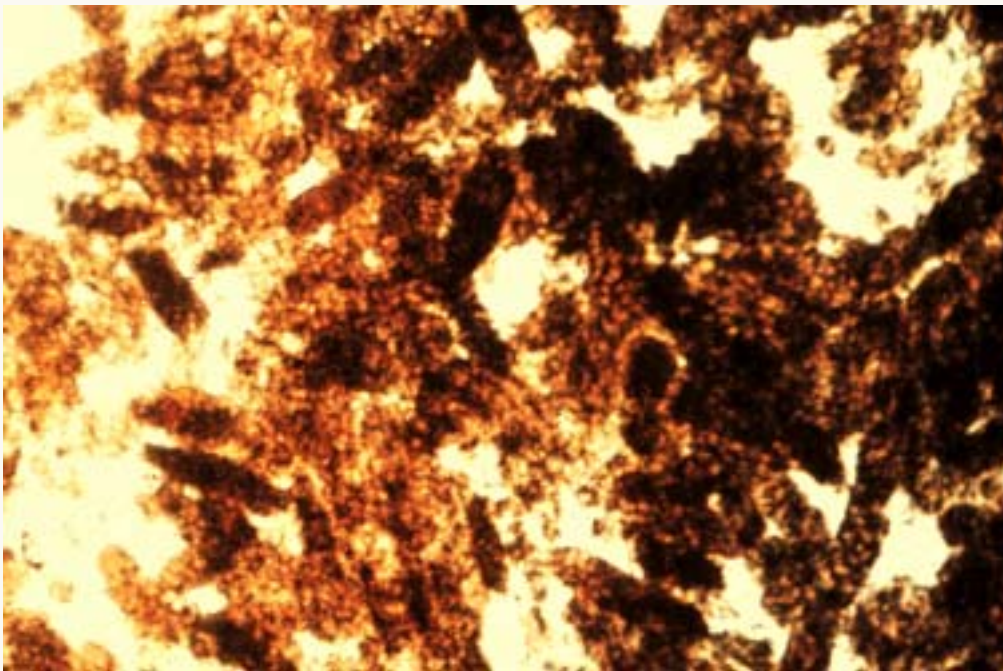




Muddy brown cast



Usually associated with acute renal tubular injury, muddy brown casts are large granular casts that may be pigmented if they contain bilirubin, myoglobin or free hemoglobin.