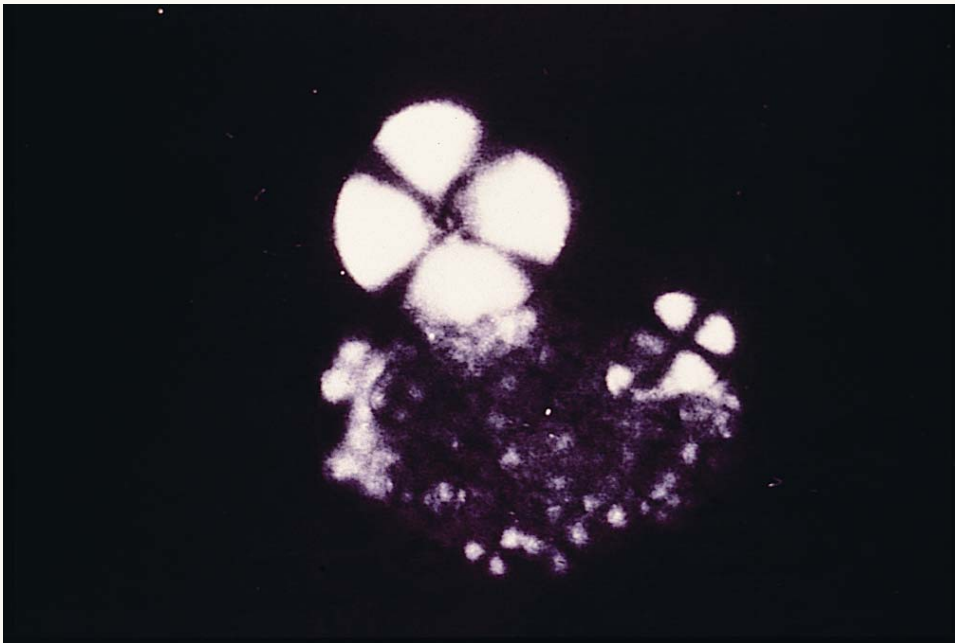




## Fat Droplet



Typical "Maltese cross" appearance of a fat droplet under polarized microscopy usually associated with the nephrotic syndrome or diabetic nephropathy.