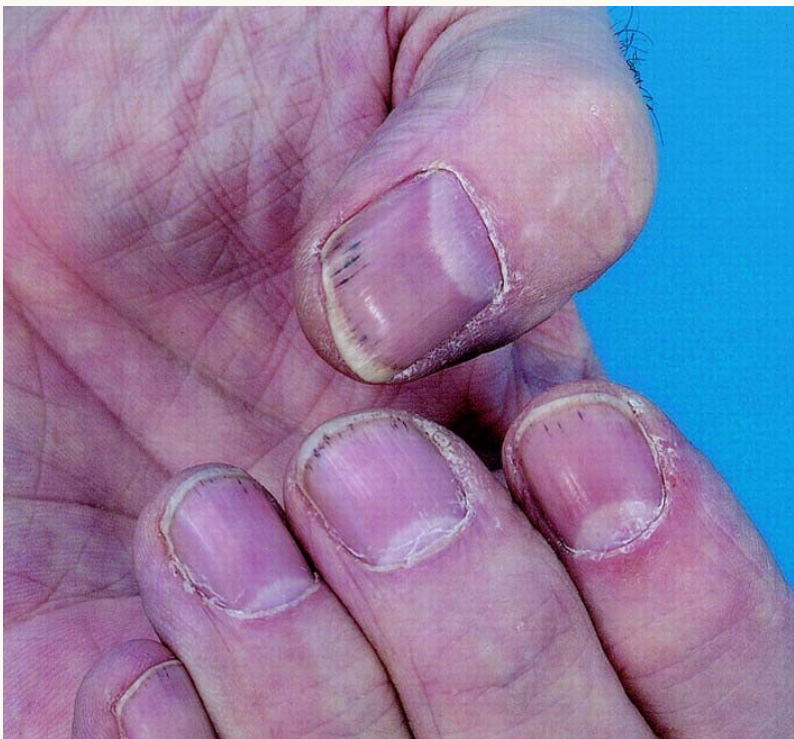




Splinter Hemorrhages



Multiple digit splinter hemorrhages consisting of nonblanching, linear reddish-brown lesions found under the nail bed. Splinter hemorrhages are nonspecific for endocarditis and can occur in other conditions, including cancer.

Used with permission from Robert C, et al. Subungual Splinter Hemorrhages: *Ann Intern Med.* 2005; 143:313-314.

