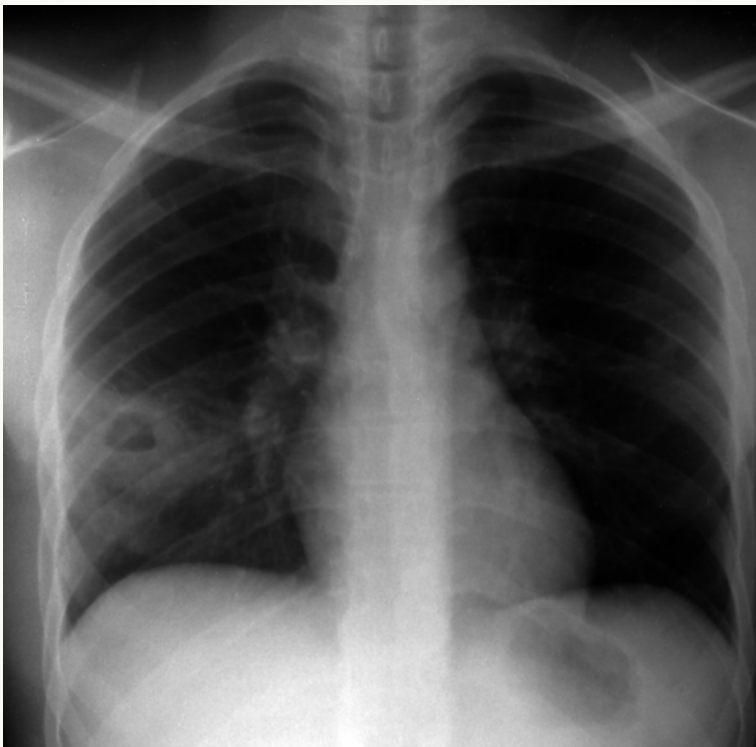




## Right Middle Lobe Pneumonia



Frontal chest radiograph demonstrating an alveolar infiltrate in the right lower lung field. An air-fluid level is seen, consistent with a lung abscess. A lateral chest radiograph would be necessary to determine whether the infiltrate involves the right lower lobe, or alternatively the right middle lobe.