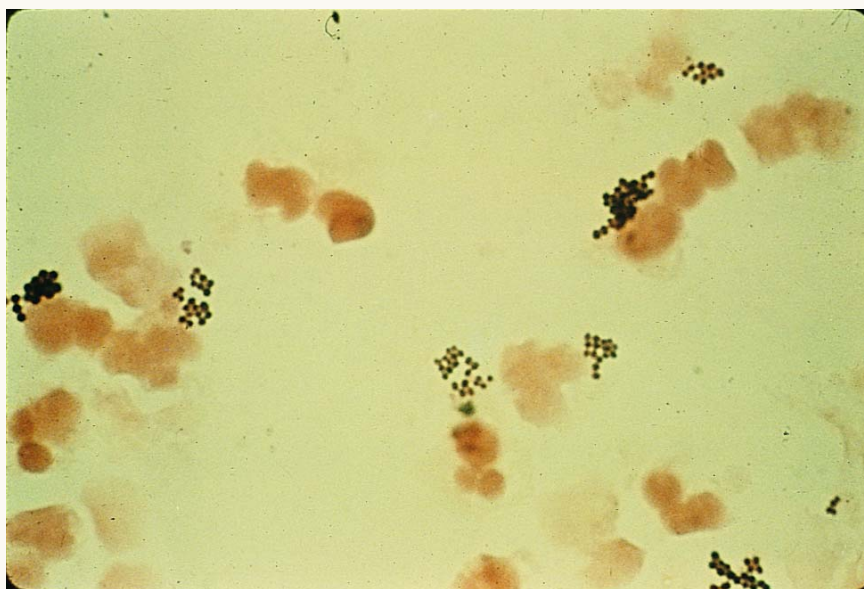




Staphylococcus



Multiple, large gram-positive cocci in clusters characteristic of staphylococcal pneumonia.