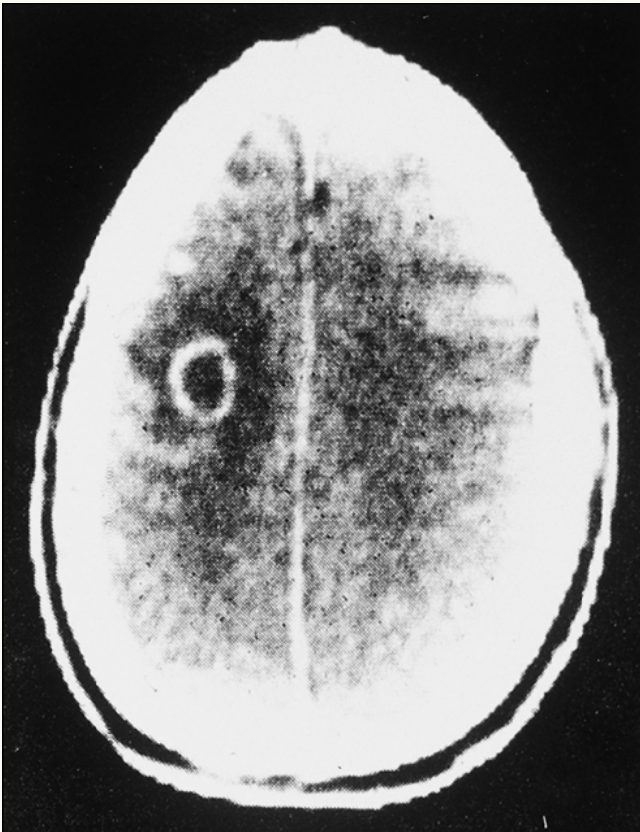




Central Nervous System Toxoplasmosis



A single, ring-enhancing cerebral lesion on CT scan in an HIV positive patient with a positive toxoplasmosis titer is almost certainly central nervous system toxoplasmosis.