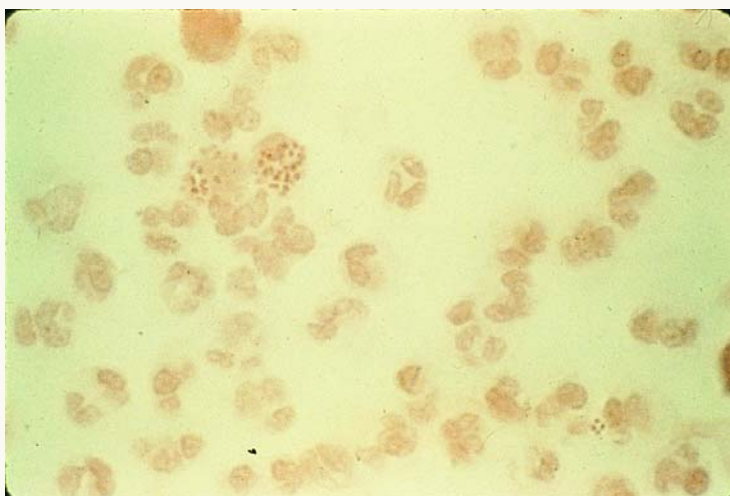




## Gonorrhea Gram Stain



Gram stain of purulent exudate from the cervical os of a patient with pelvic pain showing typical Gram negative diplococci characteristic of gonorrhea.