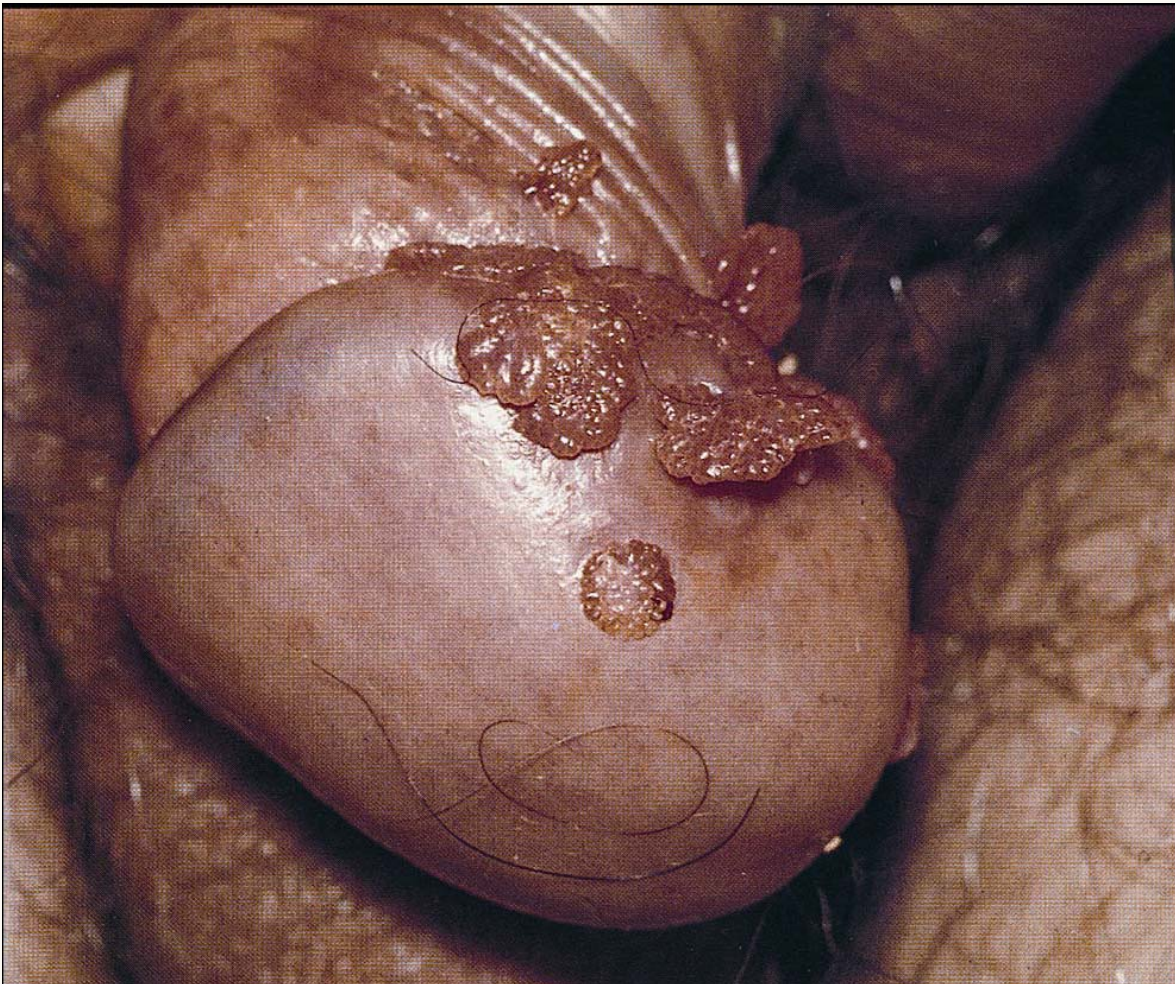




Condyloma acuminata



Note the glistening pink and white papules and plaques with a warty or irregular surface characteristic of condyloma acuminata, or common venereal wart, caused by the human papillomavirus.