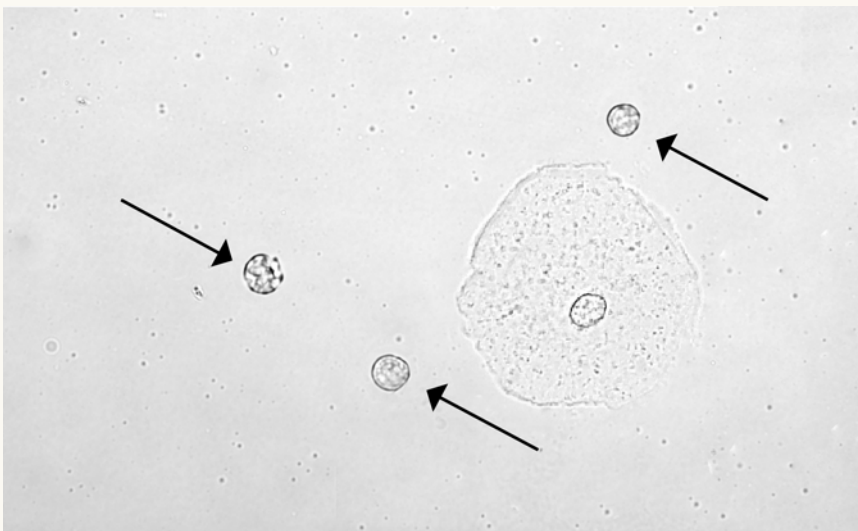




Urinalysis



Small, round cells with nuclei and granular cytoplasm characteristic of leukocytes.