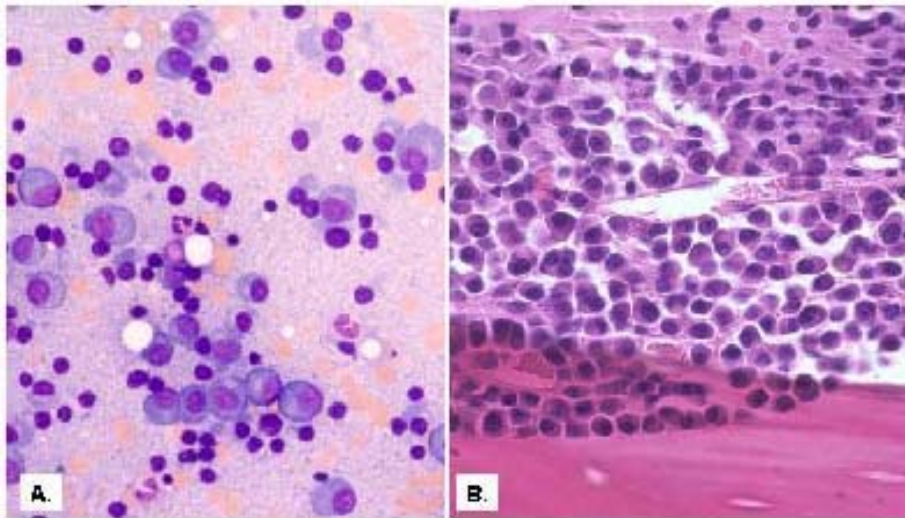




Multiple Myeloma



Bone marrow aspirate and biopsy showing sheets of plasma cells characteristic of multiple myeloma.