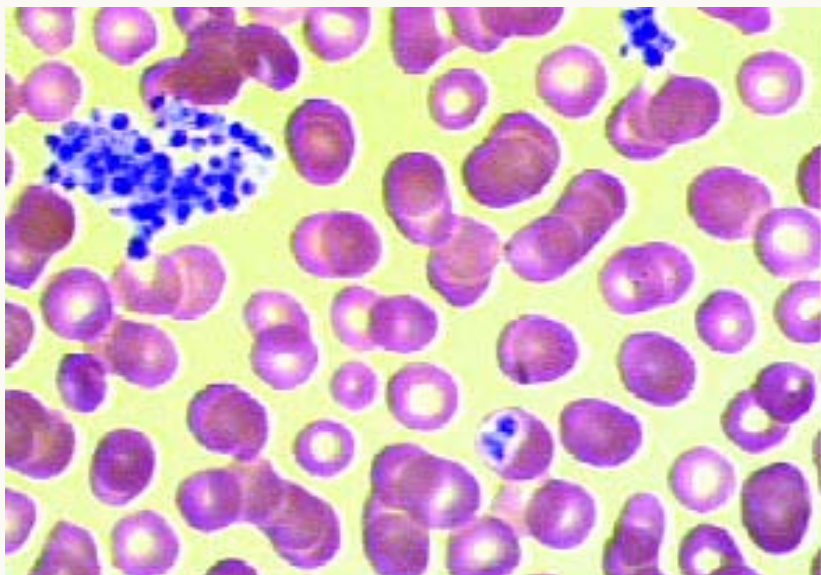




## Pseudothrombocytopenia



Peripheral blood smear showing large clumps of dark blue platelets adhering to neutrophils (upper left corner) characteristic of pseudothrombocytopenia.