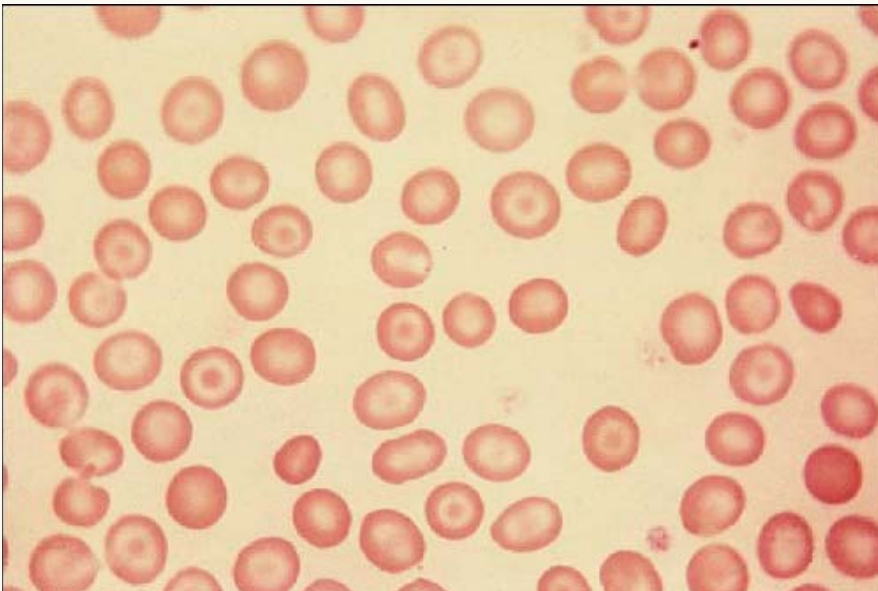




Target Cells



The peripheral smear shows target cells. Small target cells are associated with thalassemia. Other morphologic abnormalities of thalassemia (e.g., basophilic stippling, not seen here) may or may not also be present. Target cells may also be associated with liver disease.