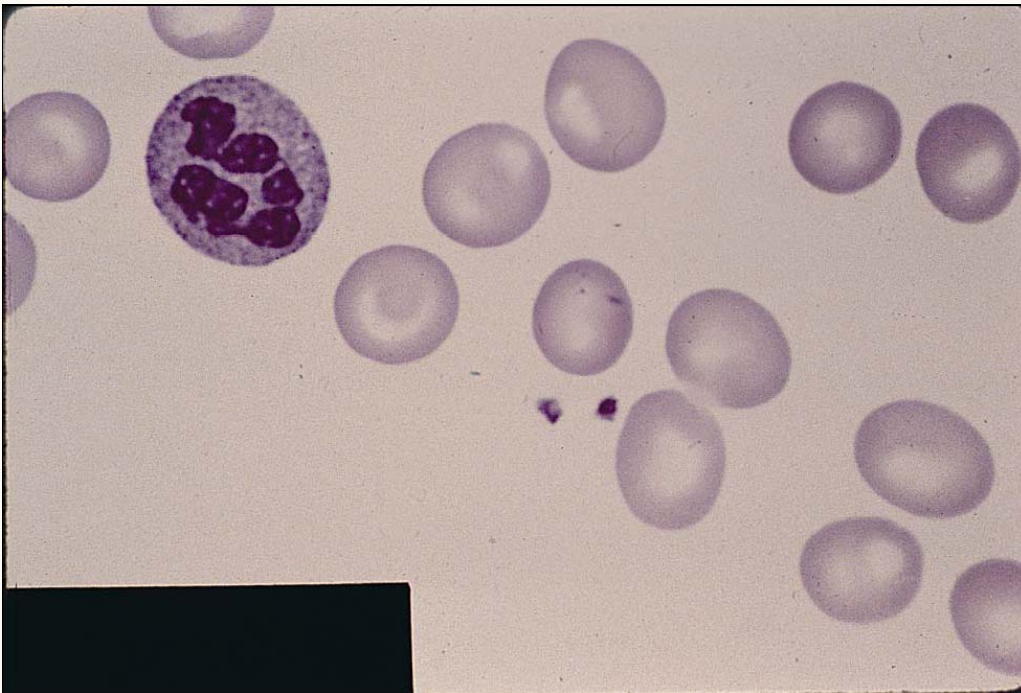




Megaloblastic Anemia



Peripheral blood smear showing anisocytosis, poikilocytosis, macro-ovalocytes and a hypersegmented polymorphonuclear erythrocyte characteristic of megaloblastic anemia. Common conditions associated with megaloblastic anemia include vitamin B₁₂ and folate deficiency.