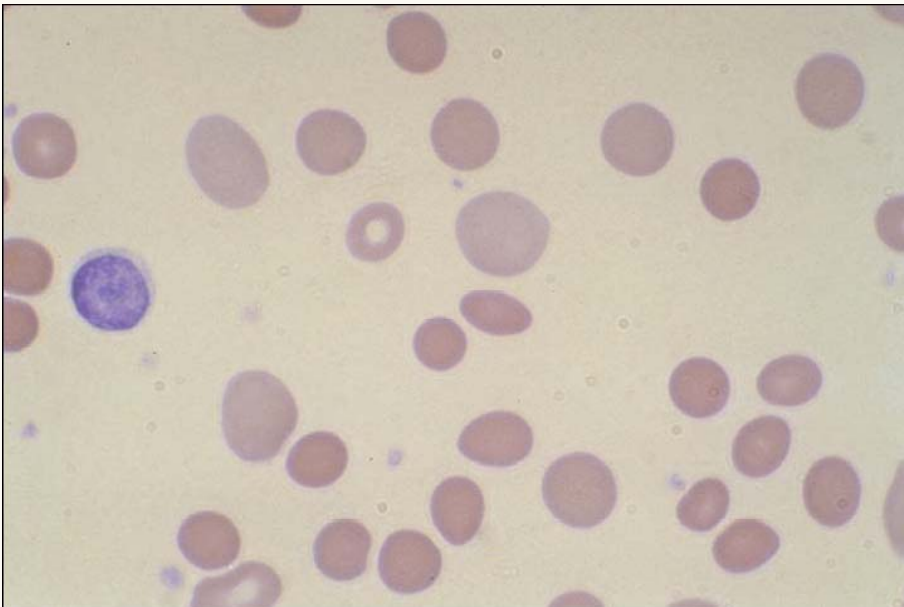




Spherocytosis



Peripheral blood smear showing small erythrocytes with loss of central pallor characteristic of spherocytosis. This finding is compatible with hereditary spherocytosis, the most common inherited hemolytic anemia.