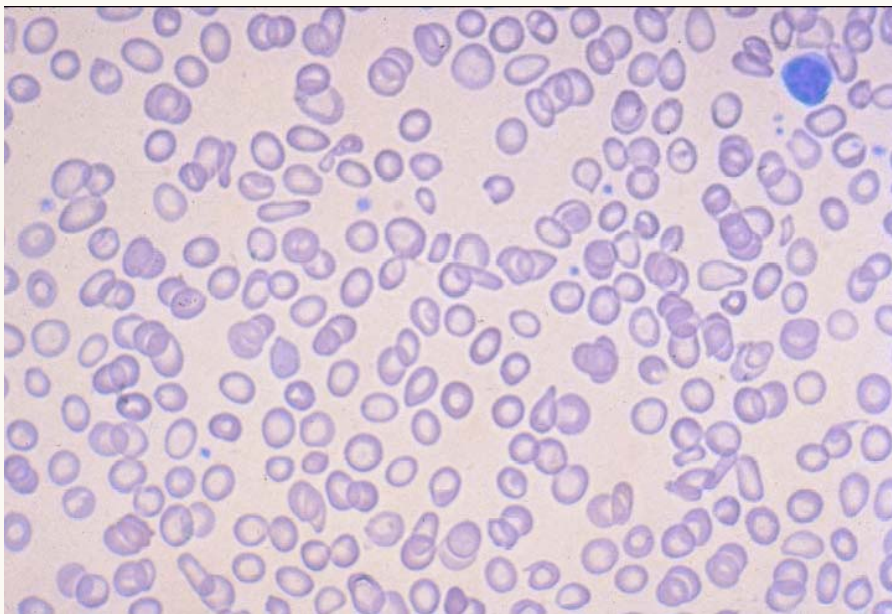




Iron Deficiency Anemia



A peripheral blood smearing showing hypochromic erythrocytes with variation in size and shape; there are numerous "pencil cells" and virtual absence of target cells. These findings are consistent with severe iron deficiency anemia.